

RESEARCH ARTICLE

The Effect of Synovial Fluid as a Natural Source of Hyaluronic Acid on Limberg Flap and Elliptical Rotation Flap Healing: A Comparative Study of Full-Thickness Excisional Dermal Wounds in Mice

Hasan ÇANTAY^{1,a (*)} Uğur AYDIN^{2,b} Turgut ANUK^{1,c}
Emin KARAKURT^{3,d} Uğur YILDIZ^{2,e} Hilmi NUHOĞLU^{3,f}

¹ Kafkas University, Faculty of Medicine, Department of General Surgery, TR-36100 Kars - TURKEY

² Kafkas University, Faculty of Veterinary Medicine, Department of Surgery, TR-36100 Kars - TURKEY

³ Kafkas University, Faculty of Veterinary Medicine, Department of Pathology, TR-36100 Kars - TURKEY

ORCIDs: ^a 0000-0003-3309-8879; ^b ORCID: 0000-0001-5756-4841; ^c ORCID: 0000-0002-8903-9993; ^d ORCID: 0000-0003-2019-3690

^e ORCID: 0000-0002-4782-1012; ^f ORCID: 0000-0003-2530-2542

Article ID: KVFD-2021-25525 Received: 06.02.2021 Accepted: 20.05.2021 Published Online: 24.05.2021

Abstract

The purpose of this study was to investigate the efficacy of synovial fluid (SF) as a source of hyaluronic acid (HA) on Limberg and Elliptical rotation flap healing. In this study conducted on 24 male *Mus musculus* mice, the animals were divided into 2 main groups. Group 1 (n = 12): Limbergflap group; Group 2 (n = 12) Elliptical rotation flap group. Six of the animals in Group 1 and Group 2 were assigned as the Flap (Control) Group, and 6 as the Flap + SF Group. In SF subgroups of animals in each group, 1 mL SF was injected into the operation area in addition to the flap surgical procedure. The groups were compared in terms of epithelialization, angiogenesis, neutrophil leukocyte infiltration and fibroblast activity, and the effect of SF on the inflammation and wound healing was evaluated. It was observed that epithelialization was completed in all animals in the groups which were administered compared to the other groups, and there was a statistically significant difference (P<0.05). In addition, no necrosis or abscess was found in the groups which were administered SF. There was no statistical difference in the paired comparisons of neutrophil-leukocyte infiltration and fibroblast activity parameters. Although the Limberg flap technique is more commonly used today, it can be said that elliptical rotation flap is a method that can be used in routine practice due to a lower complication rate. However, SF increases epithelialization and plays a regulatory role on angiogenesis. Therefore, it is concluded that the use of SF as a source of HA in combination with elliptical rotation flap in wounds with material tissue loss will contribute to clinical practice.

Keywords: Elliptical rotation flap, Hyaluronic acid, Limberg flap, Synovial fluid, Experimental study, Wound healing

Doğal Bir Hyaluronik Asit Kaynağı Olarak Sinovyal Sıvının Limberg Flep ve Eliptik Rotasyon Flep İyileşmesi Üzerine Etkisi: Farelerde Tam Katmanlı Eksizyonel Dermal Yaralarda Karşılaştırmalı Bir Çalışma

Öz

Bu çalışmada, doğal bir hyaluronik asit (HA) kaynağı olarak sinovyal sıvının (SS) Limberg ve Eliptik rotasyon flep iyileşmesi üzerine etkinliğinin araştırılması amaçlandı. Yirmi dört adet erkek *Mus musculus* cinsi fare üzerinde yapılan bu çalışmada hayvanlar 2 ana gruba ayrıldı. Grup 1 (n=12): Limberg flep grubu; Grup 2 (n=12) Eliptik rotasyon flep grubu. Grup 1 ve Grup 2'deki hayvanların 6'sı Flep (Kontrol) Grubu, 6'sı ise Flep + SS Grubu olarak ayrıldı. Her bir gruptaki hayvanların SS alt gruplarında flep cerrahi prosedürüne ek olarak operasyon bölgesine 1 mL SS enjekte edildi. Epitelizasyon, anjiyogenezis, nötrofil lökosit infiltrasyonu ve fibroblast aktivitesi yönünden gruplar karşılaştırılarak SS'nin flep viabilitesi ve yara iyileşmesine olan etkisi değerlendirildi. SS uygulanan gruplarda hayvanların tamamında, diğer gruplara göre epitelizasyonun tamamlandığı ve istatistiksel olarak anlamlı farklılık olduğu görüldü (P<0.05). Ayrıca, SS verilen gruplarda nekroz ve apseye rastlanmadı. Nötrofil-lökosit infiltrasyonu ve fibroblast aktivitesi parametrelerindeki ikili karşılaştırmalarda ise istatistiksel fark saptanmadı. Limberg flep tekniği günümüzde daha çok uygulanıyor olsa da eliptik rotasyon flebinde komplikasyonun daha az olması nedeniyle rutinde uygulanabilecek bir yöntem olduğu söylenebilir. Bununla birlikte SS, epitelizasyonu arttırmakta ve angiogenezis üzerinde düzenleyici rol üstlenmektedir. Bu sebeplerle, bir HA kaynağı olarak SS'nin, maddi doku kayıplı yaralarda eliptik rotasyon flebi ile birlikte kullanımının klinik pratiğe katkı sağlayacağı belirlenmiştir.

Anahtar sözcükler: Eliptik rotasyon flebi, Hyaluronik asit, Limberg flep, Sinovyal sıvı, Deneysel çalışma, Yara iyileşmesi

How to cite this article?

Çantay H, Aydın U, Anuk T, Karakurt E, Yıldız U, Nuhoglu H: The effect of synovial fluid as a natural source of hyaluronic acid on limberg flap and elliptical rotation flap healing: A comparative study of full-thickness excisional dermal wounds in mice. *Kafkas Univ Vet Fak Derg*, 27 (3): 355-361, 2021. DOI: 10.9775/kvfd.2021.25525

(*) Corresponding Author

Tel: +90 533 623 5576

E-mail: hasan_cantay@hotmail.com (H. Çantay)



This article is licensed under a Creative Commons Attribution-NonCommercial 4.0 International License (CC BY-NC 4.0)

INTRODUCTION

Wound is defined as the disruption of the anatomical and functional continuity of living tissue. Wound healing occurs as a result of a series of events consisting of hemostasis and inflammation, proliferation (proliferation of cells) and restructuring and maturation phases in order to restore the integrity and functional capacity of the tissue. Prolonged duration or interruption of any of these phases causes delay in wound healing or the wound to become chronic [1,2]. In addition to biochemical markers such as nitric oxide (NO), histamine and polypeptide growth factors, nutrition, diabetes, chemotherapy, radiotherapy, genetic and immunological disorders and infection are among the factors affecting wound healing [3].

In traumatic situations with severe tissue loss, flap surgery is a method frequently used to repair defects. For this purpose, many local flap techniques such as elliptical rotation, Limberg, V-Y advancement flaps and Z-plasty are used. Despite advances in surgical techniques, ischemia and necrosis of flaps remain a critical problem. Furthermore, excessive fibrosis and generalized adhesions are also an important problem in tissue healing [4,5].

Hyaluronic acid (HA), a glycosaminoglycan first discovered by Meyer and Palmer in 1934, is known to be involved in the regulation of TGF β -1 (carrier growth factor) and wound healing by providing fibroblast and myofibroblastic proliferation [4-6]. It is commonly used as a viscoelastic material, especially in eye, nerve and muscle surgery, to contribute to the primary healing of injured tissues by preventing adhesion [7-10].

The purpose of this study was to compare the effects of Limberg and Elliptical rotation flap techniques on tissue viability and to investigate the efficacy of SF as a source of HA in preventing excessive fibrosis, which is an important problem in tissue healing.

MATERIAL AND METHODS

Ethical Approval

The study was conducted with the approval of the Ethics Committee of Kafkas University Animal Experiments Local Ethics Committee with the research code (Approval no: KAU-HADYEK/2020-157).

Animals

A total of 24 male *Mus musculus* mice, 8-12 weeks old and weighing 40-45 g, were included in the study. Mice were housed in separate cages under standard laboratory conditions (12 h dark/12 h daylight, 45%-55% humidity, and room temperature 20-22°C). Animals were fed *ad libitum* with a standard feed and water.

Study Groups

Animals were divided into two main groups (n=12).

Group 1: Limberg Flap Group

Group 1-A (n = 6): Limberg Flap (Control) Group

Group 1-B (n = 6): Limberg Flap + Synovial Fluid Group

Group 2: Elliptical Rotation Flap Group

Group 2-A (n = 6): Elliptical Rotation Flap (Control) Group

Group 2-B (n = 6): Elliptical Rotation Flap + Synovial Fluid Group

In addition to the flap technique used in SF subgroups in Group 1 and Group 2, 1 mL volume of SF was administered to the wound area (subcutaneous and intradermal). Synovial fluid was collected from both tarsal joints of a healthy bovine after the asepsis of the area, by arthrocentesis and used after centrifugation using a Rotina 380 R device for 10 min at 3500 rpm. The cow whose synovial fluid was taken was a healthy animal raised at the university, and the synovial fluid taken was used without waiting.

Anesthesia

The study was conducted under general anesthesia induced by intraperitoneal injection of 10 mg/kg xylazine HCl (Rompun, 2%, Bayer®) and 100 mg/kg ketamine HCl (Ketas, 50 mg/mL, Pfizer®) mixture.

Surgery

After shaving and disinfection of the dorsal area (povidone iodine + 70% ethanol, ISOLABÒ) in each of the animals included in the experiment, a skin excision with a diameter of 2.5x3.0 cm containing all layers which can not be closed without flap was made, and tissue loss wound was created (Fig. 1-a, Fig. 2-a).

The excisional wound created in Group 1-A was closed using the Limberg flap technique (Fig. 1) and in Group 2-A using the Elliptical Rotation Flap technique (Fig. 2); no other procedure was performed. These subgroups were evaluated as the control group of each flap technique. In the animals in Group 1-B and Group 2-B, SF (1 mL) was administered subcutaneously and intradermally to the wound area, following the closure of the wound with suture in accordance with the flap technique in their groups (Fig. 3-a,b).

Wound closure in all groups 4/0 polyglactin 910 (VicrylÒ, ETHICONÒ) was performed with a simple separate suture technique using absorbable suture material.

Postoperative Care

All mice were housed individually in standard cages under

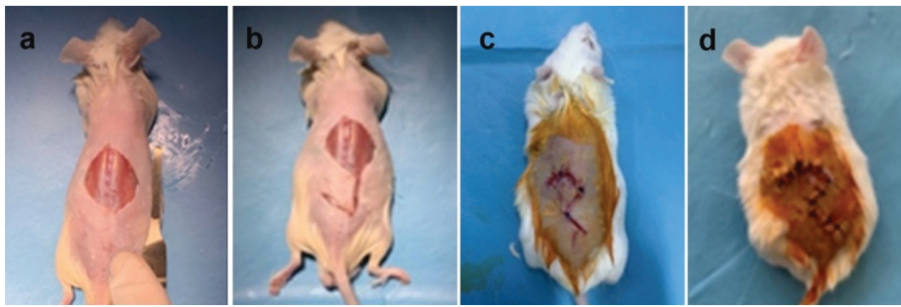


Fig 1. View of Limberg Flap Technique (Group 1-A) application; a) Full-thickness excisional wound, b) Limberg flap incision, c-d) Closure of the incision

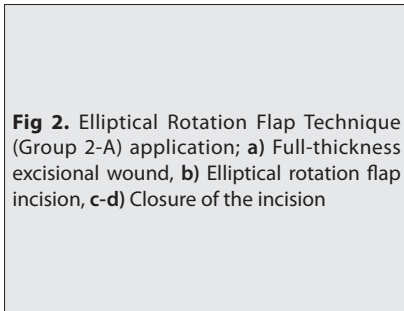


Fig 2. Elliptical Rotation Flap Technique (Group 2-A) application; a) Full-thickness excisional wound, b) Elliptical rotation flap incision, c-d) Closure of the incision

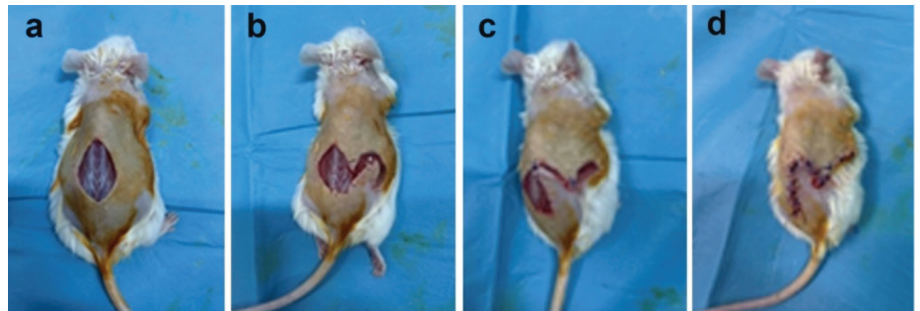


Fig 3. Synovial fluid injection to the wound area. a) Limberg Flap Technique (Group 1-B), b) Elliptical Rotation Flap Technique (Group 2-B)

standard laboratory conditions, and feed and water were provided to the mice regularly for 7 days.

Macroscopic Examination

On the 7th day of the study, a high dose of pentobarbital sodium was administered by IP route followed by euthanasia. Following euthanasia, the wound site was evaluated and photographed macroscopically. The skin and subcutaneous tissues were excised in full layers, including the entire flap, and submitted to the pathology laboratory for evaluation in 10% formaldehyde solution.

Histopathological Examination

After performing routine tissue follow-up procedures, 4-5 micron thick sections were collected from the prepared paraffin blocks on the microtome device, and Hematoxylin & Eosin (H&E) and Masson's Trichrome staining (Facepath Commercial Kit) were performed to evaluate histopathological changes. Sections were examined under

a light microscope (Olympus Bx53) and photographed by the Cell ^P Program (OlympusSoftImaging Solutions GmbH, 3,4).

The sections with H&E and Masson's Trichrome staining were examined and evaluated for epithelization, angiogenesis, neutrophil leukocyte infiltration and fibroblast activity. In the examinations, the suture line in the flap shifted for epithelization was examined; the cases in which epithelization started in the epidermis layer but there was little progress were scored as 1 (+), the cases in which epithelization started but did not close the epidermis scar line were scored as 2 (++), and the cases in which epithelization was completed were scored as 3 (+++). For neutrophil leukocyte infiltration and fibroblast activation, all flap areas in the sections were evaluated and scored as mild (1), moderate (2) and severe (3) based on their severity. For angiogenesis, neocapillary vessels in the regions where angiogenesis was most intense (HighScore method) were counted at 200x magnification.

Statistical Analysis

The normal distribution of the intragroup data was determined by the Shapiro-Wilk test. Mann-Whitney U test was used for comparison of the groups. $P < 0.05$ was considered statistically significant.

RESULTS

Clinical Observations

During the study, all the animals continued their normal lives, and there were no adverse conditions related to the animals or the wound area. It was macroscopically observed that wound healing occurred in all groups on the postoperative day 7 (Fig. 4).

Macroscopic Results

In all groups, when the skin and subcutaneous tissues were excised in full layers, including the entire flap, no macroscopic evidence of infection or necrosis was observed.

Histopathological Results

Group 1-A (Limberg Flap Control Group): Two animals had necrosis and abscess. While epithelization was well formed but not completed in most animals, epithelization was completed in one animal. It was seen that angiogenesis was well formed, and the average of neocapillary vessels counted at 200x magnification was 44.33. It was found that the fibroblast activity was severe in half of the group, and moderate in the other half. It was shown that the fibroblast activity was also moderate in the animal with abscess (Fig. 5-a,e).

Group 1-B (Limberg Flap + Synovial Fluid Group): No signs of necrosis or infection were found. It was found that epithelization was completed in all animals. On the other hand, it was observed that angiogenesis was less than that of the Limberg group and the group mean was 31.33. In all animals except one animal, it was noted that fibroblast activity was severe, but in one animal the fibroblast activity was moderate (Fig. 5-b,f).

Group 2-A (Elliptical Rotation Flap Control Group): One animal had bleeding, necrosis and infection. It was observed that epithelization was good, including the animal with necrosis and infection, but epithelization was not completed except only in one animal. The group average of neocapillary vessel formation was 35.66. Fibroblast activity was moderate, but mild in an animal with necrosis (Fig. 5-c,h).

Group 2-B (Elliptical Rotation Flap + Synovial Fluid Group): No signs of necrosis or infection were found. It was found that epithelization was completed in all animals. The group average of neocapillary vessel formation was 36.00. In all animals except one, it was observed that the fibroblast activity was severe, and this parameter was moderate in one animal (Fig. 5-d,g).

There was no difference in neutrophil leukocyte infiltrates between the groups.

In the statistical comparison, there was a significant difference in epithelization formation between Group 1-A and Group 1-B and Group 2-A and Group 2-B ($P < 0.05$). There was also a statistical difference in terms of angiogenesis in the comparison of Group 1-A and Group 2-A ($P < 0.05$). On the other hand, there was no significant difference in angiogenesis between Group 2-A and Group 2-B, and there was no statistical difference in paired comparisons of neutrophil-leukocyte infiltration and fibroblast activity parameters ($P > 0.05$). In addition, there was no statistical difference in all parameters between Group 1-A and Group 2-A and Group 1-B and Group 2-B ($P > 0.05$) (Table 1).

DISCUSSION

As a natural source of HA, SF contains enzymes such as matrix metalloproteinase-1 (MMP-1), elastase and plasmin, as well as hyaluronan and DN-acetyl glucosamine, which are involved in tissue remodeling in varying concentrations [11]. As is known, HA and viscoelastic materials are antiadhesive agents due to their viscoelastic properties rather than their anti-inflammatory effects [7,8]. In our study, we aimed to

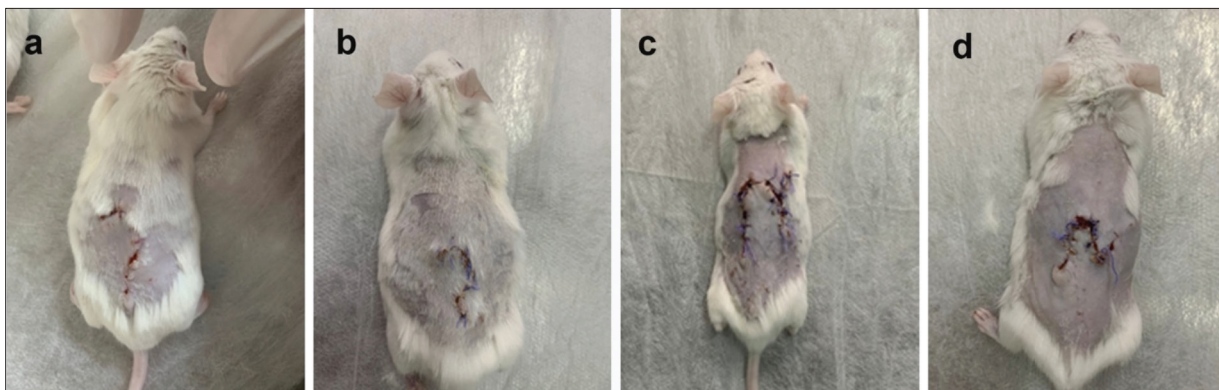


Fig 4. Postoperative 7th day view of all groups; a) Group 1-A, b) Group 1-B, c) Group 2-A, d) Group 2-B

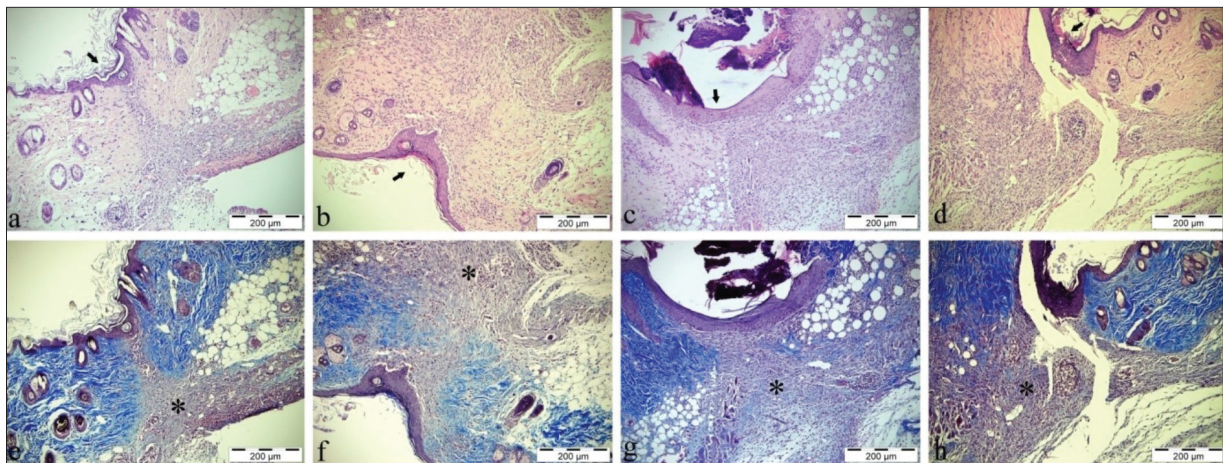


Fig 5. Microscopic images. **a)** Limberg group, H&E, Bar = 200 µm, **b)** Limberg + SF group, H&E, Bar = 200 µm, **c)** Elliptical Group, H&E, Bar = 200 µm, **d)** Elliptical + SF group, H&E, Bar = 200 µm, **e)** Limberg group, MassonTrichrom, Bar = 200 µm, **f)** Limberg + SF group, MassonTrichrom, Bar = 200 µm, **g)** Elliptical + SF group, MassonTrichrom, Bar = 200 µm, **h)** Elliptical group, MassonTrichrom, Bar = 200 µm (Arrows: areas of epithelization, stars: fibroblast activity)

Table 1. Statistical comparison of the groups in terms of epithelization, angiogenesis, neutrophil-leukocyte infiltration and fibroblast activity

Groups	Epithelization* (X±SE)	Angiogenesis (X±SE)	Neutrophil Leukocyte Infiltration (X±SE)	Fibroblast Activity (X±SE)
Group 1-A (Limberg Flap)	2.17±0.167 ^a	44.33±2.963 ^a	2.17±0.307 ^a	2.50±0.224 ^a
Group 1-B (Limberg Flap + SF)	3.00 ^b	31.33±2.789 ^b	2.17±0.307 ^a	2.83±0.167 ^a
Group 2-A (Elliptical Rotation Flap)	2.17±0.167 ¹	35.67±6.119 ¹	2.50±0.224 ¹	2.17±0.307 ¹
Group 2-B (Elliptical Rotation Flap + SF)	3.00 ²	36.00±4.163 ¹	2.33±0.211 ¹	2.83±0.167 ¹

* Due to the lack of variation in the data in the Limberg and Elliptical Rotation Flap + SF groups, only value was given; a,b and 1,2; There is a statistical difference between the groups with different letters and numbers in the same column ($P<0.05$). SF: Synovial fluid

investigate the effect of SF on tissue viability, which is one of the most common problems in flap surgery and affects healing, and its effectiveness in preventing excessive fibrosis.

Flap techniques are frequently used in surgery, especially in sacrococcygeal pilonidal sinus disease. Various flap techniques have been described in the treatment of pilonidal sinus disease. These include Z-plasty, W-plasty, VY advancement flap, Limberg Flap, gluteus maximus myocutaneous flap, and fasciocutaneous rotation flap [12]. Limberg flap technique is a method preferred more than other flap techniques due to its satisfactory results [13-15]. The most common complications in flap methods are tissue ischemia, dehiscence, and infection [16]. Furthermore, there are studies showing that maceration, dehiscence and infection are less common in the elliptical rotation flap technique compared to Limberg flap method due to the absence of acute angled end points (corner points) [17-19]. In this study, Limberg and Elliptical rotation flap methods were compared on mice with tissue loss, and it was observed that two mice developed necrosis and abscess in the Limberg group, and one animal developed necrosis

and infection in the elliptical rotation group. Although elliptical rotation flap is used less frequently, it can be said that it has a lower rate of complications and can be applied routinely.

It is known that HA, which is a glycosaminoglycan and has regulatory roles in the immune system, mitosis, migration and inflammation, is generally derived from umbilical cord, cockscomb, skin, joint fluid and spinal cord, bacteria and marine animals [9,20]. It has been proven that HA can be used as a potential material to prevent bacterial contamination in dressings for wounds [21]. It is known that HA acts as an antioxidant by retaining free radicals and has a protective effect by removing tissue-destroying enzymes from the environment in inflammation [22,23]. The viscous structure of HA helps delay the viral and bacterial passage in the pericellular region rich in hyaluronic acid [24-26]. In our study, SF obtained from bovine joints was used as the source of HA. No mice developed necrosis and abscess in mice administered intradermal and subcutaneous SF in Group 1-B and Group 2-B, and a total of three mice developed necrosis and abscess in Group 1-A and Group 2-A without SF injection. These results suggest that SF creates a barrier

in the wound area due to its viscous structure, preventing the infection and thus the development of necrosis and abscess.

The role of HA in the wound healing process is fundamental to the wound healing process in many of the HA-mediated biological processes. Wound healing after injury consists of tightly regulated successive processes. These are inflammation, granulation tissue formation, reepithelization and remodeling. HA has a versatile role in these cellular and matrix related events. It is known that HA makes wound matrix more permeable for fibroblast migration and accelerates wound healing [4,22,23]. When evaluated in terms of epithelization, in our study, it was observed that epithelization was completed in all mice in the groups that received SF compared to the groups that did not receive SF.

Hyaluronic acid has a role in the control of angiogenesis. High molecular weight HA in the extracellular matrix has been shown to inhibit angiogenesis. In contrast, various experimental models have shown that low molecular weight HA oligosaccharides stimulate angiogenesis and increase collagen production by endothelial cells [22,23]. HA also reduces platelet adhesion and thrombosis. However, sulfated HA derivatives exhibit heparin-like properties, preventing blood coagulation [27]. In terms of angiogenesis, there was a statistically significant difference only between Group 1-A and Group 1-B in the comparison of the groups. Angiogenesis was lower in the Limberg group administered SF compared to the group without SF. The probable reason for this may be explained by both the stimulating and the inhibitory effect of SF during the angiogenesis process.

It is known that HA makes the wound matrix more permeable in terms of fibroblast migration and accelerates wound healing [4,23]. In our study, histopathologically, there was no statistically significant difference in fibroblastic activity between the groups, and it was observed that SF did not increase the fibroblastic activity.

In the healing process which begins immediately after wound formation, neutrophils and macrophages migrate from the circulation to the wound area due to the effect of mediators secreted in the first stage of inflammation, and wound healing occurs as a result of collagen synthesis and contraction with the contribution of other cells [28]. In a study conducted on mice, HA was found to be effective in the restoration of wound matrix and rapid migration of leukocytes [29]. In our study, it was observed that SF did not affect neutrophil leukocyte infiltration.

In conclusion, although the Limberg flap technique is commonly used as a flap method today, it can be said that elliptical rotation flaps is a method that can be used in routine practice due to a lower complication rate. However, SF, a source of HA, which has a role in almost every stage of wound healing, increases epithelization and

plays a regulatory role in angiogenesis. For these reasons, it is concluded that the use of SF as a source of HA in combination with the elliptical rotation flap technique in wounds with material tissue loss will contribute to clinical practice.

STUDY LIMITATIONS

Since the number of subjects in the study is limited, it is necessary to be careful in generalizing the results to the population.

FINANCIAL SUPPORT

This research did not receive any specific grant from funding.

CONFLICT OF INTEREST

The authors declared no conflict of interest.

AUTHOR CONTRIBUTIONS

HÇ - Study design, data collections, data analysis, writing.
UA, TA, EK, UY, HN - Study design, Data collections

REFERENCES

1. Anuk T, Öztürk S, Özaydin İ, Kahramanca Ş, Yayla S, Aksoy Ö, Okumuş Z, Aydın U, Bilgin BÇ, Demirkan İ: Comparison of three fixation methods for the prevention of wound contractions in diabetic and non-diabetic mice with full-thickness skin excision. *Kafkas Univ Vet Fak Derg*, 22 (5): 647-651, 2016. DOI: 10.9775/kvfd.2015.14837
2. Özaydin İ, Aksoy Ö, Yayla S, Kurt B, Kılıç E, Bingöl SA, Can İ, Deprem T: Clinical, histopatological and immunohistochemical evaluation of the effects of topical NPH-insulin on full-thickness open wounds: An *in-vivo* study in diabetic and non-diabetic mice. *Ankara Univ Vet Fak Derg*, 65, 219-228, 2018. DOI: 10.1501/Vetfak_0000002850
3. Kurt B, Bilge N, Sözmen M, Aydın U, Önyay T, Özaydin İ: Effects of *Plantago lanceolata* L. extract on full thickness excisional wound healing in a mouse model. *Biotech Histochem*, 93 (4): 249-257, 2018. DOI: 10.1080/10520295.2017.1421773
4. Özer K, Karabağlı M, Uğurlu K: A new flap model in the treatment of non-healing elbow wounds in dogs: The island arterial composite flap comprising the skin originating from the thoracodorsal artery, the cutaneous trunci muscle and fascia of the latissimus dorsi muscle. *Kafkas Univ Vet Fak Derg*, 22 (6): 829-835, 2016. DOI: 10.9775/kvfd.2016.15425
5. Lee MS, Ahmad T, Lee J, Awada HK, Wang Y, Kim K, Shin H, Yang HS: Dual delivery of growth factors with coacervate-coated poly(lactic-co-glycolic acid) nanofiber improves neovascularization in a Mouse skin flap model. *Biomaterials*, 124, 65-77, 2017. DOI: 10.1016/j.biomaterials.2017.01.036
6. Dehdashtian A, Afshari K, Jazaeri SZ, Haddadi NS, Sheikhi M, Abbaszadeh-Kasbi A, Tavangar SM, Jazaeri F, Amirlak B, Dehpour AR: Sumatriptan increase skin flap survival through activation of 5HT 1b/1d receptors in rats: the mediating role of nitric oxide pathway. *Plast Reconstr Surg*, 144 (1): 70e-77e, 2019. DOI: 10.1097/PRS.0000000000005740
7. Çolak A, Özaydin İ, Okumuş Z, Özcan K, Oral H: Koyunlarda deneysel meme başı lezyonlarının viskoşirurjikal sağaltımı. *Kafkas Univ Vet Fak Derg*, 1 (1-2): 36-41, 1995.
8. Cihan M: Viskoşirurji. *Kafkas Univ Vet Fak Derg*, 4 (1-2): 119-122, 1998.
9. Ermutlu ÇŞ, Kılıç E, Aksoy Ö, Yayla S, Baran V, Dağ S, Ulkay MB, Aydın U, Demirtaş B: Effect of bovine corpus vitreum on full-thickness dermal wound healing: An experimental study in rats. *Kafkas Univ Vet Fak*

Derg, 24 (1): 33-38, 2018. DOI: 10.9775/kvfd.2017.18189

10. Özaydın İ, Ünsaldı E, Aksoy Ö, Yayla S, Kaya M, Ulkay Tunalı MB, Aktaş A, Taşdemiroğlu E, Cihan M, Kurt B, Yıldırım HC, Şengöz A, Erdoğan H: The effect of silicone tube and silicone tube + hyaluronic acid application on adhesion formation in experimental peri- and epineurorrhaphy in a rat model. *Kafkas Univ Vet Fak Derg*, 20 (4): 591-597, 2014. DOI: 10.9775/kvfd.2014.10583

11. Palmer M, Stanford E, Murray MM: The effect of synovial fluid enzymes on the biodegradability of collagen and fibrin clots. *Materials*, 4, 1469-1482, 2011. DOI: 10.3390/ma4081469

12. Sarı R, Akbaba S, Gündoğdu RH, Yazıcıoğlu MÖ: Comparison of the V-Y flap and limberg flap operations in pilonidal sinus surgery. *Türk J Colorectal Dis*, 29, 69-74, 2019. DOI: 10.4274/tjcd.galenos.2018.10437

13. Lee PJ, Raniga S, Biyani DK, Watson AJM, Faragher IG, Frizelle FA: Sacrococcygeal pilonidal disease. *Colorectal Dis*, 10, 639-650, 2008. DOI: 10.1111/j.1463-1318.2008.01509.x

14. Sevinc B, Damburacı N, Karahan Ö: Longterm results of minimally invasive treatment of pilonidal disease by platelet rich plasma. *J Visc Surg*, 157, 33-35, 2020. DOI: 10.1016/j.jvisc.2019.07.004

15. Isik A, Idiz O, Firat D: Novel approaches in pilonidal sinus treatment. *Prague Med Rep*, 117, 145-152, 2016. DOI: 10.14712/23362936.2016.15

16. Sit M, Aktas G, Yilmaz EE: Comparison of three surgical flap techniques in pilonidal sinus surgery. *Am Surg*, 79, 1263-1268, 2013. DOI: 10.1177/000313481307901217

17. Dizen H, Yoldas O, Yıldız M, Cilekar M, Dilektaslı E: Modified elliptical rotation flap for sacrococcygeal pilonidal sinus disease. *ANZ J Surg*, 84, 769-771, 2014. DOI: 10.1111/ans.12818

18. Yoldas O, Dizen H, Cilekar M, Yıldız M, Dilektaslı E: Comparison of modified limberg flap and modified elliptical rotation flap for pilonidal sinus surgery: a retrospective cohort study. *Int J Surg*, 16, 74-77, 2015. DOI: 10.1016/j.ijsu.2015.02.024

19. Gundogdu E: Fasciocutaneous elliptical rotation flap for pilonidal sinus disease and its outcomes. *Türk J Surg*, 36 (3): 310-316, 2020. DOI:

10.47717/turksurg.2020.4917

20. Giji S, Arumugam M: Isolation and characterization of hyaluronic acid from marine organisms. *Adv Food Nutr Res*, 72, 61-77, 2014. DOI: 10.1016/B978-0-12-800269-8.00004-X

21. Lequeux I, Ducasse E, Jouenne T, Thebault P: Addition of antimicrobial properties to hyaluronic acid by grafting of antimicrobial peptide. *Eur Polym J*, 51, 182-190, 2014. DOI: 10.1016/j.eurpolymj.2013.11.012

22. Chen WYJ, Abatangelo G: Functions of hyaluronan in wound repair. *Wound Repair Regen*, 7, 79-89, 1999. DOI: 10.1046/j.1524-475x.1999.00079.x

23. Jiang D, Liang J, Noble PW: Hyaluronan in tissue injury and repair. *Annu Rev Cell Dev Biol*, 23, 435-461, 2007. DOI: 10.1146/annurev.cellbio.23.090506.123337

24. Almond A: Hyaluronan. *Cell Mol Life Sci*, 64 (13): 1591-1596, 2007. DOI: 10.1007/s00018-007-7032-z

25. Girish KS, Kemparaju K: The magic glue hyaluronan and its eraser hyaluronidase: A biological overview. *Life Sci*, 80 (21): 1921-1943, 2007. DOI: 10.1016/j.lfs.2007.02.037

26. Price RD, Berry MG, Navsaria HA: Hyaluronic acid: The scientific and clinical evidence. *J Plast Reconstr Aesthet Surg*, 60, 1110-1119, 2007. DOI: 10.1016/j.bjps.2007.03.005

27. Barbucci R, Magnani A, Casolaro M, Marchettini N, Rosi C, Bosco M: Modification of hyaluronic acid by insertion of sulfate groups to obtain a heparin like molecule. Part I. Characterization and behavior in aqueous solution towards H⁺ and Cu²⁺ ions. *Gazz Chim Ital*, 125, 169-180, 1995.

28. Özler M, Şimşek K, Topal T, Öter Ş, Korkmaz A: Pinealektomili ratlarda yara iyileşmesi. *Gulhane Med J*, 52, 181-184, 2010.

29. Mack JA, Feldman RJ, Itano N, Kimata K, Lauer M, Hascall VC, Maytin EV: Enhanced inflammation and accelerated wound closure following tetraphorbol ester application or full-thickness wounding in mice lacking hyaluronan synthases *Has1* and *Has3*. *J Invest Dermatol*, 132 (1): 198-207, 2012. DOI: 10.1038/jid.2011.248