



RESEARCH ARTICLE

The effects of oleuropein on lung and heart injury in cecal ligation and puncture - induced sepsis

Hüseyin Serkan Erol^{1*}, Tuba Aydın², Serkan Yıldırım³, İsmail Can⁴, Mesut Bünyami Halıcı⁵

¹Kastamonu University, Veterinary Faculty, Department of Biochemistry, Kastamonu, Turkey

²Agri Ibrahim Cecen University, Pharmacy Faculty, Department of Pharmacognosy, Agri, Turkey

³Ataturk University, Veterinary Faculty, Department of Pathology, Erzurum, Turkey

⁴Kafkas University, Medicine Faculty, Department of Histology and Embriology, Kars, Turkey

⁵Ataturk University, Veterinary Faculty, Department of Biochemistry, Erzurum, Turkey

Received:12.05.2020, Accepted: 30.07.2020

*hserol@kastamonu.edu.tr

Oleuropeinin çekal ligasyon ve punktur ile indüklenen sepsiste akciğer ve kalp hasarı üzerine etkileri

Eurasian J Vet Sci, 2020, 36, 3, 221-231

DOI: 10.15312/EurasianJVetSci.2020.282

Öz

Amaç: Sepsis öldürücü ciddi bir klinik hastalıktır. Sepsis durumunda oksidatif stres inflamasyonda önemli bir rol oynar. Bu nedenle çalışmada oleuropeinin (OLE) ve seftriaksonun (CEFT) sepsis üzerine etkileri denenmiştir.

Gereç ve Yöntem: Otuz adet erkek rat Sham, Sepsis, CEFT, OLE-150 ve OLE-300 olmak üzere 5 eşit gruba ayrılarak, model uygulamasından 15 dakika önce 150 mg/kg seftriakson (IP), 150 mg ve 300 mg OLE (PO), uygulandı. Uygulamadan 24 saat sonra kan, akciğer ve kalp dokuları alındı. Serumda kreatin kinaz (CK) ve laktat dehidrojenaz (LDH) düzeyleri ölçülürken, kalp ve akciğer dokularında lipid peroksidasyonu (LPO) ve glutatyon (GSH), süperoksit dismutaz (SOD) ve katalaz (KAT) düzeyleri tespit edildi. Ayrıca, patolojik ve immünohistokimyasal olarak akciğerde interlökin (IL)-8 ve kalpte tümör nekrozis faktör (TNF)- α ekspresyonları belirlendi.

Bulgular: Sepsis CK, LDH, LPO, GSH ve kalp CAT aktivitelerinde önemli bir artışa, SOD ve akciğer CAT aktivitesinde ise belirgin azalmaya neden oldu ($p<0.001$). OLE akciğer ve kalp dokusunda LPO ve GSH seviyelerini anlamlı şekilde düşürmüştü ($p<0.001$), her iki dokuda SOD aktivitesini ve kalp dokusunda CAT aktivitesini arttırmıştır ($p<0.001$). Ayrıca akciğer dokusunda CEFT LPO seviyesini belirgin şekilde düşürmüştü ($p<0.01$), SOD ve CAT aktivitelerini arttırmıştır ($p<0.001$).

Öneri: OLE'nin antioksidan, IL-8 ve TNF- α seviyelerini düşürerek belirgin anti-inflamatuvar etkileri olduğu belirlenmiştir. Bu nedenle, OLE gibi kuvvetli bir antioksidan sepsis tedavisi için faydalı olabilir.

Anahtar kelimeler: Oleuropein, sepsis modellemesi, seftriakson, yangı

Abstract

Aim: Sepsis is a fatal serious clinical disorder. The oxidative stress in sepsis plays an important role in the inflammation. Therefore, the effects of oleuropein (OLE) and ceftriaxone (CEFT) on sepsis were investigated in this study.

Materials and Methods: Thirty male rats were divided into five equal groups: Sham, Sepsis, CEFT, OLE-150 and OLE-300, The 150 mg/kg of ceftriaxone (i.p.), and 150 and 300 mg/kg OLE (p.o.) were administered to the treatment groups fifteen minutes before the experiment. After 24 hours, blood samples, lungs and hearts tissues were taken. The creatine kinase (CK) and lactate dehydrogenase (LDH) activities in serum, lipid peroxidation (LPO), glutathione (GSH), superoxide dismutase (SOD) and catalase (CAT) levels were all determined. In addition, the expressions of the interleukin (IL)-8 in lung and tumor necrosis factor (TNF)- α in heart were pathologically and immunohistochemically were determined.

Results: Sepsis caused significant increases in CK, LDH, LPO, GSH and heart CAT activity and caused inhibition of SOD and lung CAT activity ($p<0.001$). The OLE significantly decreased the LPO and GSH levels ($p<0.001$) and increased the SOD in activity of both tissues and CAT activity in lung tissue ($p<0.001$). Moreover, CEFT significantly decreased the LPO level ($p<0.01$) and increased tissue SOD and CAT activities in lung tissue ($p<0.001$). CK and LDH activities in serum showed marked decrease in OLE and CEFT groups ($p<0.001$).

Conclusion: Antioxidant and a notable anti-inflammatory effect of OLE by reducing IL-8 and TNF- α levels have been stated. Thus, a strong antioxidant, such as OLE, would be beneficial for the treatment of sepsis.

Keywords: Oleuropein, sepsis model, ceftriaxone, inflammation





Introduction

Sepsis is a fatal critical medical disorder that induces multiple-organ dysfunction syndrome (MODS) in humans and in animals (Cadirci et al 2010, Gray 2017). Sepsis is a serious syndrome that is accompanied by pathogens, severe and unstable inflammation (Pandir et al 2019). This deadly situation needs intensive care and may commonly lead to multiple organ dysfunction. The serious inflammation process that occurs leads to impaired microvascular circulation by activating coagulation factors besides causing microvascular changes, vasodilation, hypovolemia and cardiac depression (Wang et al 2017). Hypoxia in tissues occur with unstable blood circulation and leukocyte infiltration caused by increasing permeability (Spanos et al 2010).

Insufficient oxygen concentration trigger energy production from anaerobic pathways. Moreover, low ATP levels occur because of hypoxia induces reactive oxygen species (ROS) leakages through electron transport chains (ETCs) and increase hydrogen peroxide production. Furthermore, a progressively increasing inflammation process exacerbates ROS production by participating in its progress. Activated macrophages in the inflammation process do not just increase inducible nitric oxide synthase (iNOS) activity but also cause increased nitric oxide (NO) production (Bar-Or et al 2015). ETCs reactions gradually decrease in parallel with increased NO level. Furthermore, while ROS exacerbates inflammation, it also reduces endothelium regeneration and production by converting the NO to peroxynitrite (Crimi et al 2007, Erol et al 2019). This mechanism shows how tissue damage occurs by collaboration between ROS and severe inflammation in sepsis. Increased ROS causes irreversible and fatal damage to cell metabolism by devastating the polyunsaturated lipids of the cell membrane, proteins, and even nucleic acids.

Alongside impaired tissue oxygenation and feeding, the pathogens infiltrating into the blood cause severe damage, particularly in the circulatory system, by affecting coagulation factors. After a circulatory system failure, micro emboli, thrombus, and infarctions are formed in tissues by severe inflammation and coagulation because of sepsis. Even though the medical treatments – such as systemic anti-inflammatories, antibiotic drugs, and serums for haemostasis – can alleviate sepsis, many chronic diseases that need long-term treatments occur as a consequence of severe tissue injury and organ dysfunction (Keir and Dickinson 2015). In recent years, studies have proved a strong relationship between inflammation and ROS (Halliwell 2005, Blaser et al 2016, Erol et al 2019). In particular, there are many diseases where excessive increases in ROS trigger the release of inflammatory mediators such as tumor necrosis factor (TNF)- α and nuclear factor (NF)- κ B, these interactions also contribute to the increased severity of the inflammation (Blaser et al 2016).

Oleuropein (OLE) is a well - known polyphenol molecule of the Oleaceae family of plants with a secoiridoid glycoside structure (Hassen et al 2015). It features scavenging activity against superoxide radicals and performs this activity by virtue of having hydroxyl groups in its structure, which allows it to be a donor of hydroxyl. Because of its inhibiting activities and release of some important mediators and enzymes that participate in inflammatory processes, such as NF- κ B, cyclooxygenase (COX), TNF- α , and interleukin (IL)-1 β , OLE has strong anti-inflammatory activity (Feng et al 2017, Şahin et al 2017, Qabaha et al 2018). Moreover, in previous studies, the antioxidant, anti-inflammatory, antimicrobial, cardioprotective, neuroprotective, hepatoprotective, antidiabetic, gastroprotective, anti-obesity properties and lipid metabolism regulatory effects of oleuropein have all been reported (Cicerale et al 2012, Hassen et al 2015, Pourkhodadad et al 2016).

The pathology of sepsis involves a significant and complex interaction between the severe inflammatory, pathogens, and oxidative stress. Therefore, OLE, which has been found its antioxidant, anti-inflammatory and antimicrobial effects in previous studies, was investigated on the cecal ligation and puncture (CLP)-induced sepsis model in rats. The aim of the study is to reveal the effects of it on the pathology of sepsis, the inflammation and oxidative stress.

Material and Methods

Oleuropein leaf extract and identification of its molecular structure

Oleuropein purified from the leaves of the *Olea europea*, which collected from the Kilis region in Turkey, was extracted and identified by using chromatographic methods according to Kisa et al (2018).

Animal model

The study was approved by Ataturk University Local Ethics Council of Animal Experiments (Acceptance no. 1700334699, Decision no.165). Thirty male Wistar rats were divided into five groups (n=6) as sham, sepsis, CEFT, OLE-150 and OLE-300. Before the study began, the rats were held in standard conditions; 12 hours of light/12 hours dark, a room temperature of 25 °C and ad libitum access to food and water. Dose of OLE in the current study was decided according to Geyikoglu et al (2017) and Koc et al (2018). The OLE was prepared as a suspension in distilled water (7.5 mg OLE/ml distilled water) and was given orally to the rats once (150 mg/kg and 300 mg/kg) 15 minutes before performing the CLP. The ceftriaxone (Cephaxon ® 1 g IV, Toprak Ilac, Turkey) was chosen to be a reference drug for comparing the effects of OLE



on the sepsis and intraperitoneally injected at a dose of 150 mg/kg 15 minutes before performing the CLP. The xylazine-ketamine anesthesia was performed to all rats and CLP was performed by making an incision on the right area of the abdomen. The cecum was perforated with four identical holes using a 20-gauge cannula, except for the sham group. Some feces were removed by finger pressure and the cecum was sutured using 2-0 silk approximately 1 cm from the appendix. After CLP administration, the incision was closed by sutures (2-0 plain catgut). After 24 hours, the rats were euthanized by performing cervical dislocation under a high dose of anesthesia, and blood samples were collected in serum tubes (Vacutainer SST II Advance, BD, USA) via a 5 ml injector from the heart. The serum was collected in eppendorf tubes after centrifugation at 3500 rpm for 7 minutes and kept at -80°C until tested. For analyzing of lipid peroxidation (LPO), superoxide dismutase (SOD), glutathione (GSH) and catalase (CAT), lung and heart tissues were put into sterile petri dishes. In addition, for performing histopathological investigations, the tissues were kept into a 7% formalin solution.

Preparation of the tissue homogenates

The lung and heart tissues were powdered in liquid nitrogen by using a mortar. Then, 25 mg of tissue was weighed into sterile eppendorf tubes and freshly prepared homogenate buffers were added to the tubes (LPO: 10% KCl, SOD: 50 mM KH_2PO_4 , 10 mM EDTA; GSH: 50 mM Tris-HCl and CAT: 50 mM KH_2PO_4 at a pH of 7). The tissues in the buffer were homogenized at 35 Hz for 1 minute by adding a sterile 5 mm steel ball into the tubes (Qiagen Tissuelyser II, Germany). Afterwards, the homogenates were centrifuged at 4°C and 4000 rpm for 30 minutes (for LPO and GSH), 6000 rpm for 1 hour (for SOD), and 8500 rpm for 1 hour (for CAT) by using a refrigerated centrifuge (Rotina 380r, Hettich, Germany). The supernatants were used for the determination of parameters of concerns using methods previously described.

Determination of the tissue LPO, GSH, SOD and CAT

To determine the LPO level in tissue, a method based on the reaction between thiobarbituric acid and malondialdehyde (MDA) was used (Ohkawa et al 1979). Determination of the tissue LPO level was evaluated by reading samples at a wavelength of 532 nm with a spectrophotometer (EPOCH, Bio-Tek, USA) and recorded as nmol/g tissue after preparation by using a standard graphic with 1,1,3,3-tetraethoxypropane as the MDA standard.

A method based on a reaction that generates formazan dye from superoxide radicals generated by xanthine oxidase and 4-nitro blue tetrazolium chloride, was used to determine SOD activity in the tissue (Sun et al 1988). Determination of tissue SOD activity was evaluated by reading samples at a wavelength of 560 nm with a spectrophotometer (EPOCH,

Bio - Tek, USA) and recorded as U/mg tissue.

To determine the GSH level in the tissue, a method based on the reaction between 5,5-dithio-bis-(2-nitrobenzoic acid) and the sulfhydryl group of GSH was used (Sedlak and Lindsay 1968). Determination of tissue GSH level was evaluated by reading samples at a wavelength of 412 nm with a spectrophotometer and recorded as nmol/mg tissue after preparing a standard graphic by using GSH reduced (Sigma, USA) as the GSH standard.

The method based on a reaction that generates water from enzymes and H_2O_2 , was used to determine the CAT activity in tissue (Aebi 1984). Samples were kinetically read at a wavelength of 240 nm using a quartz plate (Hellma, Germany) with a spectrophotometer and recorded as $\mu\text{mol}/\text{min}/\text{mg}$ tissue.

Determination of serum CK and LDH activities

To determine the serum CK and LDH activity, commercial kits (Erba Lachema XL SysPack, Czech Republic) were used as instructed by the manufacturer. Results were evaluated by using a formula, generated from standard graphics prepared with normal (ERBA Norm, Czech Republic), pathological (ERBA Path, Czech Republic) and multi serum (ERBA Multi, Czech Republic). The results were recorded as U/L.

Histopathological examination

The tissue samples obtained at necropsy were soaked in a 10% formalin solution. After fixing over 48 hours, the tissues were washed in fresh water for 10 hours and embedded into paraffin blocks. The $4\ \mu\text{m}$ sections sliced from each block were mounted on slides. The slides were stained with hematoxylin-eosin for examination under a light microscope (Olympus BX51, Japan). The images were captured using a digital camera (Olympus DP72, Japan). The findings were evaluated according to the degree of pathological events as none (–), mild (+), moderate (++) and severe (+++).

Immunohistochemical examination

All slides for immunoperoxidase examination were prepared by passing the tissue through increasing concentrations of alcohol (to replace the water) and then replacing the alcohol with xylol to dehydrate and clear them. In this way, endogenous peroxidase inactivation was provided by incubating slides in 3% hydrogen peroxide for 10 minutes after washing in PBS. The procedure was performed twice for 5 minutes at 500 watts in a microwave by using a retrieval solution to detect the antigens. After cooling, samples were incubated with TNF- α (sc-52746, Santa Cruz, USA) and IL-8 (sc-376750, Santa Cruz, USA) antibodies at 37°C for 1 hour as instructed (ab102890, Abcam, USA), and 3-3' diaminobenzidine (DAB)



was used as a chromogen. The background was stained with hematoxylin. The stained slides were evaluated according to immunopositivity as being none (–), slight (+), moderate (++) and severe (+++).

Statistical analysis

Statistical analyses of the biochemical results were performed using Prism 8.0 software, and statistical significances were determined by ANOVA (One-way Analysis of Variance) test. The Tukey test was used for multiple comparisons of groups. Histopathological results were analyzed by using the non-parametric Kruskal - Wallis test and Mann Whitney U test for paired comparisons. The significant level was set at $p<0.05$.

Results

The LPO levels of lung and heart tissues shown in Figure 1a and 1b significantly increased by sepsis (lung: 102.8 ± 5.56 , heart: 524.0 ± 29.60) compared to the sham group (lung: 76.56 ± 4.83 , heart: 316.2 ± 19.08) ($p<0.001$). The CEFT group had markedly decreased LPO levels in the lung (92.56 ± 2.964 , $p<0.01$) and heart tissues (429.3 ± 23.17 , $p<0.001$).

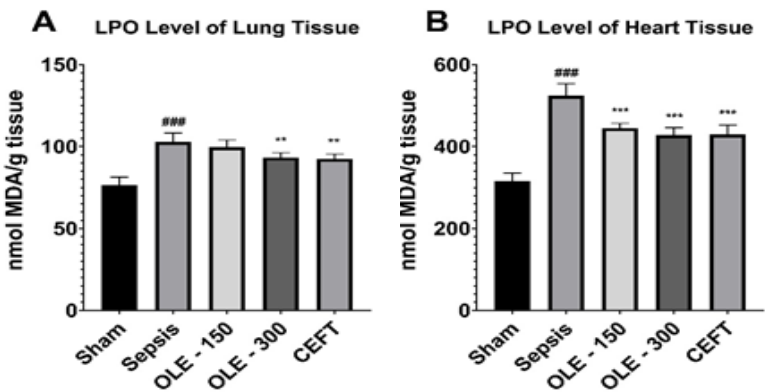


Figure 1. The lipid peroxidation (LPO) levels of lung (A) and heart (B) tissues.
*: $p<0.05$, **: $p<0.01$ and ***: $p<0.001$ indicate the significant difference compared to sepsis group. #: $p<0.05$, ##: $p<0.01$ and ###: $p<0.001$ indicate the significant difference compared to sham group

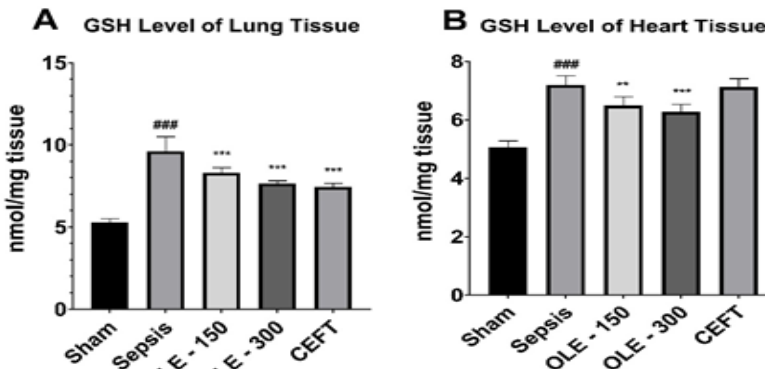


Figure 3. The glutathione (GSH) levels of lung (A) and heart (B) tissues.
*: $p<0.05$, **: $p<0.01$ and ***: $p<0.001$ indicate the significant difference compared to sepsis group. #: $p<0.05$, ##: $p<0.01$ and ###: $p<0.001$ indicate the significant difference compared to sham group.

Although the OLE at a 150 mg/kg dose did not show a significant decrease in LPO levels of lung tissue (99.67 ± 4.27) ($p>0.05$), the OLE at 300 mg/kg dose had markedly decreased levels in both tissue types (lung: 93.33 ± 2.89 , $p<0.01$, heart: 427.3 ± 23.17 , $p<0.001$).

The SOD activity is shown in Figure 2a and 2b was significantly decreased in the sepsis group (lung: 28.86 ± 0.27 , heart: 32.28 ± 0.22) compared to the sham group ($p<0.001$). In lung tissues, the CEFT (28.51 ± 0.90) and OLE at 150 (29.66 ± 0.34) and 300 mg (35.97 ± 0.33) doses had markedly increased activity compared to the sepsis group (28.86 ± 0.27) ($p<0.001$). Even though the 150 mg/kg dose OLE (31.92 ± 0.59) did not significantly increase SOD activity in heart tissue ($p>0.05$), the activity in the CEFT (33.34 ± 0.15) and OLE at 300 mg/kg dose (35.83 ± 0.29) markedly increased ($p<0.001$).

The amount of GSH is shown in Figure 3a and 3b significantly increased in the sepsis group (lung: 9.62 ± 0.88 , heart: 7.19 ± 0.31) compared to the sham group (lung: 5.28 ± 0.23 , heart: 5.05 ± 0.22) ($p<0.001$). The CEFT (7.45 ± 0.21) and OLE at 150 (8.32 ± 0.31) and 300 mg doses (7.66 ± 0.16) had markedly decreased GSH levels in lung tissue ($p<0.001$). Although the CEFT (7.12 ± 0.29) did not significantly decre-

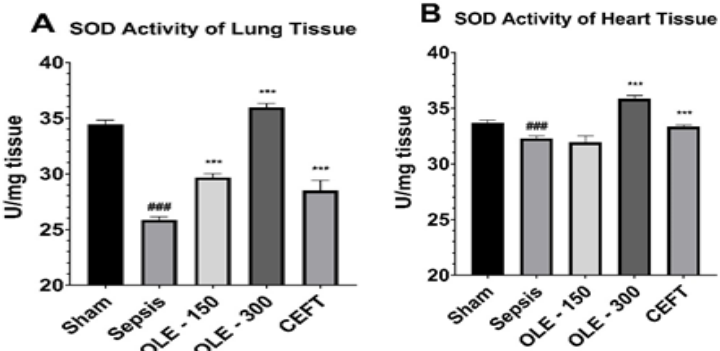


Figure 2. The superoxide dismutase (SOD) activities of lung (A) and heart (B) tissues.
*: $p<0.05$, **: $p<0.01$ and ***: $p<0.001$ indicate the significant difference compared to sepsis group. #: $p<0.05$, ##: $p<0.01$ and ###: $p<0.001$ indicate the significant difference compared to sham group

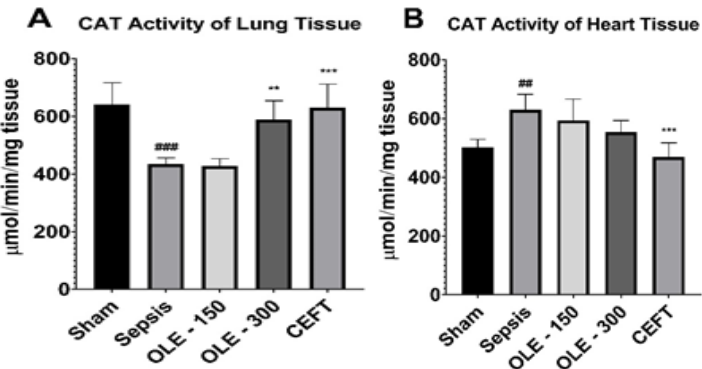


Figure 4. The catalase (CAT) activities of lung (A) and heart (B) tissues.
*: $p<0.05$, **: $p<0.01$ and ***: $p<0.001$ indicate the significant difference compared to sepsis group. #: $p<0.05$, ##: $p<0.01$ and ###: $p<0.001$ indicate the significant difference compared to sham group



ase GSH levels in the heart tissue ($p>0.05$), the OLE at 150 (6.49 ± 0.30) and 300 mg/kg doses (6.23 ± 0.25) did markedly decrease levels in both tissues ($p<0.001$).

The CAT activity is shown in Figure 4a and 4b. In lung tissue, the activity significantly decreased in the sepsis group (433.4 ± 22.02) compared to the sham group (639.9 ± 76.42)

($p<0.001$). On the other hand, the activity significantly increased in the sepsis group (629.4 ± 52.85) compared to the sham group (500.8 ± 28.33) for heart tissue ($p<0.001$). In lung tissue, the CEFT (629.4 ± 82.03) and OLE at the 300 mg dose (587.7 ± 66.23) showed marked increase in CAT activity compared to the sepsis group ($p<0.01$), whereas the OLE at the 150 mg/kg dose (427.0 ± 25.83) did not show a significant effect ($p>0.05$).

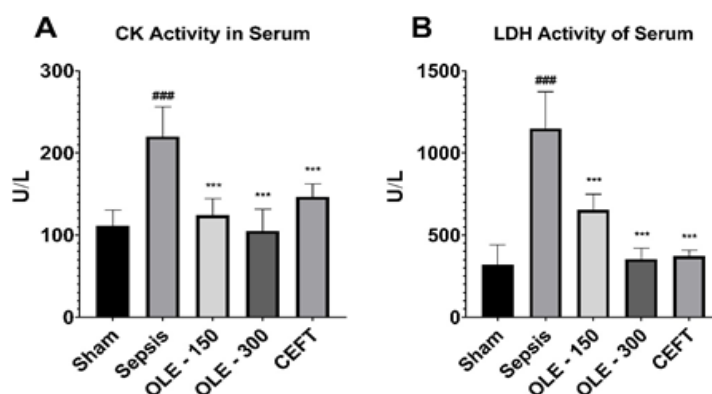


Figure 5. The total creatine kinase (CK) activity and lactate dehydrogenase (LDH) activity in serum.

*: $p<0.05$, **: $p<0.01$ and ***: $p<0.001$ indicate the significant difference compared to sepsis group. #: $p<0.05$, ##: $p<0.01$ and ###: $p<0.001$ indicate the significant difference compared to sham group

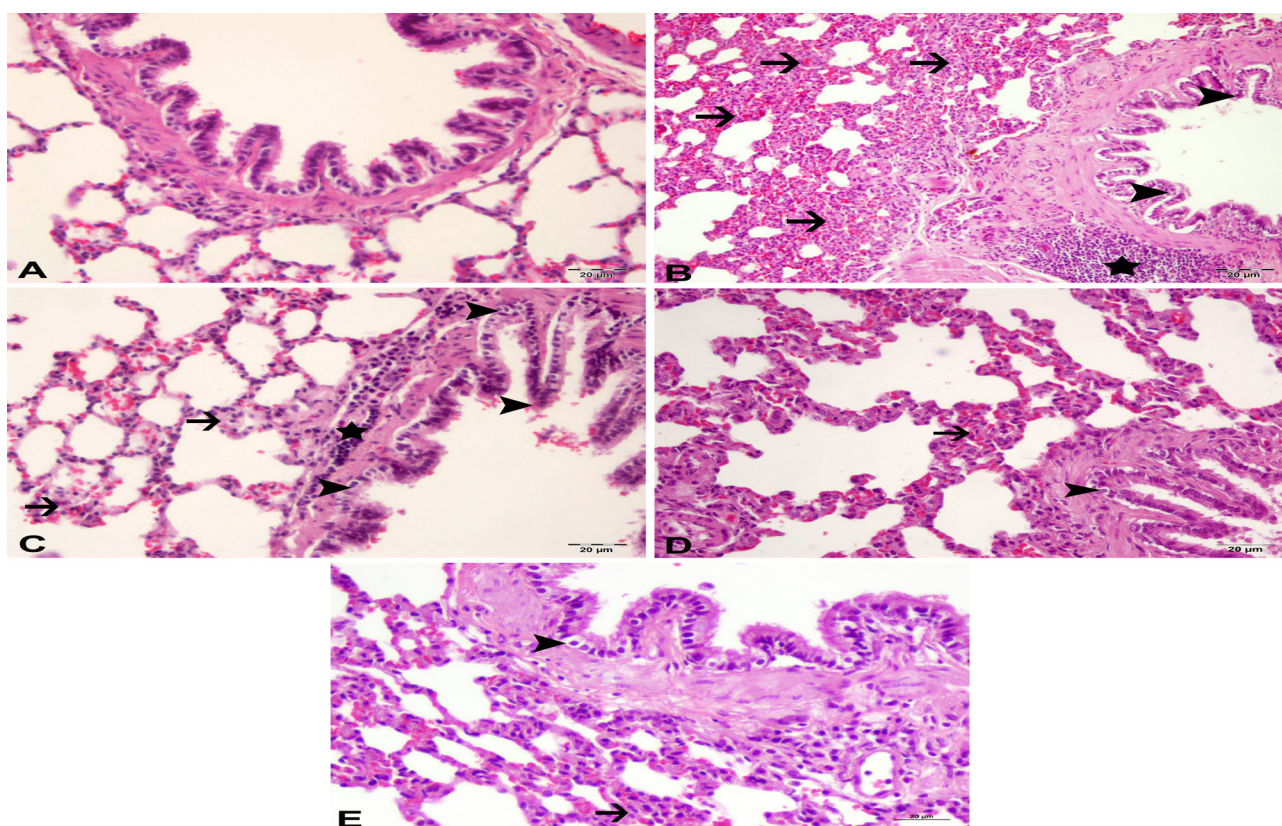


Figure 6. Histopathological examination of lung tissues.

Sham group: (A) normal histopathological view. Sepsis group: (B) severe necrosis and degeneration in bronchial mucosa epithelium (arrowheads) (+++), peribronchial cell infiltration (star) (+++), edema and thickening due to mononuclear cell infiltration in interstitial tissue (arrows) (+++), severe hyperemia in vessels. OLE - 150 group: (C) moderate degeneration and necrosis in bronchial epithelium (arrowheads) (++), thickening in the interalveolar areas (arrows) (++), peribronchial cell infiltration (star) (++). OLE - 300 group: (D) slight degeneration in bronchial epithelium (arrowhead) (+), slight thickening in interalveolar area (arrow) (+). CEFT group: (E) slight degeneration in bronchial epithelium (arrowhead) (+), slight thickening in interalveolar area (arrow) (+). difference compared to sham group

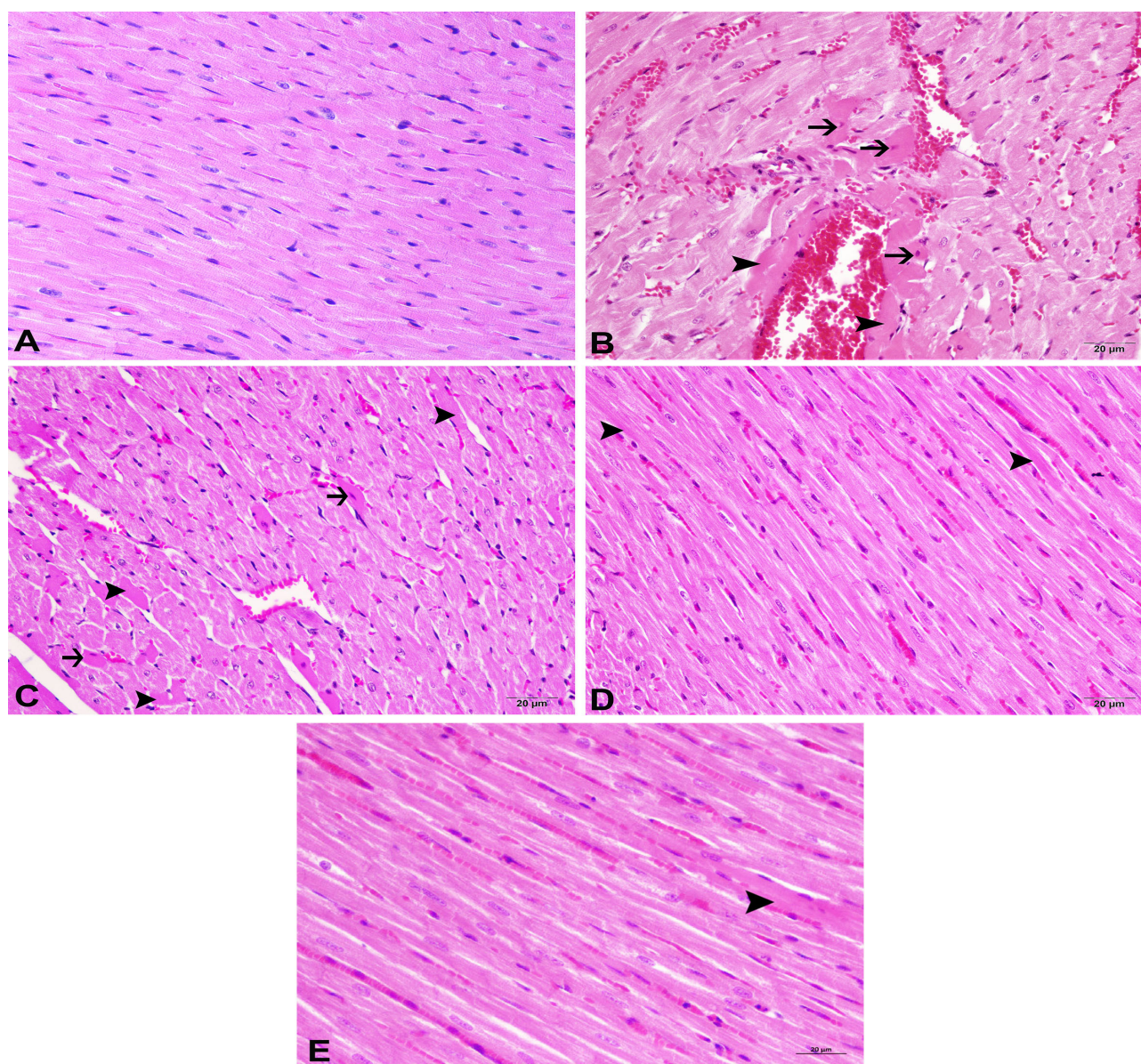


Figure 7. Histopathological examination of heart tissues.

Sham group: (A) normal histopathological view (-) (A). Sepsis group: (B) severe hyaline degeneration in myofibrils (arrowheads) (+++), Zenker necrosis (arrows) (+++) and severe hyperemia in vessels (+++). OLE - 150 group: (C) moderate hyaline degeneration in myofibrils (arrowheads) (++), a few Zenker necrosis (arrows) (++) and moderate hyperemia in vessels (++). OLE - 300 group: (D) slight degeneration in myofibrils (arrowheads) (+), slight hyperemia in vessels (+). CEFT group: (E) very slight degeneration in myofibrils (arrowheads) (+) and hyperemia in interstitial vessels (+)

In heart tissue, the CEFT (468.7 ± 48.07) had significantly decreased activity ($p < 0.001$), but the OLE at both 150 (593.1 ± 72.74) and 300 mg doses (553.3 ± 39.49) did not show any significant effect on activity compared to the sepsis group (629.4 ± 52.85) ($p > 0.05$).

The total CK and LDH activities are shown in Figure 5a and 5b significantly increased in the sepsis group (CK-MB: 220.2 ± 35.86 , LDH: 1149.0 ± 224.1) compared to the sham group (CK-MB: 111.6 ± 18.85 , LDH: 318.7 ± 122.4) ($p < 0.001$). The CEFT (CK-MB: 146.7 ± 15.65 , LDH: 373.4 ± 34.28), OLE at 150 (CK-MB: 124.3 ± 20.1 , LDH: 654.1 ± 95.0) and 300 mg

doses (354.4 ± 34.28) showed marked decrease in activity compared to the sepsis group (CK-MB: 220.2 ± 35.86 , LDH: 1149.0 ± 224.1) ($p < 0.001$).

The sepsis findings in Figure 6 showed severe peribronchial cell infiltrations, hyperemia in vessels, interstitial edema, and thickening dependent on mononuclear cell infiltrations. Also, severe degeneration and necrosis in bronchial mucosa were observed in the sepsis group. According to result of statistical analysis, the sepsis group was significantly different from treatment and sham groups ($p < 0.05$). Treatments with the dose-dependent OLE (150 mg/kg: ++, 300 mg/kg: +) and



CEFT (+) reduced the severity of the findings ($p < 0.05$).

The sepsis findings in Figure 7 showed severe hyperemia, hemorrhage, severe hyaline degeneration and Zenker necrosis in myofibrils (+++). There were significant differences between sepsis and sham groups ($p < 0.05$). Treatments with OLE at 300 mg/kg dose (++) ($p < 0.05$) and CEFT (+) ($p < 0.05$) lessened the severity of the findings.

Immunohistochemical examination of lung tissue revealed severe IL-8 expressions in peribronchial, alveolar and perivascular areas in the sepsis group (Figure 8), whereas they were negative in the sham group (-). The expression in sepsis group was significantly different from sham and treatment groups ($p < 0.05$). The IL-8 expression was slightly positive in the CEFT and OLE-300 group (+) ($p < 0.05$), and moderately positive in the OLE-150 group (++) ($p < 0.05$).

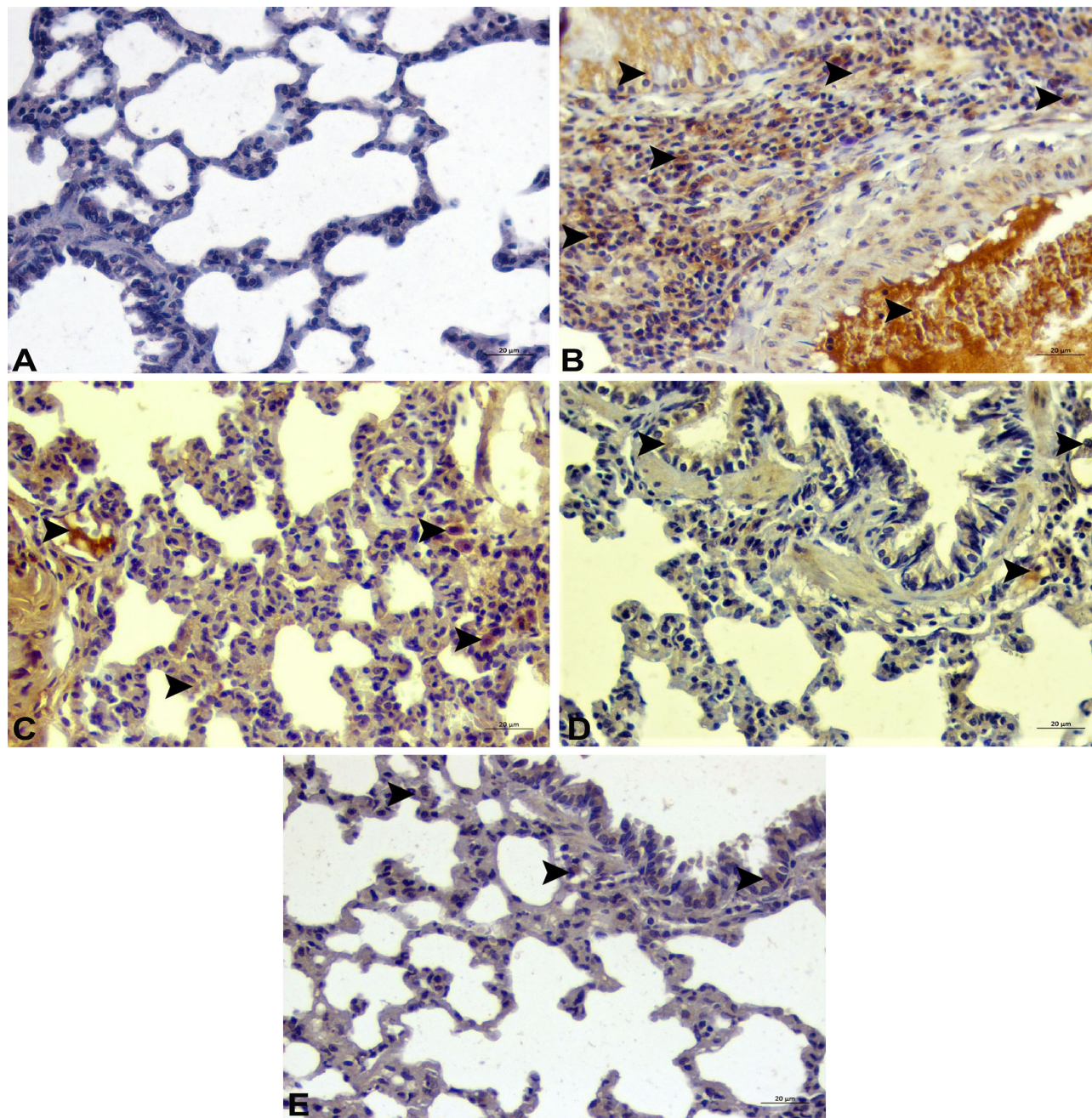


Figure 8. Interleukin-8 (IL - 8) expressions of lung tissues.

Sham group: (A) non-expressed IL-8 (-). Sepsis group: (B) severe expression in peribronchial cell infiltration, vessels, bronchi-bronchial epithelium, and alveolar macrophages (arrowheads) (+++). OLE - 150 group: (C) moderate expressions of IL-8 in vessels and alveolar macrophages (arrowheads) (++) . OLE - 300 group: (D) slight expressions in bronchial epithelium and alveolar macrophages (arrowheads) (+). CEFT group: (E) slight expressions in bronchial epithelium and alveolar macrophages (arrowheads) (+).

The heart TNF- α expression shown in Figure 9 was observed as being severe positive, particularly at the necrotic areas in the heart tissues (+++) in the sepsis group, whereas they were negative in the sham group (-). The expression in sepsis group was significantly different from sham and treatment groups ($p<0.05$). The TNF- α expression was slightly positive in the CEFT and OLE-300 group (+) ($p<0.05$), and moderately positive in the OLE-150 group (++) ($p<0.05$).

Discussion

As a result of oxidative stress, i.e. lipid peroxidation, malondialdehyde (MDA) occurs in injured cell membranes. Therefore, the determination of the amount of MDA in tissues is an important parameter for revealing the degree of tissue injury. In the present study, sepsis significantly increased LPO levels in lung and heart tissues, and oleuropein markedly

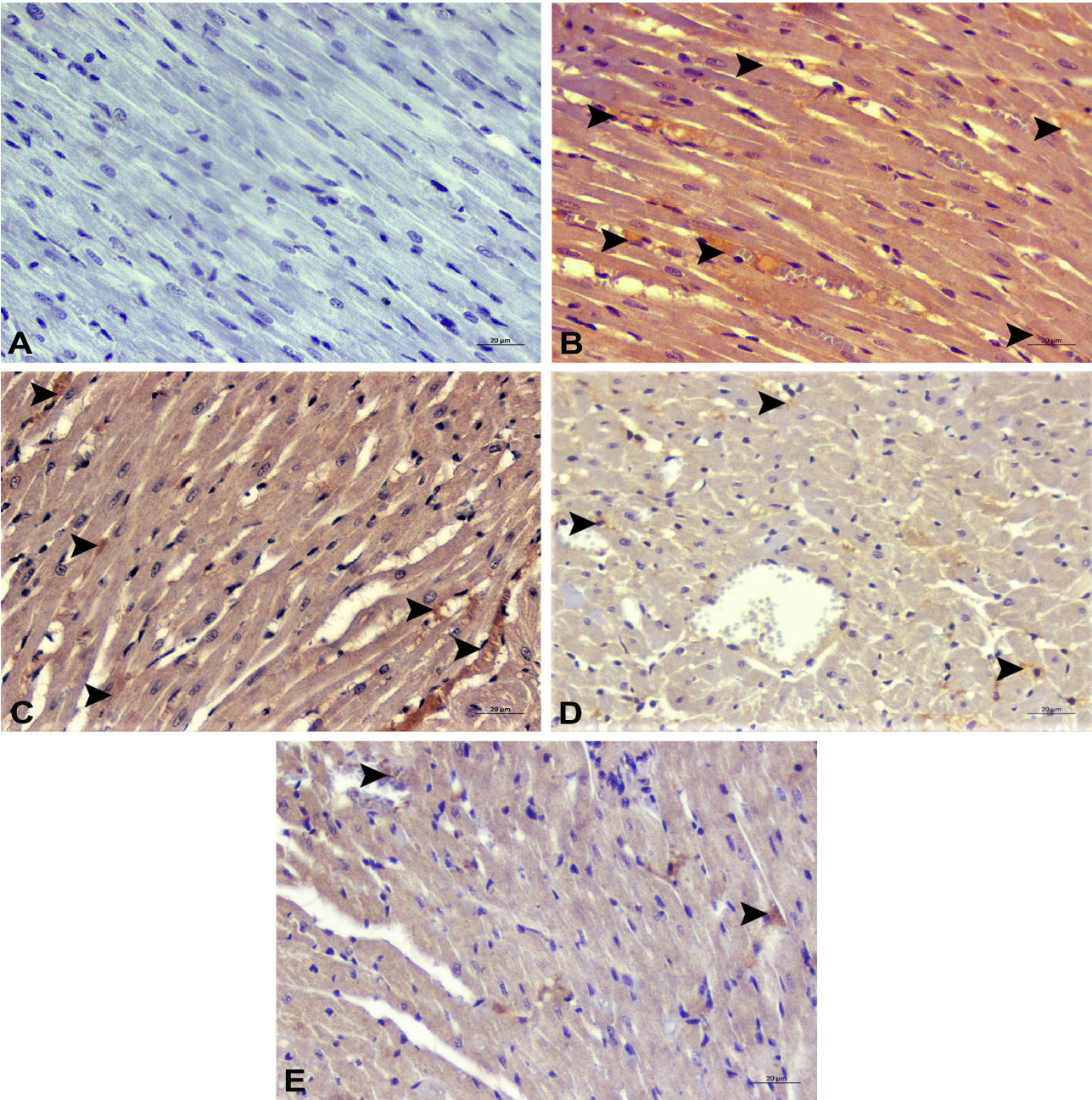


Figure 9. Tumor necrosis factor- α (TNF- α) expressions for heart tissues
Sham group: (A) non-expressed TNF- α (-). Sepsis group: (B) severe expression in interstitial areas and vessels (arrowheads) (+++). OLE-150 group: (C) moderate expressions of TNF- α in vessels and interstitial areas (arrowheads) (++). OLE - 300 group: (D) slight expressions of TNF- α in interstitial areas and vessels (arrowheads) (+). CEFT group: (E) very slight expressions of TNF- α in interstitial areas and vessels (arrowheads) (+).



decreased the levels, particularly at the 300 mg/kg dose (Figure 1). Similarly, in a previous study on cisplatin-induced lung injury, oleuropein significantly increased the total antioxidant level, and decreased the total oxidant, 8-OH-dG, and MDA levels, particularly at the 200 mg/kg dose (Geyikoglu et al 2017). Also, oleuropein at different doses (20 to 80 mg/kg) significantly decreased the MDA level in a group dosed only at 80 mg/kg in a previous study on bleomycin-induced lung fibrosis rat model (Khalili et al 2018). It has been previously stated that OLE has a scavenging effect (Kruk et al 2005), SOD-like activity (Lee and Lee 2010) and inhibits ROS production (Park et al 2017). In the current study, OLE decreased the LPO level of tissues by reducing oxidative stress and improving antioxidant status in parallel with the previous studies.

The SOD enzyme is a member of the antioxidant defense system which converts ROS, which is responsible for the destructive oxidation in the cell, to H_2O_2 . The inhibition of SOD causes substantial deactivation of angiogenesis, hence tissue oxygenation and feeding arrive at an irrecoverable state (Marikovsky et al 2003). Significant inhibition of SOD activity in the sepsis groups of lung and heart tissues was observed in this study. In lung tissue, OLE significantly increased the SOD activity, which markedly inhibited sepsis at both doses; however, only OLE at the 300 mg/kg dose increased the activity in heart tissue (Figure 2). It was reported that oral administration of OLE at 10 and 15 mg/kg doses for ten days did not show significant increases in SOD activity in kidney tissues, whereas LPS decreased the activity (Alirezaei et al 2015). In another study on an LPS-induced sepsis model, it was stated that although SOD activity decreased in the lungs, no significant change in expression was observed (Constantino et al 2014). However, sepsis causes leakage of lysosomal hydrolytic enzymes and severe damage to the tissues (Rocha et al 2012). This tissue damage lead to inhibition of the SOD activity. Therefore, parallel with the pathological findings, significant increases in SOD activities of the OLE groups were observed in the current study.

In the antioxidant mechanism, GSH is responsible for converting the toxic H_2O_2 that is produced by SOD to water and oxygen. This conversion is achieved by using the GSH as a substrate for a reduction reaction that eliminates hydroxyl radicals and H_2O_2 with glutathione peroxidase (GPx). Though the GSH levels were increased by sepsis in both tissues, OLE significantly decreased the levels (Figure 3). By contrast, it was reported that in the LPS induced-sepsis model, significant inhibition of GPx in renal tissue was determined and OLE markedly increased activity (Alirezaei et al 2015). The proinflammatory cytokines (TNF- α and IL-1 β) induces GSH synthesis and increases GSH level of the cell (Biolo et al 2007). Thus, the GSH levels of the tissues increased in the sepsis groups which initiated increasing cytokine release in the current study.

Another structure for eliminating H_2O_2 , which is generated by SOD activity in cells, is the catalase enzyme (CAT). The CAT enzyme includes an iron atom in its structure and converts H_2O_2 to oxygen and water. Whereas in sepsis, CAT activity increased in the lung tissue, the activity significantly decreased in the heart tissue (Figure 4). Either the differences in antioxidant responses of the tissues may be attributed to different structures and various organelles, or an alteration in their expressions occurs. Moreover, according to its lethality, sepsis generates the SOD/CAT imbalance in cells (Andrades et al 2005). Though imbalanced SOD/CAT activity was observed in the heart tissue, activity of the lung tissue in the study was supported by previous studies on experimental sepsis model (Cadirci et al 2010, Ozogul et al 2015)

The IL-8 in the lung is responsible for activating mononuclear cells by linking to its specific receptor, and the activated mononuclear cells cause an acute inflammation process by initiating pro-inflammatory cytokine releases (Allen and Kurdowska 2013). Increased TNF- α expression in sepsis is an indicator of inflammation in heart tissue, just as it is in lung tissue. Moreover, increased ROS in sepsis initiates critical inflammation by leading to pro-inflammatory cytokine release (TNF- α , IL-6, LTB4, etc.) and excessive activity of NF- κ B, which plays an important role in apoptosis (Wang et al 2017). The inhibitory effects of OLE on iNOS and COX-2 enzyme activities and pro-inflammatory mediators (IL-6, IL-1 β and NF- κ B) releases were reported in a previous study on an LPS-induced sepsis model in the cell culture of zebrafish (Ryu et al 2015). Moreover, in a previous study, OLE decreased the blood TNF- α level in LPS-induced sepsis model in rabbits (Giamarellos-Bourboulis et al 2006). In the same study, it was reported that the decreased levels of TNF- α supported the presence of a modulator role of OLE on the proinflammatory cytokine secretion. This current study observed OLE decreasing expressions of IL-8 in the lung tissue and TNF- α in the heart tissue (Figure 8 and 9). A significant decrease in LPO level of tissue indicates reducing amount of ROS which induce proinflammatory cytokines in the tissue. Thus, OLE inhibited the cytokine release which caused by sepsis and this showed a remarkable anti-inflammatory property by reducing the cytokine production in the current study.

Conclusion

In conclusion, the inflammation and oxidative stress produced by sepsis caused serious tissue damages in lung and heart. According to the current study results, a notable anti-inflammatory effect of OLE by means of reducing cytokine releases such as TNF- α and IL-8 has been stated. Oleuropein, also known as a strong antioxidant agent, regulated the antioxidant system of the tissues and reduced the tissue LPO levels. Moreover, OLE treatment led to significant histopathological ameliorations of the structure of tissues by reducing oxidative stress and cytokine releases. Therefore, OLE may



be beneficial in the treatment of sepsis.

Acknowledgement

This article has been presented as oral presentation at the 2nd International Conference on “Veterinary Biochemistry and Clinical Biocehmistry: Advances and Challenges in Understanding The Mechanism of Diseases”.

Conflict of Interest

The authors did not report any conflict of interest or financial support.

Funding

During this study, any pharmaceutical company which has a direct connection with the research subject, a company that provides and / or manufactures medical instruments, equipment and materials or any commercial company may have a negative impact on the decision to be made during the evaluation process of the study. or no moral support.

References

Aebi H, 1984. Catalase in vitro. *Methods Enzymol*, 105, 121-126.

Alirezaei M, Dezfoulan O, Kheradmand A, 2015. Novel Antioxidant properties of ghrelin and oleuropein versus lipopolysaccharide-mediated renal failure in rats. *Int J Pept Res Ther*, 21(4), 411-421.

Allen TC, Kurdowska A, 2013. Interleukin 8 and acute lung injury. *Arch Pathol Lab Med*, 138(2), 266-269.

Andrades M, Ritter C, Moreira JCF, Dal-Pizzol F, 2005. Oxidative Parameters Differences during Non-Lethal and Lethal Sepsis Development1. *J Surg Res*, 125(1), 68-72.

Bar-Or D, Carrick MM, Mains CW, Rael LT et al., 2015. Sepsis, oxidative stress, and hypoxia: are there clues to better treatment? *Redox Rep*, 20(5), 193-197.

Biolo G, Antonione R, De Cicco M, 2007. Glutathione metabolism in sepsis. *Crit Care Med*, 35(9 Suppl), S591-595.

Blaser H, Dostert C, Mak TW, Brenner D, 2016. TNF and ROS crosstalk in inflammation. *Trends Cell Biol*, 26(4), 249-261.

Cadirci E, Altunkaynak BZ, Halici Z, Odabasoglu F et al., 2010. α-lipoic acid as a potential target for the treatment of lung injury caused by cecal ligation and puncture-induced sepsis model in rats. *Shock*, 33(5), 479-484.

Cicerale S, Lucas L, Keast R, 2012. Antimicrobial, antioxidant and anti-inflammatory phenolic activities in extra virgin olive oil. *Curr Opin Biotechnol*, 23(2), 129-135.

Constantino L, Gonçalves RC, Giombelli VR, Tomasi CD et al., 2014. Regulation of lung oxidative damage by endogenous superoxide dismutase in sepsis. *Intensive Care Med Exp*, 2(1), 17.

Crimi E, Ignarro L, Napoli C, 2007. Microcirculation and oxidative stress. *Free Radic Res*, 41(12), 1364-1375.

Erol N, Saglam L, Saglam YS, Erol HS et al., 2019. The Protection Potential of Antioxidant Vitamins Against Acute Respiratory Distress Syndrome: a Rat Trial. *Inflammation*, 42(5), 1585-1594.

Feng Z, Li X, Lin J, Zheng W et al., 2017. Oleuropein inhibits the IL-1β-induced expression of inflammatory mediators by suppressing the activation of NF-κB and MAPKs in human osteoarthritis chondrocytes. *Food Funct*, 8(10), 3737-3744.

Geyikoglu F, Isikgoz H, Onalan H, Colak S et al., 2017. Impact of high-dose oleuropein on cisplatin-induced oxidative stress, genotoxicity and pathological changes in rat stomach and lung. *J Asian Nat Prod Res*, 19(12), 1214-1231.

Giamarellos-Bourboulis EJ, Geladopoulos T, Chrisofos M, Koutoukas P et al., 2006. Oleuropein: a novel immunomodulator conferring prolonged survival in experimental sepsis by *Pseudomonas aeruginosa*. *Shock*, 26(4), 410-416.

Gray K, 2017. Introduction of a sepsis bundle in the ICU and ER: a case-based discussion. *Vet Nurs J*, 32(12), 365-368.

Halliwell B, 2005. Free radicals and other reactive species in disease. *eLS*, 1-9.

Hassen I, Casabianca H, Hosni K, 2015. Biological activities of the natural antioxidant oleuropein: Exceeding the expectation–A mini-review. *J Funct Foods*, 18, 926-940.

Keir I, Dickinson AE, 2015. The role of antimicrobials in the treatment of sepsis and critical illness-related bacterial infections: Examination of the evidence. *J Vet Emerg Crit Care*, 25(1), 55-62.

Khalili HR, Adeli Behrooz HR, Rashidi Nooshabadi MR, Geravandi S et al., 2018. Evaluation of potential anti-fibrotic effect of oleuropein on bleomycin-induced pulmonary fibrosis in rat. *Toxin Rev*, 1-9.

Kısa A, Akyüz M, Çoğun HY, Kordali Ş et al., 2018. Effects of *Olea europaea* L. leaf metabolites on the tilapia (*Oreochromis niloticus*) and three stored pests, *Sitophilus granarius*, *Tribolium confusum* and *Acanthoscelides obtectus*. *Rec Nat Prod*, 12(3), 201.

Koc K, Cerig S, Ucar S, Colak S et al., 2018. Gastroprotective effects of oleuropein and thymol on indomethacin-induced gastric ulcer in Sprague-Dawley rats. *Drug Chem Toxicol*, 1-13.

Kruk I, Aboul-Enein HY, Michalska T, Lichsztekd K et al., 2005. Scavenging of reactive oxygen species by the plant phenols genistein and oleuropein. *Luminescence*, 20(2), 81-89.

Lee O-H, Lee B-Y, 2010. Antioxidant and antimicrobial activities of individual and combined phenolics in *Olea europaea* leaf extract. *Bioresour Technol*, 101(10), 3751-3754.

Marikovskyy M, Ziv V, Nevo N, Harris-Cerruti C et al., 2003. Cu/Zn superoxide dismutase plays important role in immune response. *J Immunol*, 170(6), 2993-3001.

Ohkawa H, Ohishi N, Yagi K, 1979. Assay for lipid peroxides in animal tissues by thiobarbituric acid reaction. *Anal Biochem*, 95(2), 351-358.

Ozogul B, Halici Z, Cadirci E, Karagoz E et al., 2015. Compar-



- tive Study on Effects of Nebulized and Oral Salbutamol on a Cecal Ligation and Puncture-Induced Sepsis Model in Rats. *Drug Res (Stuttg)*, 65(04), 192-198.
- Pandır D, Per S, Doğanyigit Z, Bekdemir FO et al., 2019. All aspects of the toxic effects of lipopolysaccharide on rat liver and the protective effect of vitamin E and sodium selenite. *Turk J Zool*, 43(6), 566-579.
- Park J, Min J-S, Chae U, Lee JY et al., 2017. Anti-inflammatory effect of oleuropein on microglia through regulation of Drp1-dependent mitochondrial fission. *J Neuroimmunol*, 306, 46-52.
- Pourkhodadad S, Alirezaei M, Moghaddasi M, Ahmadvand H et al., 2016. Neuroprotective effects of oleuropein against cognitive dysfunction induced by colchicine in hippocampal CA1 area in rats. *J Physiol Sci*, 66(5), 397-405.
- Qabaha K, AL-Rimawi F, Qasem A, Naser SA, 2018. Oleuropein is responsible for the major anti-inflammatory effects of olive leaf extract. *J Med Food*, 21(3), 302-305.
- Rocha M, Herance R, Rovira S, Hernández-Mijares A et al., 2012. Mitochondrial dysfunction and antioxidant therapy in sepsis. *Infect Disord Drug Targets*, 12(2), 161-178.
- Ryu S-J, Choi H-S, Yoon K-Y, Lee O-H et al., 2015. Oleuropein suppresses LPS-induced inflammatory responses in RAW 264.7 cell and zebrafish. *J Agric Food Chem*, 63(7), 2098-2105.
- Sedlak J, Lindsay RH, 1968. Estimation of total, protein-bound, and nonprotein sulfhydryl groups in tissue with Ellman's reagent. *Anal Biochem*, 25, 192-205.
- Spanos A, Jhanji S, Vivian-Smith A, Harris T et al., 2010. Early microvascular changes in sepsis and severe sepsis. *Shock*, 33(4), 387-391.
- Sun Y, Oberley LW, Li Y, 1988. A simple method for clinical assay of superoxide dismutase. *Clin Chem*, 34(3), 497-500.
- Şahin S, Samli R, Tan ASB, Barba FJ et al., 2017. Solvent-free microwave-assisted extraction of polyphenols from olive tree leaves: Antioxidant and antimicrobial properties. *Molecules*, 22(7), 1056.
- Wang F, Jin Z, Shen K, Weng T et al., 2017. Butyrate pretreatment attenuates heart depression in a mice model of endotoxin-induced sepsis via anti-inflammation and anti-oxidation. *Am J Emerg Med*, 35(3), 402-409.

Author Contributions

Motivation / Concept: Hüseyin Serkan Erol , Mesut Bünyami Halıcı
 Design: Hüseyin Serkan Erol, Mesut Bünyami Halıcı
 Control/Supervision: Mesut Bünyami Halıcı
 Data Collection and / or Processing: Hüseyin Serkan Erol, Tuba Aydın, Serkan Yıldırım, İsmail Can
 Analysis and / or Interpretation: Hüseyin Serkan Erol, Tuba Aydın, Serkan Yıldırım
 Literature Review: Hüseyin Serkan Erol
 Writing the Article: Hüseyin Serkan Erol, Tuba Aydın
 Critical Review: Hüseyin Serkan Erol, Mesut Bünyami Halıcı, Serkan Yıldırım

Ethical Approval

Ataturk University Animal Experiments Local Ethics Committee 30.11.2017, 13/165 Number Ethics Committee Decision

CITE THIS ARTICLE: Erol HS, Aydın T, Yıldırım S, Can I, et al., 2020. The effects of oleuropein on lung and heart injury in cecal ligation and puncture - induced sepsis. *Eurasian J Vet Sci*, 36, 3, 204-213.

