

A Comparative Morphometric Study on the Skull of the Tuj and Morkaraman Sheep

Sami ÖZCAN *  Gürsoy AKSOY * İbrahim KÜRTÜL *
Kadir ASLAN * Zekeriya ÖZÜDOĞRU **

* Department of Anatomy, Faculty of Veterinary Medicine, University of Kafkas, 36100, Kars - TURKEY

** Department of Anatomy, Faculty of Veterinary Medicine, University of Atatürk, 25240, Erzurum - TURKEY

Makale Kodu (Article Code): KVFD-2009-518

Summary

This study was undertaken to reveal morphometric skull features of the Tuj and Morkaraman sheep. The skulls of 10 months old 6 male Tuj and 6 male Morkaraman sheep were used. A number of 38 craniometric measurements were taken from skulls of both species. Craniofacial indices were also calculated. There were no significant differences determined between the heads of these species except the measurement which displayed the width between the two orbita (entorbitale - entorbitale = least breadth between the orbits), $P < 0.05$. The least breadth between the orbits of 66.58 ± 2.263 mm in Tuj sheep and, 70.41 ± 2.538 mm in Morkaraman sheep were obtained.

Keywords: Morphometry, Skull, Tuj and Morkaraman sheep

Tuj ve Morkaraman Koyunlarının Kafatasında Karşılaştırmalı Morfometrik Bir Çalışma

Özet

Bu çalışma, Tuj ve Morkaraman koyunlarının kafatası yapıları arasındaki muhtemel farklılıkları ortaya koymak için yapıldı. 10 aylık yaşta 6 erkek Tuj ve 6 erkek Morkaraman koyunu kullanıldı. Bu amaçla, her iki hayvana ait kafataslarının 38 farklı yerinden craniometric ölçümler alındı ve craniofacial indeksler hesaplandı. Orbita'lar arası en küçük genişlik (entorbitale - entorbitale) dışındaki ölçümlerde iki tür arasında kayda değer bir farklılık elde edilemedi ($P < 0.05$). Orbita'lar arası en küçük genişlik, Tuj koyununda ortalama 66.58 ± 2.263 mm, Morkaraman koyununda ise 70.41 ± 2.538 mm olarak ölçüldü.

Anahtar sözcükler: Morfometri, Kafatası, Tuj ve Morkaraman koyunu

INTRODUCTION

Shape and largeness of the sheep skulls are mainly associated with the bony structures, varying with species and sex. Meat sheep has larger and rough head while milk sheep comprises smaller head with prominent bony lines. Despite changing with sex, head in male is round, and in female longer, possessing wider nose ^{1,2}.

Male Tuj sheep has horn while female has not. It is mainly raised in northeast Anatolia. It is also called Tuchin in Caucasia ^{1,3}. Each sex in Morkaraman sheep may be with or without horn. It is also mostly raised in

northeast Anatolia. Previous macroanatomical studies ^{4,5} on the Tuj sheep have reported some important differences. This study compared the skull features of the Tuj and Morkaraman sheep, particularly underlying similarities and differences.

MATERIAL and METHODS

A total of 12 skulls of Tuj (6 male, 10 months old) and Morkaraman sheep (6 male, 10 months old) were



İletişim (Correspondence)



+90 474 242 68 00/1327



samiozcan2000@hotmail.com

used in this study. Animals were obtained from different butchery stores in Kars and, were reported to be weighing 30-35 kg. The skulls were macerated accordingly ⁶, measurements were taken from 38 different points in accordance with the indicated method ⁷, and indices were calculated using the method defined by Onar et al. ⁸ and Stockard ⁹. Statistical analyses were performed with "t-test" using MINITAB statistical program.

The following measurements by using definitions of measuring points ^{8,9} on the cranium were made: profile length (akrokranium - prosthion), condylobasal length (aboral border of occipital condyles - prosthion), basal length (basion - prosthion), short skull length (basion - premolare), premolare - prosthion, neurocranium length (basion - nasion), viscerocranium length (nasion - prosthion), median frontal length (akrokranium - nasion), akrokranium - bregma, frontal length (bregma - nasion), upper neurocranium length: Akrokranium - supraorbitale, facial length (supraorbitale - prosthion), akrokranium-infraorbitale of one side, greatest length of the lacrimal (most lateral point of the lacrimal - the most oral point of the lacrimo-maxillary suture, greatest length of the nasals (nasion-rhinion), short lateral facial length (entorbitale - prosthion), from the aboral border of one occipital condyle to the infraorbitale of the same side, dental length (postdentale - prosthion), oral palatal length (palatinoorale - prosthion), lateral length of the premaxilla (nasointermaxillare - prosthion), length of the cheektooth row (measured along the alveoli), length of the molar row (measured along the alveoli on the buccal side), length of the premolar row (measured along the alveoli on the buccal side), greatest inner length of the orbit (ectorbitale - entorbitale), greatest inner height of the orbit (measured in the same way as measurement), greatest mastoid breadth (otio - otion), greatest breadth of the occipital condyles, greatest breadth at the bases of the paraoccipital processes, greatest breadth of the foramen magnum, height of the foramen magnum (basion - opisthion), least breadth of parietal: Least breadth between the temporal lines, greatest neurocranium breadth-Greatest breadth of the braincase (euryon - euryon), greatest breadth across the orbit-greatest frontal breadth-greatest breadth of skull (ectorbitale - entorbitale), least breadth between the orbits (entorbitale - entorbitale), facial breadth (breadth across the facial tuberosities), greatest breadth across the nasals, greatest breadth across the premaxillae, greatest palatal breadth (measured across the outer borders of the alveoli).

The craniofacial indices were calculated by using upper measurements.

Craniofacial indices

Facial index: maximum zygomatic width x 100/viscerocranial length

Nasal index: greatest breadth across the nasals x 100/greatest length of the nasals

Neurocranium index: maximum width of the neurocranium x 100/Neurocranium length

Basal index: maximum width of neurocranium x100/basal length

Skull index: maximum zygomatic width x 100/skull length

RESULTS

Craniometric measurements of the skull of Tuj and Morkaraman sheep were obtained. The mean±SD of the investigated features are presented in [Table 1](#).

Table 1. Craniometric measurements of Tuj and Morkaraman sheep

Tablo 1. Tuj ve Morkaraman koyunlarında cranimetric ölçümler

Measurements of the cranium	Morkaman sheep	Tuj sheep
	Mean SD	Mean SD
Profile length	204.49±9.71	198.09±7.69
Condylobasal length	199.82±9.39	193.16±7.42
Basal length	182.37±8.33	175.59±6.60
Short skull length	129.87±5.32	124.60±4.97
Premolare - prosthion	52.50±3.14	51.14±2.03
Neurocranium length	110.82±3.42	107.20±3.69
Viscerocranium length	113.34±7.53	109.34±2.96
Median frontal length	111.51±2.94	109.16±5.14
Akrokranium - bregma	47.80±1.92	48.50±2.51
Frontal length	73.79±4.15	70.06±3.85
Upper neurocranium length	89.66±1.93	88.73±2.79
Facial length	140.37±7.64	136.71±5.96
Akrokranium-infraorbitale of one side	141.60±4.61	138.25±5.83
Greatest length of the lacrimal	39.01±3.04	37.07±1.18
Greatest length of the nasals	70.34±6.77	68.65±3.16
Short lateral facial length	117.39±6.37	112.16±3.77
From the aboral border of one occipital condyle to the infraorbitale of the same side	144.56±18.17	134.81±4.64
Dental length	119.65±4.57	117.00±3.87
Oral palatal length	83.45±3.76	81.40±3.11
Lateral length of the premaxilla	62.20±4.42	58.53±4.36
Length of the cheektooth row (measured along the alveoli)	65.70±1.16	66.17±1.95
Length of the molar row (measured along the alveoli on the buccal side)	36.77±1.43	36.78±1.69
Length of the premolar row (measured along the alveoli on the buccal side)	28.94±1.18	30.68±3.15
Greatest inner length of the orbit	36.17±0.73	36.63±0.86
Greatest inner height of the orbit	33.04±1.30	33.50±0.51
Greatest mastoid breadth	60.49±2.07	60.91±2.98
Greatest breadth of the occipital condyles	44.10±1.62	44.49±2.83
Greatest breadth at the bases of the paraoccipital processes	57.84±2.10	57.22±2.15
Greatest breadth of the foramen magnum	21.76±1.06	20.81±1.79
Height of the foramen magnum	19.41±1.14	17.83±1.54
Least breadth of parietal	36.16±4.75	38.44±1.82
Greatest neurocranium breadth	60.10±1.20	60.11±1.40
Greatest frontal breadth	102.98±2.52	101.66±1.69
Least breadth between the orbits	70.41±2.54	66.58±2.26
Facial breadth	62.04±1.5	60.05±2.4
Greatest breadth across the nasals	26.54±2.24	25.67±2.76
Greatest breadth across the premaxillae	29.36±3.52	29.55±1.75
Greatest palatal breadth	56.31±2.03	56.08±2.19

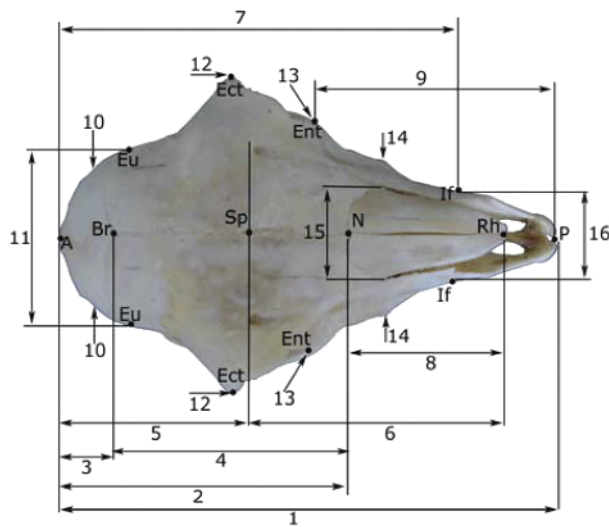


Fig 1. Measurements of the skull of the Tuj and Morkaraman sheep (dorsal view)

Şekil 1. Tuj ve Morkaraman koyununda kafatası ölçümleri (üstten görünüm)

A: Akrokranion, **Br:** Bregma, **Ect:** Ectorbitale, **Ent:** Entorbitale, **Eu:** Euryon, **If:** Infraorbitale, **N:** Nasion, **P:** Prosthion, **Rh:** Rhinion, **Sp:** Supraorbitale

1: profile length, **2:** median frontal length, **3:** akrokranion-bregma, **4:** frontal length, **5:** upper neurocranium length, **6:** facial length, **7:** akrokranion-infraorbitale of one side, **8:** greatest length of nasals, **9:** short lateral facial length, **10:** least breadth of the parietal, **11:** greatest neurocranium breadth, **12:** greatest breadth across the orbits, **13:** least breadth between the orbits, **14:** facial breadth, **15:** greatest breadth across the nasals, **16:** greatest breadth across the premaxillae

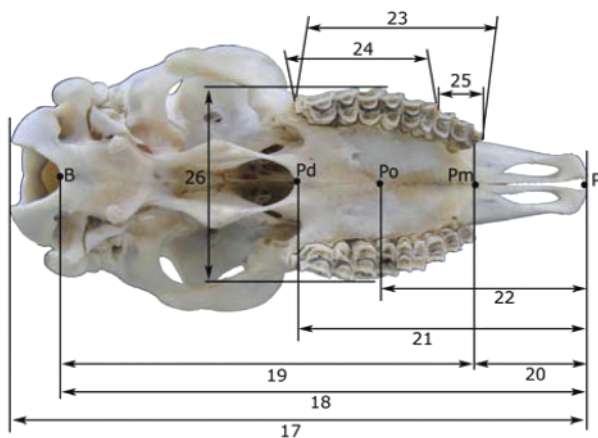


Fig 2. Measurements of the skull of the Tuj and Morkaraman sheep (ventral view)

Şekil 2. Tuj ve Morkaraman koyununda kafatası ölçümleri (alttan görünüm)

B: Basion, **P:** Prosthion, **Pd:** Postdentale, **Pm:** Premolare, **Po:** Palatinoorale
17: condylobasal length, **18:** basal length, **19:** short skull length, **20:** premolare-prosthion, **21:** dental length, **22:** oral palatal length, **23:** length of the cheektooth row (measured along alveoli), **24:** length of the molar row (measured along the alveoli on the buccal side), **25:** length of the premolar row (measured along the alveoli on the buccal side), **26:** greatest palatal breadth

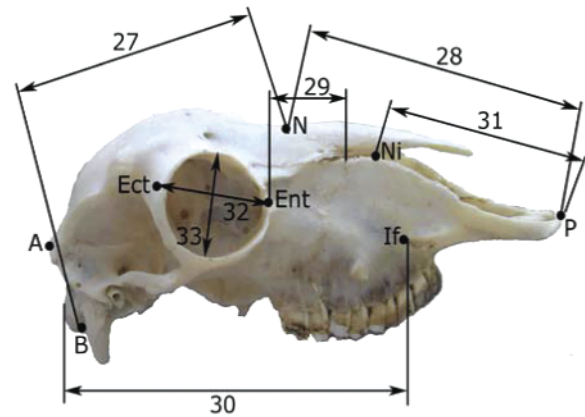


Fig 3. Measurements of the skull of the Tuj and Morkaraman sheep (lateral view)

Şekil 3. Tuj ve Morkaraman koyununda kafatası ölçümleri (yandan görünüm)

A: Akrokranion, **B:** Basion, **Ect:** Ectorbitale, **Ent:** Entorbitale, **If:** Infraorbitale, **N:** Nasion, **Ni:** Nasointermaxillare, **P:** Prosthion

27: neurocranium length, **28:** viscerocranium length, **29:** greatest length of the lacrimal, **30:** from the aboral border of one occipital condyle to the infraorbitale of the same side, **31:** lateral length of the premaxilla, **32:** greatest inner length of the orbit, **33:** greatest inner height of the orbit

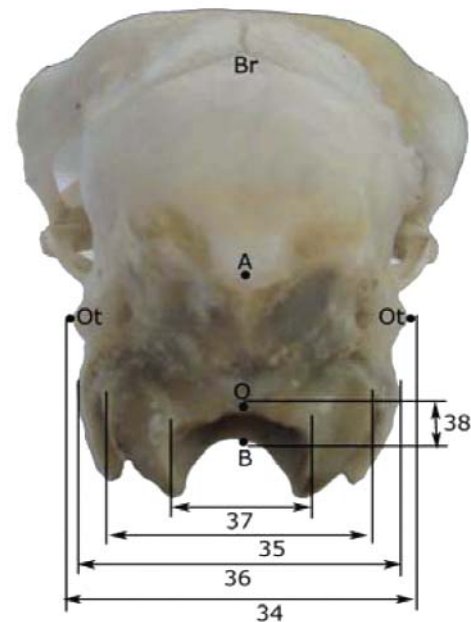


Fig 4. Measurements of the skull of the Tuj and Morkaraman sheep (occipital view)

Şekil 4. Tuj ve Morkaraman koyununda kafatası ölçümleri (okspital görünüm)

A: Akrokranion, **B:** Basion, **Br:** Bregma, **O:** Opisthion, **Ot:** Otion

34: greatest mastoid breadth, **35:** greatest breadth of the occipital condyles, **36:** greatest breadth of the bases of the paraoccipital processes, **37:** greatest breadth of the foramen magnum, **38:** height of the foramen magnum

Table 2. Craniofacial indices of Tuj and Morkaraman sheep**Tablo 2.** Tuj ve Morkaraman koyununda craniofacial indeksler

Craniofacial indices	Morkaman sheep	Tuj sheep
Facial index	93.00±0.68	91.07±1.89
Nasal index	37.43±1.85	37.91±1.64
Neurocranium index	55.12±0.73	53.93±0.79
Basal index	34.26±0.54	33.01±0.72
Skull index	51.36±0.69	50.42±0.78

DISCUSSION

This study, for the first time, has documented the craniometric measurements of the Tuj and Morkaraman sheep. They were showed in results section. Craniofacial indices were determined in both species by using the craniometric measurements.

Onar et al.^{8,10} documented the skull index, basal index - I, and length-width index - 2 in Kangal dogs and in German shepherd dog puppies, respectively. These literatures^{8,10} and Al-Sagair et al.¹¹ in camel and Sarma¹² in Kagani goat skull used the zygomatic length as the widest skull area on measuring index. We used greatest frontal breadth (entorbitale - entorbitale) instead in our study due to morphologic structural differences.

As can be drawn from results section, even though there was no statistically significant difference between the most of the results of the two species compared, numerical differences were of concern, which is probably due to individual variation. The least breadth between the orbits (entorbitale - entorbitale) was significantly higher in Morkaraman sheep, $P < 0.05$. The profile length (akrokranium - prosthion) of the Tuj sheep skull was 198.09 ± 7.690 mm while that in Morkaraman sheep was 204.49 ± 9.710 mm. The greatest frontal breadth was 101.66 ± 1.686 mm in Tuj sheep, and 102.98 ± 2.515 mm in Morkaraman sheep. Least breadth (entorbitale - entorbitale) between the orbits was determined to be 66.58 ± 2.263 mm in Tuj sheep and 70.41 ± 2.538 mm in Morkaraman sheep.

There were no significant differences between the indices of the two species.

Consequently, the results have indicated in our study that both Tuj and Morkaraman sheep comprise a dolichocephalic head in nature, and have determined no significant differences between the skulls of these species except the least breadth between the orbits (entorbitale - entorbitale).

REFERENCES

- Akçapınar H:** Koyun Yetiştiriciliği. 2. baskı, s. 109-115. İsmat Matbaacılık, Ankara, 2000.
- Nickel R, Schummer A, Seiferle E:** Anatomy of the Domestic Animals. Volume 1. 5th ed., pp. 100-161. Verlag Paul Parey, Berlin, 1986.
- Özcan L:** Koyunculuk. s. 100-103, 113-114. Tarım, Orman ve Köyişleri Bakanlığı Yayın Dairesi Başkanlığı, Ankara, 1990.
- Aksoy G, Özmen E, Kürtül İ, Özcan S, Karadağ H:** The venous drainage of the heart in the Tuj sheep. *Kafkas Univ Vet Fak Derg*, 15 (2): 279-286, 2009.
- Özüdoğru Z, Aksoy G:** Tuj koyunun ön bacak venaları üzerine makroanatomik bir çalışma. *Kafkas Univ Vet Fak Derg*, 15 (5): 771-778, 2009.
- Taşbaş M, Tecirlioğlu S:** Maserasyon tekniği üzerinde araştırmalar. *Ankara Üniv Vet Fak Derg*, XII, 4, 324-330, 1996.
- Von Den Driesch A:** A Guide to the measurement of animal bones from archaeological sites. pp. 31-34. Peabody Museum Bulletin I. Cambridge M.A., Harvard University, 1976.
- Onar V, Özcan S, Pazvant G:** Skull typology of adult male Kangal dogs. *Anat Histol Embriol*, 30, 41-48, 2001.
- Stocard CR:** The Genetic and Endocrinic Basis for Differences in Form and Behaviour. No. 19, pp. 1-775. American Anatomical Memoirs, Wistar Institute, Philadelphia, 1941.
- Onar V, Kahvecioğlu O, Çebi V:** Computed tomographic analysis of the cranial cavity and neurocranium in the German shepherd dog (Alsatian) puppies. *Vet Arhiv*, 72 (2): 57-66, 2002.
- Al-Sagair O, Al-Mougy SA:** A comparative morphometric study on the skull of three phenotypes of *Camelus dromedarius*. *J Camel Pract Res*, 9, 73-77, 2002.
- Sarma K:** Morphological and craniometrical studies on the skull of Kagani goat (*Capra hircus*) of Jammu Region. *Int J Morphol*, 24 (3): 449-455, 2006.