


Ossification and Growth of the Bones of the Wings and Legs in Prehatching Period of the Hubbert Strain Broiler

İbrahim KÜRTÜL *  Şükrü Hakan ATALGIN ** Kadir ASLAN *** Emine Ümran BOZKURT ****

* Mustafa Kemal University, Faculty of Veterinary Medicine, Department of Anatomy, Hatay - TÜRKİYE

** Süreyya Astarıcı Vocational School of Higher Education, İzzet Baysal University, Bolu - TÜRKİYE

*** Kafkas University, Faculty of Veterinary Medicine, Department of Anatomy, Kars - TÜRKİYE

**** University of Harran, Faculty of Veterinary Medicine, Department of Anatomy, Şanlıurfa - TÜRKİYE

Makale Kodu (Article Code): KVFD-2009-176

Summary

Recent researches in the field of experimental embryology of avian species are designed to investigate and analyze skeletal mutations, development of cultured embryos under artificial conditions, and to reveal the teratogenic consequences of new drugs. Thus, data on the normal skeletogenous stages of the avian species are essential indicators and indispensable parameters to interpret and elucidate the data acquired on these studies. Accordingly, a number of 10 embryos were prepared every 24 h from 7 to 21 days of incubation, to report the ossification and growth of the bones of the wing and limb in the prehatching period of the Hubbert strain broiler (JV). The embryos fixed in 10% formaldehyde then 95% ethanol solutions were cleared and the skeletons were stained in toto with alcian blue&alizarin red for cartilage and ossified components, respectively. Observation of the skeletons, measurements and photography were performed under a stereoscopic microscopy, paying particular attention to the timing of chondrification and ossification of the bones. The first occurrence of the primary ossification centers was observed on the 9th day of incubation. Different growth patterns were indicated between the long and short bones of the wings and legs. On the 19th days of incubation, occurrence of all the ossification centers completed in all the bones except the radial and ulnar carpal bones, resembling those of the gross structural shapes of the mature stages. At hatching, the radial and ulnar carpal bones were still chondrotic drafts.

Keywords: *Broiler, Limb, Ossification, Wing*

Hubbert Irkı Broylerlerde Kuluçka Döneminde Kanat ve Bacak Kemiklerinin Kemikleşme ve Gelişimleri

Özet

Kanatlı embriyoları ile ilgili son yapılan deneysel araştırmalar, iskelet mutasyonlarını ve laboratuvar şartlarındaki embriyoların gelişimlerini araştırmak ve analiz etmek ve yeni ilaçların teratojenik sonuçlarını ortaya çıkarmak amacıyla dizayn edilmişlerdir. Ayrıca, kanatlıların normal iskelet gelişim aşamaları, bu çalışmalarda elde edilen bulguların yorumlanması ve açıklanmasında önemli göstergeler ve vazgeçilemez parametrelerdir. Bu duruma paralel olarak bu çalışma, Hubbert ırkı broylerlerde kuluçkanın 7.-21. günleri arasında her 24 saatte 10 adet embriyonun kanat ve bacak kemiklerinin kemikleşme ve gelişim süreçlerini ortaya koymak amacıyla tasarlanmıştır. Embriyolar %10 formol ve %95 etanol solusyonlarında tespit edildikten sonra temizlenmiş ve iskeletler in toto olarak Alcian mavisi ve Alizarin kırmızısı ile boyanmıştır. İskeletlerin incelenmesi, ölçümler ve fotoğraflama kıkırdaklaşma ve kemikleşme zamanları dikkate alınarak stereomikroskop altında yapılmıştır. Primer kemikleşme merkezlerinin ilk oluşumu inkubasyonun 9. gününde gözlemlenmiştir. Kanat ve bacaklarda bulunan uzun ve kısa kemiklerinde farklı büyüme modelleri ortaya konmuştur. İnkubasyonun 19. gününde, radial ve ulnar karpal kemikleri haricindeki tüm kemiklerde kemikleşme merkezleri gözlemlenmiş olup, mevcut iskelet şekli erişkin iskeletine benzerlik göstermiştir. Radial ve ulnar karpal kemikler çıkım anında hala kıkırdaksal taslaklar halinde ortaya konmuştur.

Anahtar sözcükler: *Broyler, Bacak, Kemikleşme, Kanat*

INTRODUCTION

Recent researches in the field of experimental embryology of avian species have advanced extraordinarily through focusing specifically on natural skeletal development, teratological testing and

developmental engineering in avian species. For example, some teratological experiments using artificial *in vivo* cultures have been conducted on creating transgenic or chimeric birds from 1-cell or blastoderm



İletişim (Correspondence)



+90 474 242 68 00



kurtul1995@hotmail.com

stage ¹⁻⁵. Furthermore, these researches and tests are designed to investigate and analyze embryonic skeletogenesis ⁶, skeletal mutations ^{7,8} and development of cultured embryos under artificial conditions ⁹, and to reveal the teratogenic consequences of new drugs ^{6,10}.

Usage of an avian embryo as an experimental model in embryological research possesses essential valuable properties such as smaller body size, more and fast prolificness, and precociousness of the material. General experimental embryology that uses avian embryos, and that deals with indicated areas including skeletal mutants, requires a list of natural embryonic developmental stages as the normal control to design the experiments and to analyze the results. Thus, data on the normal skeletogenous stages of the avian species are essential indicators and indispensable parameters to interpret and elucidate the data on the studies of experimental embryology, developmental engineering, and teratological experiments.

There have been lists of researches accumulating on the ossificatory developmental stages of the bones in various avian species including chicken and quail embryos ¹¹⁻¹⁴. They were conducted on staining ossification centers of either partial or whole fetal skeletal components to contribute significant basic knowledge to the experimental embryology studies so that research they do might be more precise and efficient ¹⁴⁻¹⁷. This study, therefore, aimed at reporting the ossification and growth of the bones of the wing and limb in the prehatching period of the Hubbert strain broiler (JV) which has recently acquired a remarkable feed efficiency through gaining extraordinary muscle mass in a very short period of time. With this aspect; the time of appearance of the various centers of ossification was determined, pattern of the related bone growth was established, and the data were compared to the literature. The findings may well contribute to the list of normal skeletogenetic stages in the development of avian species.

MATERIAL and METHODS

Fertilized eggs collected from a local broiler farm unit within 2 h after laying and stored 15°C, were put into an incubator (Brinsea Octagon 250, Sandford, England) within 3 days of laying. The temperature and relative humidity of the incubator were adjusted to 37.5±0.2°C and 71%, respectively. In the research, stages at 24-h intervals were taken to describe the external developmental occurrences of the embryos. A

number of 10 embryos were prepared in the morning to acquire a timing fashion every 24 h from 7 to 21 days of incubation, so a total of 150 embryos were searched within 24 h periods. The external description was evaluated in accordance with the data of Hamburger and Hamilton ¹¹.

The embryos were fixed in 10% formaldehyde for 1 week then in 95% ethanol solutions for 10 days, starting in the morning to acquire a timing fashion. Subsequently, they were cleared and the skeletons were stained in toto with Alcian blue (C.I 74240, Merck, Darmstadt, Germany) and alizarin red (C.I 58005, Merck) for cartilage and ossified components, respectively. The staining technique was modified from the literatures ^{14,17,18}, which dyes the cartilaginous tissue blue and the osseous tissue red. The technique displays the development of the cartilaginous components and localization of the early centers of the ossification areas in the bones.

Observation of the skeletons was performed under a stereoscopic microscopy (Olympus Optical Co. Ltd. Tokyo. No: 20326), paying particular attention to the timing of chondrification and ossification. Each bone was measured on both sides at all periods and photographs were also taken using this equipment. Numerical data were evaluated and analyzed by Minitab 12.1 statistics program (Minitab Inc. 1998) and comparison of the data was performed by "one-way Analysis of Variance" on that P-value was P<0.05 in 95% CI for all the comparison made. Bone nomenclature was based on that described by Nomina Anatomica Avium ¹⁹.

RESULTS

The developmental features of the wing and leg of the 7-21 day embryos were evaluated during the course of incubation. At days of 7 and 8, the main skeletal components of the wings such as the humerus, the radius, the ulna, and the majus and minus metacarpal bones, and the legs including the femur, the tibia, the fibula, and the tarsometatarsus were displayed to have a complete cartilaginous formation even though the digital components were not formed yet.

The first occurrence of the primary ossification centers was observed on the 9th day of incubation. The diaphyseal ossified centers were grossly visible in the humerus, the radius, the ulna, and the majus and minus metacarpal bones. Widths of the ossification

centers in the ulna and radius were nearly equal, and the majus metacarpal bone was thicker than the minus one. The primary ossification centers were also observable in the diaphysis of the bones of the legs at this stage including the femur, the tibia, the fibula, and the tarsometatarsus. The cartilage sketches of the long bones were eminent. That of the fibula was also visible, being of half length of the tibia, with a ¼ thickness ratio. There were three different primary ossification centers determined in the tarsometatarsus, all later fusing completely. There was also no ossification center observed yet in the phalanges of the digits of the wings and legs at this stage.

On the 10th day of incubation, the extension of the ossification observed along the diaphysis of all the long bones, was eminent. There was no new ossification center observed in the long bones at this stage. On the other hand, new ossification centers were seen in the 1st phalanges of the 2nd and 3rd digits of the legs even though cartilage bases of the digits of the wings and legs progressively started to arise.

On the 11th day of incubation (*Figure 1/A; 1/F*), two more ossification centers were observed in the 1st phalanges of the minor and major digits, respectively, in the wings. Moreover, other ossification centers appeared in the 1st phalanges of the 1st, 2nd, 3rd, and 4th digits, 2nd phalanges of the 2nd and 3rd, and 3rd phalanges of the 3rd digits of the legs. The ossified distal extremity of the tibia ended as a pointed component.

On the 12th day of incubation, new ossification center was seen in the 2nd phalanges of the major digits of the wings. The cartilage components of the radial and ulnar carpal bones were apparent at this stage. Thus, all the ossification centers in all the phalanges of the 1st, 2nd, and 3rd digits of the legs were observed. The 4th phalanges of the 4th digits also possessed ossification centers.

There was no new ossification center determined in the bones of the wings on the 13th, 14th, and 15th days of incubation (*Figure 1/B; 1/C; 1/G; 1/H*). All the phalanges of all the digits of the legs were observed already to contain ossification centers by the 15th day of incubation. The articular metatarsal trochlea on the distal edge of the tarsometatarsus was eminent. New ossification center was observed in the 1st phalanges of the alular digits of the wings on the 16th day of the incubation.

By the 17th day of incubation (*Figure 1/D; 1/I*), all

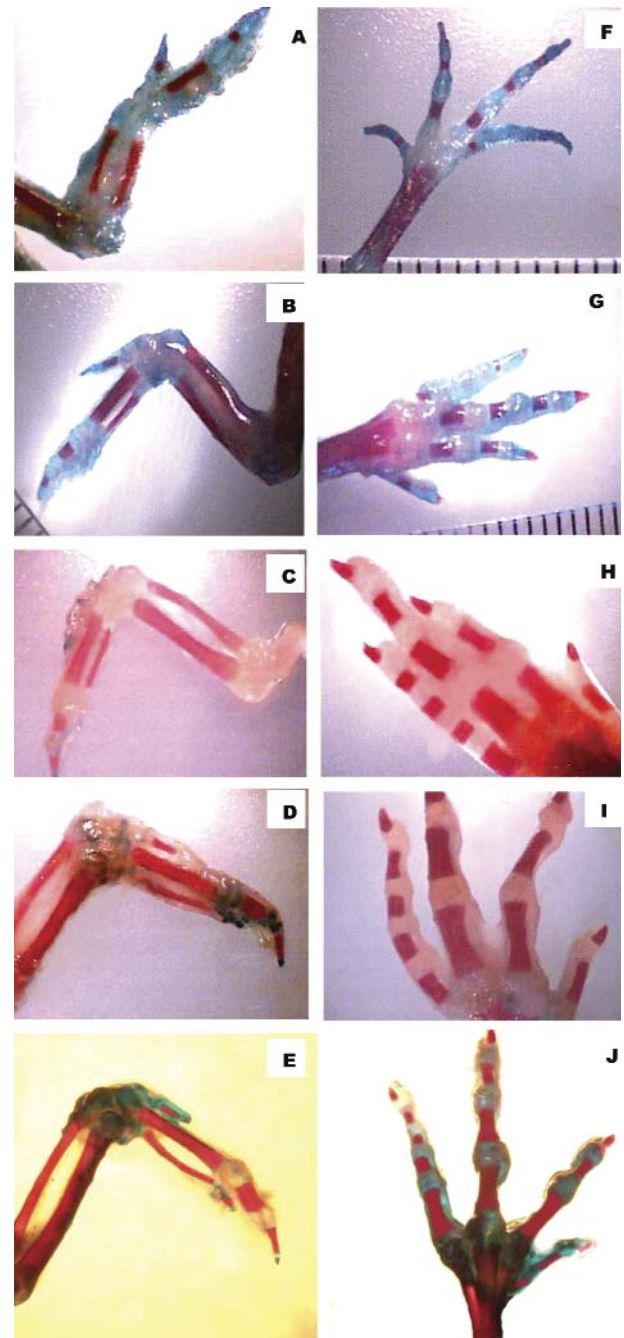


Fig 1. Skeletal features of the wings and legs of the Hubbert strain broiler at various days of incubation. Detail explanations are in the text. (A), (B), (C), (D), (E) representing the wing bones of 11th, 13th, 15th, 17th, and 19th days of incubation. (F), (G), (H), (I), and (J) displaying the leg bones of 11th, 13th, 15th, 17th, and 19th days of incubation. All pictures were taken from dorsal direction and from either right or left extremities

Şekil 1. İnkubasyonun değişik günlerinde Hubbert ırkı broylerlerin kanat ve bacak kemiklerinin iskeletsel özellikleri. Detaylı açıklamalar metindedir. (A), (B), (C), (D) ve (E) inkubasyonun 11., 13., 15., 17. ve 19. günlerindeki kanat kemiklerini göstermektedir. (F), (G), (H), (I) ve (J) inkubasyonun 11., 13., 15., 17. ve 19. günlerindeki bacak kemiklerini göstermektedir. Bütün resimler dorsal bakıdan ve sağ veya sol ekstremitelere alınmıştır

Table 1. The occurrence of the primary ossification centers in the bones of the leg**Tablo 1.** Bacak kemiklerinde primer kemikleşme merkezlerinin oluşumu

Incubation day	femur	tibia	fibula	TMT	1 st digit		2 nd digit			3 rd digit				4 th digit				
					1 st P	2 nd P	1 st P	2 nd P	3 rd P	1 st P	2 nd P	3 rd P	4 th P	1 st P	2 nd P	3 rd P	4 th P	5 th P
7th	-	-	-	-	-	-	-	-	-	-	-	-	-	-	-	-	-	-
8th	-	-	-	-	-	-	-	-	-	-	-	-	-	-	-	-	-	-
9th	+	+	+	+	-	-	-	-	-	-	-	-	-	-	-	-	-	-
10th	+	+	+	+	-	-	-	-	-	+	-	-	-	-	-	-	-	-
11th	+	+	+	+	+	-	+	+	-	+	+	+	-	+	-	-	-	-
12th	+	+	+	+	+	+	+	+	+	+	+	+	+	+	-	-	+	-
13th	+	+	+	+	+	+	+	+	+	+	+	+	+	+	-	-	+	+
14th	+	+	+	+	+	+	+	+	+	+	+	+	+	+	+	+	+	+
15th	+	+	+	+	+	+	+	+	+	+	+	+	+	+	+	+	+	+
16th	+	+	+	+	+	+	+	+	+	+	+	+	+	+	+	+	+	+
17th	+	+	+	+	+	+	+	+	+	+	+	+	+	+	+	+	+	+
18th	+	+	+	+	+	+	+	+	+	+	+	+	+	+	+	+	+	+
19th	+	+	+	+	+	+	+	+	+	+	+	+	+	+	+	+	+	+
20th	+	+	+	+	+	+	+	+	+	+	+	+	+	+	+	+	+	+
21th	+	+	+	+	+	+	+	+	+	+	+	+	+	+	+	+	+	+

+: ossified, -: not ossified, **TMT**: tarsometatarsal bone, **P**: phalanx**Table 2.** The occurrence of the primary ossification centers in the bones of the wing**Tablo 2.** Kanat kemiklerinde primer kemikleşme merkezlerinin oluşumu

Incubation day	humerus	radius	ulna	RCB&UCB	OMC	Major digit		Minor digit	Alular digit	
						1 st	2 nd		1 st	2 nd
7th	-	-	-	-	-	-	-	-	-	-
8th	-	-	-	-	-	-	-	-	-	-
9th	+	+	+	-	+	-	-	-	-	-
10th	+	+	+	-	+	-	-	-	-	-
11th	+	+	+	-	+	+	-	+	-	-
12th	+	+	+	-	+	+	+	+	-	-
13th	+	+	+	-	+	+	+	+	-	-
14th	+	+	+	-	+	+	+	+	-	-
15th	+	+	+	-	+	+	+	+	-	-
16th	+	+	+	-	+	+	+	+	+	-
17th	+	+	+	-	+	+	+	+	+	-
18th	+	+	+	-	+	+	+	+	+	-
19th	+	+	+	-	+	+	+	+	+	+
20th	+	+	+	-	+	+	+	+	+	+
21th	+	+	+	-	+	+	+	+	+	+

+: ossified, -: not ossified, **RCB**: radial carpal bone, **UCB**: ulnar carpal bone, **OMC**: both major and minor metacarpal bones

the ossification centers that occurred in all the bones resembled those of the gross structural shapes of the mature stages. At this stage, occurrence of the ossification centers in all the phalanges of the digits in the wings except the 2nd phalanges of the alular digits and legs completed at this stage. On the 19th day of incubation, ossification centers in the 2nd phalanges of the alular digits finally occurred (*Figure 1/E*). After the 19th day of incubation (*Figure 1/K*), the ossified components of the observed bones continued to develop until the 21st day of incubation when the hatching happened. At the time of hatching, there was

still no ossification center that occurred in the radial and ulnar carpal bones which were still chondrotic drafts.

The data acquired regarding the development of the ossification of the bones of the leg and wing against the embryonic periods were displayed in *Figures 2* and *3*, respectively. There were no statistically significant side and individuality differences among the data of the same period, ($P < 0.05$). The occurrence of the primary ossification centers in the bones of the leg and wing were also shown in *Tables 1* and *2*, respectively.

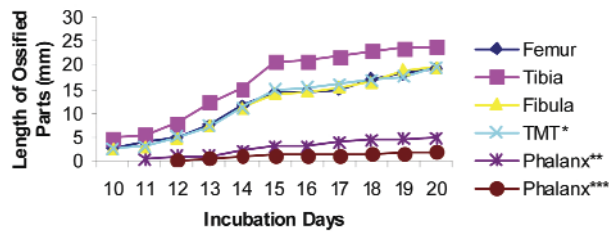


Fig 2. Growth curves of ossified parts of the leg bones

Şekil 2. Bacak kemiklerinin kemikleşmiş kısımlarının gelişim eğrileri

* Medial length of the tarsometatarsal bone

** 2nd digit, 1st phalanx *** 4th digit, 5th phalanx

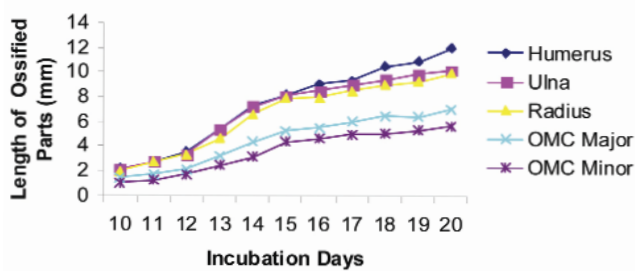


Fig 3. Growth curves of ossified parts of the wing bones.

Şekil 3. Kanat kemiklerinin kemikleşmiş kısımlarının gelişim eğrileri

DISCUSSION

Figures 1-3 and Tables 1 and 2 schematically and photographically display the timing of ossification in the bones forming the wings and legs of the Hubbert strain broiler. Only gross morphological appearance of the ossification in the bones was observed in the study. The growth in length of the ossification of the measured bones was determined to be fundamentally equal bilaterally with time increase. Due to that, very small numerical side variations were disregarded since they had no significant effects on the results. As expected, the first primary ossification centers appeared in the diaphysis of the long bones, which was in parallel with the accumulating data ^{14,20,21}. The time of the appearance of the first primary ossification center was on the 9th day of incubation even though cartilaginous formation commenced earlier. By the 19th day of incubation, all the components of the legs and wings except the radial and ulnar carpal bones showed ossification. From now on, all the bones resembled those of the gross structural shapes of the mature stages. At the time of hatching, there was still no ossification center in the radial and ulnar carpal bones even though chondrotic drafts of were present. This obviates the very late ossification of the 2nd

phalanges of the alular digits just as indicated by the Nomina Antomica Avium ¹⁹ and the postnatal ossification of the radial and ulnar carpal bones in the Hubbert strain broiler.

It has been well known that birds possess different postnatal growth rates, i.e. altricial species show higher postnatal growth rates than precocial birds ²²⁻²⁴. This is directly related to the degree of precocity of the new born chick. Altricial species with higher postnatal growth rates allocate such rates particularly to rapid development of supply organs including the ones in digestive system. The early development of these organs is probably at the expense of growth directed to demand organs such as muscles and skeletal features. Studies have well established in domestic chicken that calcium mobilization and mineralization of the skeletal features begin between the 7th and 8th days of incubation ^{11,24,25}. On the other hand, we found in our study that the first primary ossification center in the bones of the Hubbert strain broiler occurred grossly on the 9th day of incubation. The first gross appearance of the ossification was at least between the 8th and 9th days of incubation, which seemed to be slightly later as compared to the previous data. Consequently, this might led to the speculation that, in the domestic fowl raised as broiler which gains giant muscle mass at a very short period, precocity is probably at the expense of the musculature system rather than the skeletal features. It is very essential to indicate, though, that mineralization in the observed ossification areas may earlier. This can be determined by subgross and histological studies. As mentioned above, this study focused the gross appearance of the ossification only.

Likewise, the growth pattern of the long bones of the wing and leg in Japanese quail was indicated to differ significantly ²¹. It has been highlighted in this report that the long bones of the wing reach their mature length more quickly than those of the leg. On the other hand, the results suggested in our study that the growth rate of the bones of the wing and leg in broiler displayed almost the same pattern. In other words, the growth curve of the bones in the wing and leg followed similar pattern with time increase. These contradictory results in our study, once again, highlighted the fact that growth rates of the organs and tissues in avian species differ greatly due to form and function, as indicated by the literature ^{24,26}.

The growth rate has been reported to differ significantly also among different bones of the same

species^{11,17,24-26}. There is a significant increase during the first few days of the development in the cartilaginous and ossified components of all the bones. The development of the ossification continues throughout the hatching while that of the cartilaginous parts displays a plateau, followed by a steady decrease^{11,17,25}. This study focused only on the changes of the ossification. The ossification rate in the long bones of the wing and leg, at first, seemed to increase by the 15th day of incubation, followed by a steady decrease in the rate, displaying a plateau-like pattern. There was, however, a regular increase in the ossification rate of the short bones in the wing and leg.

Chondrification and calcification start from different regions of the skeletal system^{14,17}. They usually occurred at the midregion and extend to the proximal and edges in the long bones. In the metatarsal and digital bones, calcification begins either at the proximal or at the distal region. Ossification in all the bones observed in this study began at the midregion and progressed to the proximal and distal regions.

REFERENCES

1. **Perry MM:** A complete culture system for the chick embryo. *Nature*, 331, 70-72, 1988.
2. **Etches RJ, Carsience RS, Clark ME, Fraser RA, Toner A, Verrinder Gibbins AM:** Chimeric chickens and their use in manipulation of the chicken genome. *Poult Sci*, 72, 882-889, 1993.
3. **Ono T, Murakami T, Mochii M, Agata K, Kino K, Otsuka K, Ohta M, Mizutani M, Yoshida M, Eguchi G:** A complete culture system for avian transgenesis, supporting quail embryos from the single-cell stage to hatching. *Dev Biol*, 161, 126-130, 1994.
4. **Naito M, Sasaki E, Ohtaki M, Sakurai M:** Introduction of exogenous DNA into somatic and germ cells of chickens by microinjection into the germ disc of fertilized ova. *Mol Rep Dev*, 37, 167-171, 1994.
5. **Ono T, Matsumoto T, Arisawa Y:** Production of donor-derived offspring by transfer of primordial germ cells in Japanese quail. *Exp Anim*, 47, 215-219, 1998.
6. **Hashizume R, Noda A, Itoh M, Yamamoto Y, Masui S, Oka M:** A method for detecting malformations in chicken embryos. *Jap Poult Sci*, 30, 298-305, 1993.
7. **Tsudzuki M, Nakane Y, Wada A:** Hereditary multiple malformation in Japanese quail: A possible powerful animal model for morphogenetic studies. *J Hered*, 89, 24-31, 1998.
8. **Nakane Y, Tsudzuki M:** Morphological and genetic studies for a new morphometric mutant of Japanese quail. *Proceedings, 6th Asian Pacific Poultry Congress*, 242-243, 1998.
9. **Naito M, Nirasawa K, Oishi T:** Development in culture of the chick embryo from fertilized ovum to hatching. *J Exp Zool*, 254, 322-326, 1990.
10. **Hashizume R, Noda A, Itoh M, Yamamoto Y, Masui S, Oka M, Nakamura T:** Studies on teratological testing using chicken embryos: Effects of solvents, injection sites and the age of the embryo. *Exp Anim*, 41, 349-356, 1992.
11. **Hamburger H, Hamilton HL:** A series of normal stages in the development of the chick embryo. *J Morphol*, 88, 49-92, 1951.
12. **Padgett CS, Ivey WD:** The normal embryology of the coturnix quail. *Anat Rec*, 137, 1-11, 1960.
13. **Zacchei AM:** Lo sviluppo embrionale della guaglia giapponese. *Arch Ital Anat Embriol*, 66, 36-62, 1961.
14. **Nakane Y, Tsudzuki M:** Development of the skeleton in Japanese quail embryos. *Dev Growth Differ*, 41, 523-534, 1999.
15. **Hamilton HL:** Lillie's Development of the Chick: An Introduction to Embryology. Holt, Rinehart, Winston, New York. 1952.
16. **Jollie MT:** The head skeleton of the chicken and remarks on the anatomy of this region in other birds. *J Morphol*, 100, 389-436, 1957.
17. **Atalgın H, Kürtül İ:** A morphological study of skeletal development in turkey during the pre-hatching stage. *Anat Histol Embryol*, 38, 23-30, 2009.
18. **Peters PWJ:** Double staining of foetal skeletons for cartilage and bone. In: Neubert D, Merker HJ, Kwasogroch TE (Eds): *Methods in Prenatal Toxicology*. George Thieme, Stuttgart, 1977.
19. **Nomina Anatomica Avium:** Handbook of Avian Anatomy. Published by The Nuttall Ornithological Club. No: 23, Cambridge, Massachusetts, 1993.
20. **Baeriswyl F:** Morphometric development of ossification in the chick leg from the 7th to 17th day of incubation. *Bull Assoc Anat (Nancy)*, 64, 183-198, 1980.
21. **Pourlis AF, Magras IN, Petridis D:** Ossification and growth rates of the limb long bones during the prehatching period in the quail (*Coturnix coturnix japonica*). *Anat Histol Embryol*, 27, 61-63, 1998.
22. **Ricklefs RE, Starck JM, Konarzewski M:** Internal constraints on growth in birds. Avian growth and development. Evolution within the altricial-precocial spectrum. In: Stack JM, Ricklefs RE (Eds): *Oxford University Press, Oxford*, pp. 266-287, 1998.
23. **Lilja C, Blom J, Marks HL:** A comparative study of embryonic development of Japanese quail selected for different patterns of postnatal growth. *Zool*, 104, 115-122, 2001.
24. **Blom J, Lilja C:** A comparative study of embryonic development of some bird species with different patterns of postnatal growth. *Zool*, 108, 81-95, 2005.
25. **Holder N:** The onset of osteogenesis in the developing chick limb. *J Embryol Exp Morphol*, 44, 15-29, 1978.
26. **Blom J, Lilja C:** A comparative study of growth, skeletal development and eggshell composition in some species of birds. *J Zool (London)*, 262, 361-369, 2004.