

The protective effect of caffeic acid phenethyl ester on cadmium-induced liver toxicity: A histopathological and biochemical study

Haci Ahmet DEVECİ^{1,a,✉}, Gökhan NUR^{2,b}, Abdulsamed KÜKÜRT^{3,c}, Mushap KURU^{4,d}, Ayla DEVECİ^{5,e}

¹Gaziantep University, Faculty of Health Sciences, Department of Nutrition and Dietetics, Gaziantep, Türkiye; ²Iskenderun Technical University, Faculty of Engineering and Natural Sciences, Department of Biomedical Engineering, Hatay, Türkiye; ³Kafkas University, Faculty of Veterinary Medicine, Department of Biochemistry, Kars, Türkiye; ⁴Kafkas University, Faculty of Veterinary Medicine, Department of Obstetrics and Gynecology, Kars, Türkiye; ⁵Kilis 7 Aralık University, Vocational School of Technical Sciences, Kilis, Türkiye

^aORCID: 0000-0002-3862-1991; ^bORCID: 0000-0002-5861-8538; ^cORCID: 0000-0002-3603-0506; ^dORCID: 0000-0003-4409-251X

^eORCID: 0000-0003-2574-0251

ARTICLE INFO

Article History

Received : 05.02.2022

Accepted : 03.08.2022

DOI: 10.33988/auvfd.1068527

Keywords

Cadmium

Caffeic acid phenethyl ester

Oxidant-antioxidant balance

Paraoxonase activity

Sialic acid

✉Corresponding author

h_ahmet_deveci@gantep.edu.tr

How to cite this article: Deveci HA, Nur G, Küürt A, Kuru M, Deveci A (2023): The protective effect of caffeic acid phenethyl ester on cadmium-induced liver toxicity: A histopathological and biochemical study. Ankara Univ Vet Fak Derg, 70 (4), 367-374. DOI: 10.33988/auvfd.1068527.

ABSTRACT

In this study, the changes caused by caffeic acid phenethyl ester (CAPE) in the histopathological and biochemical parameters in the oxidant / antioxidant balance in mice with experimental cadmium toxicity were investigated. A total of 40 female Swiss albino mice were used, with 10 mice in each group. The mice were divided into four groups (Group I - Control group, Group II - CAPE group, Group III - Cadmium group, Group IV - Cadmium + CAPE group). Plasma paraoxonase (PON) activity, high-density lipoprotein (HDL), low-density lipoprotein (LDL), total sialic acid (TSA), total antioxidant capacity (TAC), total oxidant capacity (TOC), and oxidative stress index (OSI) were analyzed on mice's blood samples. The results showed that cadmium intoxication triggered oxidative stress in the mice. It also lowered their PON activity alongside TAC and HDL levels ($P<0.001$, $P<0.01$, and $P<0.01$, respectively) and increased their TSA, LDL, TOC, and OSI levels ($P<0.05$, $P<0.01$, $P<0.01$, and $P<0.01$, respectively). The histopathological examination of the liver tissues revealed focal apoptotic regions, sinusoidal occlusion, and irregularity in the cadmium group and no significant change in the other groups. These results indicated that CAPE can significantly prevent biochemical and histopathological changes due to cadmium damage.

Introduction

The world's population has been rapidly growing and this, in turn, has led to environmental and soil pollution. Heavy metals are a leading cause of both environmental and soil pollution (7). Under normal conditions, heavy metals are found at low levels in nature. When their levels increase, they have toxic effects on living beings because they inhibit especially enzymes (54, 58). Cadmium (Cd) is a commonly found heavy metal in the ecosystem and is highly toxic to living organisms. It gets released into the environment through various sources, and then passes into plants, soil, and water – in turn adversely affecting human and animal health. Cadmium-induced toxicity in tissues

and organs causes oxidative stress in the organism (4, 18). Oxidative stress occurs when there is a disruption of the balance between free radicals and the antioxidant system in an organism. Free radicals disrupt the structures of important organic compounds such as protein, DNA, carbohydrate, and lipid, in the cells of living organisms, thus resulting in lipid peroxidation (38, 40).

The paraoxonase (PON) enzyme – an antioxidant against lipid peroxidation in cell membranes – suffers a significant amount of activity loss during lipid peroxidation (55). PON is located in high-density lipoproteins (HDL) in serum and has a calcium-dependent glycoprotein structure (13, 52). It has several functions

such as participating in the detoxification of organophosphate compounds such as paraoxon and protecting low-density lipoproteins (LDL) from oxidation by hydrolyzing lipid peroxides (2, 59). For a long time, lipid peroxidation has been thought to be an important mechanism that plays a role in cadmium toxicity; therefore it is believed that antioxidant agents should be administered to protect and treat the organisms against oxidative stress caused by cadmium (43, 50). This has guided the related studies toward focusing on antioxidant molecules that can both strengthen the antioxidant defense system and prevent heavy metal poisoning. One of the molecules with antioxidant properties is caffeic acid phenethyl ester (CAPE). CAPE is a component of propolis, an extract collected from plants by bees. It has antimicrobial, anti-inflammatory, immunomodulatory, neuroprotective, and antioxidant properties (3, 6, 10, 37). Numerous studies have revealed that CAPE is a pharmacologically reliable molecule and increases the activity of antioxidant enzymes by suppressing lipid peroxidation (15, 21, 48). Sialic acid is a compound derived from neuraminic acid by N-acetylation and is one of the important structures of biological membranes (51, 56).

Natural antioxidants are popular remedies that have few side effects and are used by the majority of people (23). Experimental studies are powerful tools for investigating agents that induce and prevent oxidative damage and its role in carcinogenesis. As far as we know, the effect of CAPE on Cd-induced liver tissue impairment in ovariectomized mice has not yet been reported. This study, it was aimed to reveal the changes induced by CAPE, which is a powerful natural antioxidant, in the antioxidant/oxidant balance of the organism through histopathological and biochemical parameters against an experimental toxicity model created in mice by using cadmium, which is a major heavy metal.

Materials and Methods

Ethics committee approval was obtained from Kafkas University Animal Experiments Local Ethics Committee (2016-087) for this study. In the study, using G*Power (3.1.9.3) software, Type-1 (alpha) error rate = 0.05, power (1-beta) = 0.80, effect size = 0.30. Accordingly, a total of 40 female Swiss albino mice were used, with 10 mice in each group. They were fed with a standard mouse diet and water for 15 days to make them adapt. To make animals ready for the experiments, they were raised in cages at 25 ± 2 °C and an average humidity of 50 ± 5 . They were exposed to 12 hours of light, and 12 hours of darkness.

Lab animals: The mice were divided into four groups, as follows:

Group-I – Control group: 10 mice

Group-II – CAPE group: 10 mice

Group-III – Cadmium group: 10 mice

Group-IV – Cadmium + CAPE group: 10 mice

The ovaries of the mice in all four groups were surgically removed through an ovariectomy procedure. They were then left to heal for 20 days, after which point other experiments were conducted on them. Group-I was fed a normal diet. The mice in this group were given saline intraperitoneally throughout the experiment to eliminate any differences between groups that might arise from stress and to prevent the placebo effect – a possible result of injections. The mice in Group II were fed with a normal diet plus 10 µmol/kg intraperitoneal CAPE for 15 days (10). The mice in Group III were fed with a normal diet, plus 1 mg/kg/day subcutaneous cadmium-chloride for 15 days (32). The mice in Group IV were fed with a normal diet + 1 mg/kg/day subcutaneous cadmium-chloride + 10 µmol/kg intraperitoneal CAPE for 15 days.

Histopathological procedures: One day following the last administration, intracardiac blood samples were extracted from the mice and collected into heparinized tubes. Later, the mice were subjected to cervical dislocation. Tissue samples were taken from their systemic necropsies and fixed in a 10% formol solution. Next, sections were prepared on paraffin blocks following routine procedures. Last, they were stained with Hematoxylin-Eosin and then examined under a light microscope for any histopathological findings.

Biochemical parameters: Plasma was obtained by centrifuging the blood samples at 3000 rpm for 10 minutes and kept at -20 °C until the analysis began. Plasma total antioxidant capacity (TAC) and total oxidant capacity (TOC) levels in the blood samples were measured using a spectrophotometer (Epoch, Biotek, USA) with commercial kits (Rel Assay Diagnostics®, Gaziantep, Türkiye) based on Erel's method(s) (19, 20). Plasma paraoxonase activity was measured using Eckerson (16) and Gülcü's (25) methods. PON activity was determined by spectrophotometric measurement of absorbance at 25°C and 412 nm by color product yielded from 4-nitrophenol occurring as a result of enzymatic hydrolysis of O,O-Diethyl O-(4-nitrophenyl) phosphate (Sigma®, London, UK). For paraoxonase activity, the enzyme activity in 1 mL serum transforming 1 nmol paraoxonase into 4-nitrophenol in 1 min was identified as a unit and the results were given in U/L. Plasma total sialic acid (TSA) levels were measured using Sydow's method (53) in that sialic acid was separated by perchloric acid in the sample, and then it was boiled by Erlich reagent, and finally, the product was read at 525 nm. NANA (N-acetylneuraminic acid from *Escherichia coli*, Sigma®, London, UK) was used for the sialic acid calibration curve. Plasma LDL and HDL levels were measured with an automatic analyzer

(Huma Star 600, Germany) using a commercial kit (IBL®, Türkiye). The oxidative stress index (OSI) was calculated using the following formula: $OSI (AU, \text{arbitrary unit}) = \frac{TOC \times 100}{TAC}$.

Statistical analysis: SPSS (IBM SPSS Statistic 22) was used to analyze the parametric values, and then generate statistics. ANOVA-Duncan test was used to find out whether or not there was a difference between the study groups. Moreover, ANOVA was used to identify whether or not there was any difference caused by a particular group(s). The results were expressed in mean + standard deviation. The difference was deemed as significant at the level of $P < 0.05$.

Results

Biochemical Results: Biochemical analysis revealed the biochemical values of the Control group and the CAPE group were at normal levels, while PON activity, HDL, and TAC levels dropped significantly in the Cadmium group and the Cadmium + CAPE group ($P < 0.001$, $P < 0.01$, $P < 0.01$, respectively). Likewise, the biochemical values of the Control group and the CAPE group were again at normal levels, whereas LDL, TSA, TOC, and OSI levels had increased significantly in the Cadmium group and the Cadmium + CAPE group ($P < 0.01$, $P < 0.05$, $P < 0.01$, $P < 0.01$, respectively). These findings are presented in Figure 1 and Figure 2 (See below).

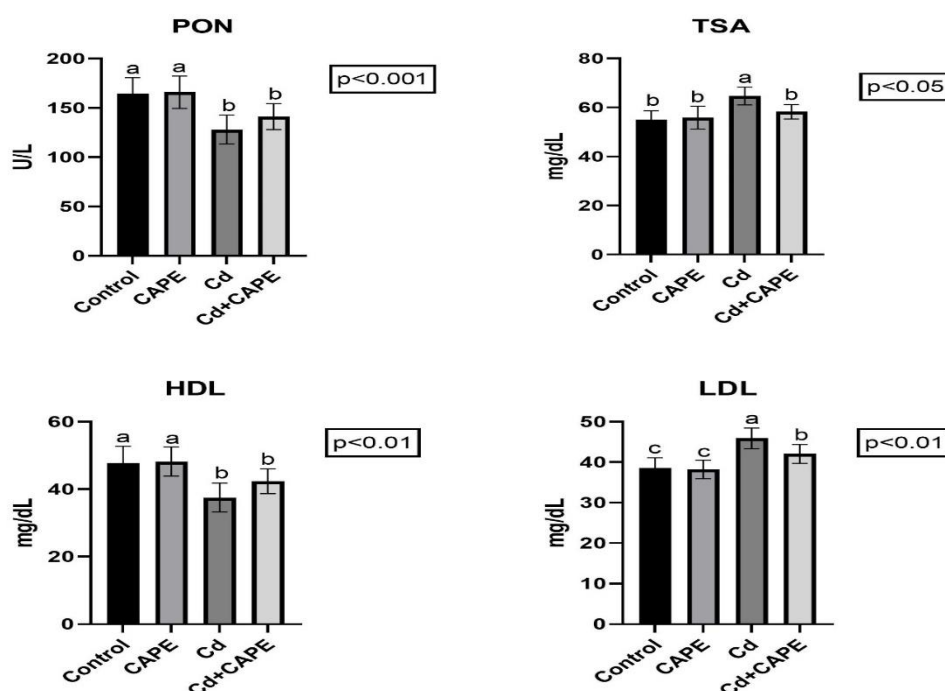


Figure 1. PON, TSA, HDL and LDL values obtained from all four groups.

Control: Control group, CAPE: caffeic acid phenethyl ester group, Cd: cadmium group, Cd + CAPE: cadmium + caffeic acid phenethyl ester group. PON: paraoxonase activity, TSA: total sialic acid, HDL: high-density lipoprotein, LDL: low-density lipoprotein. a, b, c: The difference between the group means shown with different letters in the same row is significant.

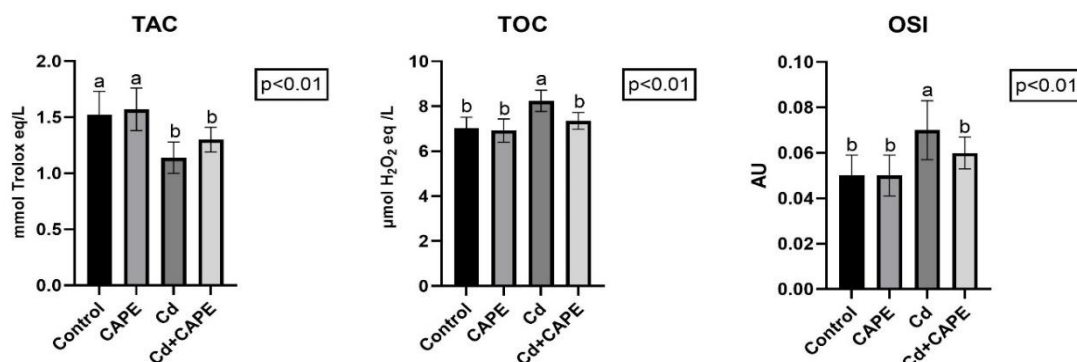


Figure 2. TAC, TOC and OSI values obtained from all four groups.

Control: Control group, CAPE: caffeic acid phenethyl ester group, Cd: cadmium group, Cd + CAPE: cadmium + caffeic acid phenethyl ester group. PON: paraoxonase activity, TAC: total antioxidant capacity, TOC: total oxidant capacity, OSI: oxidative stress index. a, b: The difference between the group means shown with different letters in the same row is significant.

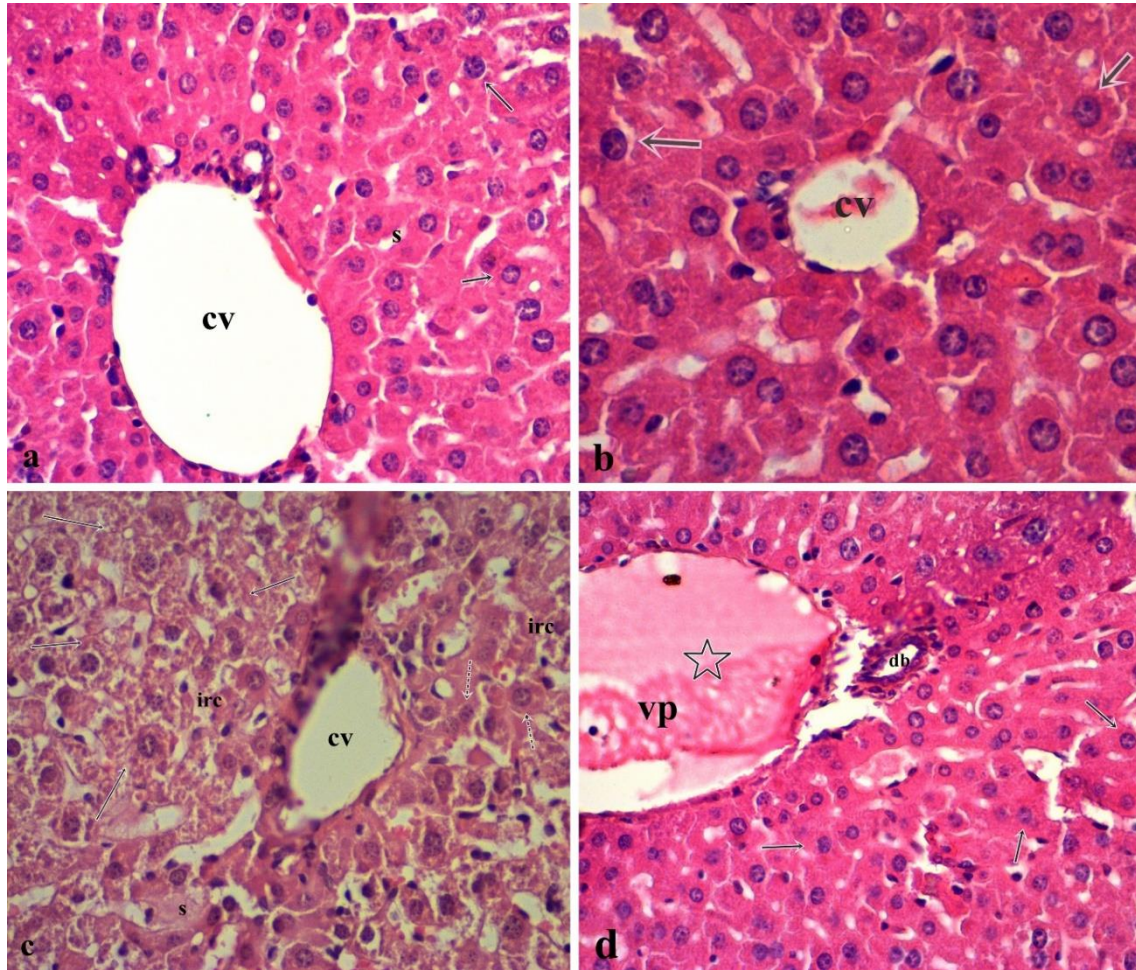


Figure 3. **a.** Liver tissue section view of Group I. Hepatocytes and sinusoidal structure had a normal appearance (cv: vena centralis, s: sinusoid, arrows: hepatocyte). **b.** Liver tissue section view of Group II. Hepatocytes and sinusoidal structure had a normal appearance (cv: vena centralis, s: sinusoid, arrows: hepatocyte). **c.** Liver tissue section view of Group III (arrows: focal apoptotic regions, dashed arrows: hepatocytes, cv: vena centralis, irc: irregular remark cords, s: sinusoidal congestion). **d.** Liver tissue section view of Group IV (star: vascular congestion, db: ductus biliferi, arrows: hepatocytes, vp: portal vena). Bar: 40 μ m, Hematoxylin-Eosin.

Histopathological Results: Histopathological analysis revealed that the vena centralis and portal areas had a normal appearance and the hepatocyte sequence was regular in the Groups I and II. Congestion, focal necrosis, and degenerative areas were detected in the central and portal veins in the sections of Group III. In Group IV, a decrease was observed in both severity and frequency of the histopathological changes compared to Group III (Figure 3 a, b, c, d).

Discussion and Conclusion

Cadmium is easily absorbed by plants and can also get mixed into drinking water from soil thereby entering the food chain. Cadmium thus emerges as critical health and environmental problem. Heavy metals like cadmium pose serious health problems through contaminated water and food (30, 44). Living organisms do not have a mechanism to remove cadmium from their systems. It, therefore, accumulates in tissues and organs, especially the kidney

and liver as well as the pancreas, bones, lung, and placenta. During chronic cadmium intoxications, organisms develop hepatotoxicity and nephrotoxicity (8, 31).

Both antioxidants and oxidants interact with one another in organisms. It is stated that the measurement of antioxidants separately in laboratories has many disadvantages such as time-consuming, intense workload, and costly complex techniques, and therefore TAC measurement can be used as a panel of antioxidant defence (5, 9, 57, 60). To determine the oxidative balance of an organism, it might be more useful to measure only TAC and TOC, rather than evaluating oxidants and antioxidants parameters one by one (19, 20). Some studies have suggested that an increased risk of disease due to cadmium exposure may result from systemic inflammation and induced oxidative stress (12, 41). Many animal model studies involving experimental cadmium toxicity have reported that cadmium causes oxidative stress, that results

in lipid peroxidation in cells and tissues, leading to a reduction in antioxidant enzymes of the organism and a rise in lipid peroxidation products (27, 29, 31, 34, 36, 45). Likewise, the present study revealed that the Cadmium group's plasma TAC levels decreased significantly and their TOC level and OSI increased. In the groups given CAPE, these values were closer to those of the control group. This may be because cadmium accumulation in major organs such as the liver causes oxidative stress in the organism by leading to an increment in free radicals and a reduction in antioxidant molecules.

Paraoxonase is a calcium-bound glycoprotein enzyme found in an organism's serum, liver, kidneys, and intestines. It functions to hydrolyze organophosphates. PON, which is bound to HDL in serum, exerts an antioxidant action through HDL and prevents lipid peroxidation (2, 59). Although the literature review did not reveal a study investigating the relationship between cadmium toxicity and PON activity in mice, many studies such as experimental studies in rats and mice have revealed the effects of various toxicants on PON activity. Also, paraoxonase activity has been associated with cadmium in some studies and inhibitory effects on PON activity have been demonstrated (1, 14, 28, 39). The findings of the present study demonstrated that plasma PON activity and HDL levels were lower and LDL levels were higher in mice treated with cadmium. The plasma PON activity, HDL and LDL levels of the CAPE group and the Cadmium + CAPE group got closer to the control group. The Cadmium group might have had low plasma PON activity and HDL level alongside high LDL level because oxidative stress caused by cadmium intoxication also induces lipid peroxidation; likewise, cadmium inhibits calcium-dependent paraoxonase activity.

Sialic acid is a derivative of N-acetyl neuraminic acid and is found in the structure of macromolecules and receptors. Any factor that causes malfunctions in living organisms also significantly increases total sialic acid levels (15, 51). Several studies have reported that endogenous and exogenous toxic agents may cause oxidative stress in tissues and cells and the release of sialic acid from oligosaccharides on the cell surface may begin with oxidative stress. That, in turn, causes lipid peroxidation and cell damage in cells and tissues (15, 17, 51). Karapehlivan et al. (33) reported that TSA levels in brain, kidney and liver tissue homogenates were higher in mice intoxicated with mercury (a major heavy metal, like cadmium) than those in control group. In the present study, plasma TSA levels in the Cadmium group were higher than those of the control group. It was also found that the plasma TSA levels in the CAPE group were closer to the plasma TSA levels in the control group. It was thought that lipid peroxidation caused by oxidative stress

and subsequent tissue damage may cause a rise in TSA levels in the Cadmium group.

Various studies have stated that CAPE is highly effective in protecting core cytosolic proteins, membrane lipids, and DNA against oxidative damage because of its antioxidant and free radical scavenging properties (21, 46-48). A handful of studies have shown that CAPE is effective in protecting the oxidant / antioxidant balance of the organism, in favor of antioxidants because it prevents oxidative stress in cells caused by cadmium toxicity (11, 35). Cadmium is mainly known to target the liver. However, like other heavy metals, it can also accumulate in an organism's kidneys, lungs, duodenum, pancreas, bones, and testicular tissues, and even cause cytological and histopathological damage. Among the precursor organs, the liver and kidneys filter cadmium from the body (22). When Cadmium enters an organism, it forms a durable bond with metallothionein, a protein that plays an important role in the liver's metabolism. The kidneys excrete that the metallothionein-cadmium complex (62). In the liver, following Cadmium-induced oxidative stress, Kupffer cells activate tumor necrosis factor- α (TNF- α) and interleukin-6 (IL-6) – both are pro-inflammatory mediators- that cause the release of adhesion molecules. This leads to a range of cellular and humoral activities that result in inflammation of hepatocytes and disrupt the cell membrane (61). Regardless of the route of exposure, Cadmium toxicity primarily causes liver necrosis and apoptosis of hepatocytes (26, 42). A study in which 5 mg/kg of cadmium was administered to rats for 28 days reported hydropic degeneration, degeneration around the central vein, infiltration foci, enlargement of sinusoids, and pyknotic nuclei (49). Another study involving 1 mg/kg cadmium reported both hydropic degeneration and infiltration foci in hepatocytes (24). The findings reported in all of the aforementioned studies support histopathological findings of the present study.

Cadmium intoxication triggered oxidative stress in mice by lowering PON activity, TAC, and HDL levels and increasing TSA, LDL, TOC, and OSI levels. Histopathological analysis of all groups revealed that the Cadmium group developed focal apoptotic regions, sinusoidal congestion, and irregularity in the remark cords due to cadmium's toxicity; no significant changes were detected in any of the other three groups. Biochemical and histopathological parameters were found to be similar in the control group and the CAPE group. In conclusion, the findings of the present study showed that cadmium can cause significant changes in biochemical and histopathological parameters, due to oxidative damage. They also demonstrate that CAPE can significantly prevent those changes.

Financial Support

This study was supported by Gaziantep University Scientific Research Projects (Project ID: IMYO.17.01).

Conflict of Interest

The authors declared that there is no conflict of interest.

Author Contributions

HAD, GN, AK and MK conceived and planned the experiments. GN, AD, MK carried out the experiments. HAD and GN planned and carried out the simulations. GN, AK and AD contributed to sample preparation. HAD, GN and AK contributed to the interpretation of the results. HAD took the lead in writing the manuscript. All authors provided critical feedback and helped shape the research, analysis and manuscript.

Data Availability Statement

The data supporting this study's findings are available from the corresponding author upon reasonable request.

Ethical Statement

All procedures performed with experimental animals comply with ethical standards and were approved by the Kafkas University Animal Experiments Local Ethics Committee (2016-087).

Animal Welfare

The authors confirm that they have adhered to ARRIVE Guidelines to protect animals used for scientific purposes.

References

1. Afolabi OK, Oyewo EB, Adekunle AS, et al (2012): Impaired lipid levels and inflammatory response in rats exposed to cadmium. *EXCLI J*, **11**, 677-687.
2. Aviram M, Rosenblat M, Bisgaier CL, et al (1998): Paraoxonase inhibits high-density lipoprotein oxidation and preserves its functions: A possible peroxidative role for paraoxonase. *J Clin Invest*, **101**, 1581-1590.
3. Banskota AH, Tezuka Y, Kadota S (2001): Recent progress in pharmacological research of propolis. *Phyther Res*, **15**, 561-571.
4. Bashir N, Manoharan V, Prabu SM (2014): Cadmium toxicity: oxidative stress and organ dysfunction. *STM Journals*, **4**, 1-19.
5. Benzie IFF, Strain JJ (1996): The ferric reducing ability of plasma (FRAP) as a measure of "antioxidant power": the FRAP assay. *Anal Biochem*, **239**, 70-76.
6. Borrelli F, Maffia P, Pinto L, et al (2002): Phytochemical compounds involved in the anti-inflammatory effect of propolis extract. *Fitoterapia*, **73**, 53-63.
7. Briffa J, Sinagra E, Blundell R (2020): Heavy metal pollution in the environment and their toxicological effects on humans. *Heliyon*, **6**, e04691.
8. Brzóska MM, Kamiński M, Supernak-Bobko D, et al (2003): Changes in the structure and function of the kidney of rats chronically exposed to cadmium. I. Biochemical and histopathological studies. *Arch Toxicol*, **77**, 344-352.
9. Cao G, Prior RL (1998): Comparison of different analytical methods for assessing total antioxidant capacity of human serum. *Clin Chem*, **44**, 1309-1315.
10. Castaldo S, Capasso F (2002): Propolis, an old remedy used in modern medicine. *Fitoterapia*, **73**, 1-6.
11. Chen F, Gong P (2011): Caffeic acid phenethyl ester protect mice hepatic damage against Cadmium exposure. *Proced Environ Sci*, **8**, 633-636.
12. Colacino JA, Arthur AE, Ferguson KK, et al (2014): Dietary antioxidant and anti-inflammatory intake modifies the effect of cadmium exposure on markers of systemic inflammation and oxidative stress. *Environ Res*, **131**, 6-12.
13. Costa LG, Cole TB, Jarvik GP, et al (2003): Functional genomics of the paraoxonase (PON1) polymorphisms: effects on pesticide sensitivity, cardiovascular disease, and drug metabolism. *Annu Rev Med*, **54**, 371-392.
14. Debord J, Bollinger JC, Merle L, et al (2003): Inhibition of human serum arylesterase by metal chlorides. *J Inorg Biochem*, **94**, 1-4.
15. Deveci HA, Karapehlivan M (2018): Chlorpyrifos-induced parkinsonian model in mice: Behavior, histopathology and biochemistry. *Pestic Biochem Physiol*, **144**, 36-41.
16. Eckerson HW, Romson J, Wyte C, et al (1983): The human serum paraoxonase polymorphism: Identification of phenotypes by their response to salis. *Am J Hum Genet*, **35**, 214-227.
17. Eguchi H, Ikeda Y, Ookawara T, et al (2005): Modification of oligosaccharides by reactive oxygen species decreases sialyl lewis x-mediated cell adhesion. *Glycobiology*, **15**, 1094-1101.
18. El-Sokkary GH, Nafady AA, Shabash EH (2010): Melatonin administration ameliorates cadmium-induced oxidative stress and morphological changes in the liver of rat. *Ecotoxicol Environ Saf*, **73**, 456-463.
19. Erel O (2004): A novel automated direct measurement method for total antioxidant capacity using a new generation, more stable ABTS radical cation. *Clin Biochem*, **37**, 277-285.
20. Erel O (2005): A new automated colorimetric method for measuring total oxidant status. *Clin Biochem*, **38**, 1103-1111.
21. Fadillioglu E, Erdogan H, Iraz M, et al (2003): Effects of caffeic acid phenethyl ester against doxorubicin-induced neuronal oxidant injury. *Neurosci Res Commun*, **33**, 132-138.
22. Gavett SH, Oberdörster G (1994): Cadmium chloride and cadmium metallothionein-induced pulmonary injury and recruitment of polymorphonuclear leukocytes. *Exp Lung Res*, **20**, 517-537.
23. Gelen V, Kükürt A, Şengül E, et al (2021): Can Polyphenols be Used as Anti-Inflammatory Agents against Covid-19 (SARS-CoV-2)-Induced Inflammation? 341-361. In: FA Badria (Ed), Phenolic Compounds - Chemistry, Synthesis, Diversity, Non-Conventional Industrial, Pharmaceutical and Therapeutic Applications. IntechOpen, London.

24. Gong P, Chen FX, Ma GF, et al (2008): *Endomorphin I effectively protects cadmium chloride-induced hepatic damage in mice*. Toxicology, **251**, 35-44.
25. Gülcü F, Gürsu MF (2003): *The Standardization of paraoxonase and arylesterase activity measurements*. Turkish J Biochem, **28**, 45-49.
26. Güven A, Güven A, Kaya I (2009): *Farelerde kadmiyum ve karbon tetraklorür ile oluşturulan oksidatif hasara kefirin etkisinin belirlenmesi*. Kafkas Üniv Fen Bil Enst Derg, **2**, 25-30.
27. Güven A, Nur G, Deveci HA (2021): *Biochemical and histopathological profile of the liver in chemical poisoning*. 123-149. In: A Güven (Ed), *Oxidative Stress and Antioxidant Defense System*. Livre de Lyon, Lyon.
28. Hussein O, Zidan J, Abu Jabal K, et al (2012): *Paraoxonase activity and expression is modulated by therapeutics in experimental rat nonalcoholic fatty liver disease*. Int J Hepatol, **2012**, 265305.
29. Işık Bircan C, Merhan O (2020): *Kadmiyum uygulanan farelerde oluşturulan oksidatif strese karşı resveratrolün koruyucu etkisinin araştırılması*. Erciyes Üniv Vet Fak Derg, **17**, 215-220.
30. Järup L, Berglund M, Elinder CG, et al (1998): *Health effects of cadmium exposure - A review of the literature and a risk estimate*. Scand J Work Environ Heal, **24**, 1-51.
31. Jurczuk M, Brzóska MM, Moniuszko-Jakoniuk J, et al (2004): *Antioxidant enzymes activity and lipid peroxidation in liver and kidney of rats exposed to cadmium and ethanol*. Food Chem Toxicol, **42**, 429-438.
32. Kara H, Karataş F, Canatan H (2005): *Effect of single dose cadmium chloride administration on oxidative stress in male and female rats*. Turkish J Vet Anim Sci, **29**, 37-42.
33. Karapehlivan M, Ogun M, Kaya I, et al (2014): *Protective effect of omega-3 fatty acid against mercury chloride intoxication in mice*. J Trace Elem Med Biol, **28**, 94-99.
34. Karoui-Kharrat D, Kaddour H, Hamdi Y, et al (2017): *Response of antioxidant enzymes to cadmium-induced cytotoxicity in rat cerebellar granule neurons*. Open Life Sci, **12**, 113-119.
35. Kobroob A, Chattipakorn N, Wongmekiat O (2012): *Caffeic acid phenethyl ester ameliorates cadmium-induced kidney mitochondrial injury*. Chem Biol Interact, **200**, 21-27.
36. Kocamaz D, Merhan O (2019): *Kadmiyum uygulanan farelerde gelişen akciğer hasarına karşı resveratrolün etkisi*. 122-127. In: Proceedings book of International Conference on Mathematics – Engineering - Natural and Medical Sciences, Adana, Turkey.
37. Kükürt A (2020): *Doğal bir antioksidan olarak propolis tedavisinin koruyucu etkileri*. 501-515. In: C Evereklioglu (Ed), *Sağlık Bilimlerinde Teori ve Araştırmalar II*. Gece Kitaplığı, Ankara.
38. Kükürt A, Gelen V, Başer ÖF, et al (2021): *Thiols: Role in oxidative stress-related disorders*. 27-47. In: P Atukeren (Ed), *Accenting Lipid Peroxidation*. IntechOpen, London.
39. Kükürt A, Karapehlivan M (2022): *Protective effect of astaxanthin on experimental ovarian damage in rats*. J Biochem Mol Toxicol, **36**, e22966.
40. Kükürt A, Kuru M, Karapehlivan M (2020): *Nitrik oksit, nitrik oksit sentaz ve dişi üreme distemindeki rolleri*. 113-123. In: C Evereklioglu (Ed), *Sağlık Bilimleri Alanında Akademik Çalışmalar II*. Gece Kitaplığı, Ankara.
41. Lee DH, Lim JS, Song K, et al (2006). *Graded associations of blood lead and urinary cadmium concentrations with oxidative-stress-related markers in the US population: Results from the Third National Health and Nutrition Examination Survey*. Environ Health Perspect, **114**, 350-354.
42. Liju VB, Jeena K, Kuttan R (2013): *Acute and subchronic toxicity as well as mutagenic evaluation of essential oil from turmeric (Curcuma longa L)*. Food Chem Toxicol, **53**, 52-61.
43. López E, Arce C, Oset-Gasque MJ, et al (2006): *Cadmium induces reactive oxygen species generation and lipid peroxidation in cortical neurons in culture*. Free Radic Biol Med, **40**, 940-951.
44. McDowell LR (2003): *Minerals in Animal and Human Nutrition*. Second Edition, Elsevier.
45. Merhan O, Kocamaz D (2018): *Farelerde kadmiyumla indüklenen oksidatif testis hasarına karşı resveratrolün koruyucu etkisi*. 26-36. In: Proceedings book of 2nd International Congress on Multidisciplinary Studies. Adana, Turkey.
46. Nur G, Deveci H, Ersan Y, et al (2016): *Protective role of caffeic acid phenethyl ester against tetramethrine-induced toxicity in mice*. Medicine Science, **5**, 972-978.
47. Nur G, Güven A, Kılıç PA (2018): *The effects of CAPE on oxidative stress and histopathological values in rats treated with subacute dichlorvos*. J Cell Neurosci and Oxid Stress, **10**, 647-655.
48. Oktem F, Ozguner F, Sulak O, et al (2005): *Lithium-induced renal toxicity in rats: Protection by a novel antioxidant caffeic acid phenethyl ester*. Mol Cell Biochem, **277**, 109-115.
49. Renugadevi J, Prabu SM (2010): *Cadmium-induced hepatotoxicity in rats and the protective effect of naringenin*. Exp Toxicol Pathol, **62**, 171-181.
50. Santos FW, Zeni G, Rocha JBT, et al (2005): *Diphenyl diselenide reverses cadmium-induced oxidative damage on mice tissues*. Chem Biol Interact, **151**, 159-165.
51. Schauer R (1982): *Chemistry, metabolism, and biological functions of sialic acids*. Adv Carbohydr Chem Biochem, **40**, 131-234.
52. Sorenson RC, Bisgaier CL, Aviram M, et al (1999): *Human serum paraoxonase/arylesterase's retained hydrophobic N-terminal leader sequence associates with HDLs by binding phospholipids: Apolipoprotein A-I stabilizes activity*. Arterioscler Thromb Vasc Biol, **19**, 2214-2225.
53. Sydow G (1985): *A simplified quick method for determination of sialic acid in serum*. Biomed Biochim Acta, **44**, 1721-1723.
54. Tchounwou PB, Yedjou CG, Patlolla AK, et al (2012). *Heavy metal toxicity and the environment*. Exp Suppl, **101**, 133-164.
55. Van Lenten BJ, Hama SY, De Beer FC, et al (1995): *Anti-inflammatory HDL becomes pro-inflammatory during the acute phase response. Loss of protective effect of HDL against LDL oxidation in aortic wall cell cocultures*. J Clin Invest, **96**, 2758-2767.
56. Varki NM, Varki A (2007): *Diversity in cell surface sialic acid presentations: implications for biology and disease*. Lab Invest, **87**, 851-857.

57. Vlachos GD, Bartzeliotou A, Schulpis KH, et al (2006): *Maternal-neonatal serum paraoxonase 1 activity in relation to the mode of delivery*. Clin Biochem, **39**, 923-928.
58. Waalkes MP (2000): *Cadmium carcinogenesis in review*. J Inorg Biochem, **79**, 241-244.
59. Watson AD, Berliner JA, Hama SY, et al (1995): *Protective effect of high density lipoprotein associated paraoxonase. Inhibition of the biological activity of minimally oxidized low density lipoprotein*. J Clin Invest, **96**, 2882-2891.
60. Wijnberger LD, Krediet TG, Visser GH, et al (2003): *Early neonatal antioxidant capacity after preexisting impaired placental function*. Early Hum Dev, **71**, 111-116.
61. Yamano T, DeCicco LA, Rikans LE (2000): *Attenuation of cadmium-induced liver injury in senescent male Fischer 344 rats: Role of kupffer cells and inflammatory cytokines*. Toxicol Appl Pharmacol, **162**, 68-75.
62. Yang H, Shu Y (2015): *Cadmium transporters in the kidney and cadmium-induced nephrotoxicity*. Int J Mol Sci, **16**, 1484-1494.

Publisher's Note

All claims expressed in this article are solely those of the authors and do not necessarily represent those of their affiliated organizations, or those of the publisher, the editors and the reviewers. Any product that may be evaluated in this article, or claim that may be made by its manufacturer, is not guaranteed or endorsed by the publisher.
