


Clinical Effectiveness of Ivermectin on Bovine Dermatophytosis

Ali Haydar KIRMIZIGÜL * 
Şemistan KIZILTEPE *

Erhan GÖKÇE *
Fatih BÜYÜK **

Mitat ŞAHİN **
Ekin Emre ERKILIÇ *

* Kafkas University, Faculty of Veterinary Medicine, Department of Internal Medicine, TR-36100 Kars - TURKEY

** Kafkas University, Faculty of Veterinary Medicine, Department of Microbiology, TR-36100 Kars - TURKEY

Makale Kodu (Article Code): KVFD-2012-6197

Summary

In the present study, clinical effectiveness of ivermectin on bovine dermatophytosis was evaluated. The material of the study consisted of 30 cattle, 20 experimental (Group I) and 10 control (Group II) animals aged between 3-14 months, diagnosed as dermatophytosis following clinical examination and microbiology. Clinical status of cases were scored on localization, size and number of lesions and condition of the cases were as follows mild (+), moderate (++) and severe (+++). During the study period, farm management practices of the animals were not changed. A single long acting injection of ivermectin at a dose of 0.2 mg/kg was subcutaneously administered to the animals in Group I. Animals in Group II served as a control and received no treatment. Following medical treatment and 45 days of observation period, recovery was recorded 18 animals from Group I (90%). No recovery was observed in the Group II. This study indicated that, ivermectin which is widely used as antiparasiter medicine, activate the immune system. For this reason, in the present study, first time, ivermectin was used in the treatment of dermatophytosis in ruminants with a 90% of recovery rate. These findings show that ivermectin can be used succesfully in the treatment of dermatophytosis infection in cattle.

Keywords: Cattle, Dermatophytosis, Ivermectin

Dermatofitozisli Sığırlarda İvermektinin Klinik Etkinliği

Özet

Bu çalışma, dermatofitozisli sığırlarda ivermektinin klinik etkinliğini araştırma amacıyla yapıldı. Çalışmanın materyalini, klinik ve mikrobiyolojik olarak dermatofitozis tanısı konulan, 3-14 aylık, 20 deneme (Grup I), 10 kontrol (Grup II) olmak üzere toplam 30 genç sığır oluşturdu. Hayvanların klinik durumları; lezyonların lokalizasyonu, büyüklüğü, sayıları ve kondisyonlarına göre, hafif (+), orta (++) ve şiddetli (+++) olarak skorlandırıldı. Çalışma süresince deneme ve kontrol grubundaki hayvanların bakım, besleme ve barınak koşullarında herhangi bir değişiklik yapılmadı. Grup I'deki hayvanlara 0.2 mg/kg dozunda deri altı yolla bir kez uzun etkili ivermektin uygulandı. Grup II'deki hayvanlara ise herhangi bir tedavi uygulanmayarak kontrol olarak tutuldu. Tedaviyi takiben hayvanlar 45 gün gözlemlendi. Grup II'deki hayvanlarda herhangi bir iyileşme görülmezken, grup I'deki 18 hayvanın (%90) iyileştiği gözlemlendi. Bu çalışma ile yaygın olarak antiparaziter amaçla kullanılan ve aynı zamanda immun sistemi aktive ettiği bilinen ivermektin ilk kez ruminantlarda dermatofitozisin tedavisinde kullanılmış ve tedavide %90 oranında başarı elde edilmiştir. Bu sonuçlarla ivermektinin sığır dermatofitozisinin tedavisinde klinik olarak oldukça etkili olduğu kanısına varıldı.

Anahtar sözcükler: Sığır, Dermatofitozis, İvermektin

INTRODUCTION

Dermatophytosis, or ringworm, is a zoonotic infection of the superficial, keratinized structures of the skin and hair of animals and humans ¹. The disease is caused by a group of keratinophilic, filamentous fungi, called dermatophytes, belonging to the genera *Trichophyton*, *Microsporum*, and *Epidermophyton* ^{2,3} *Trichophyton verrucosum*, *T. mentagrophytes* and *T. megninii* have been regarded as the

main fungi causing ringworm in cattle ⁴. But, *T. verrucosum* is the most common agent causing mycosis in cattle ⁵⁻⁸.

The disease occurs throughout the year with a higher prevalence during winter housing period due to high humidity, which facilitate the growth of spores and increases the susceptibility of animals to infection ⁹. Many



İletişim (Correspondence)



+90 474 2426836/5246



ahkirmizigul@hotmail.com

conventional drugs and vaccines have been used in the treatment and prevention of the disease ^{6,10-14}. Ivermectin is used commonly in cattle for the treatment of parasitism ¹⁵. In general, beneficial effects of ivermectin mediated by the immune system have been observed in *Psoroptes cuniculi* ¹⁶, *Dipetalonema viteae* ¹⁷, *Strongylus vulgaris* ¹⁸ and human onchocerciasis infestation ¹⁹. It was also reported that the infiltrating macrophages contained increased amounts of the enzymes lysozyme, a-1-antichymotrypsin and a-1-antitrypsin ¹⁹. Blakley and Rousseaux ²⁰ disclosed that anti-body production and T lymphocytes and macrophages dependent response were enhanced after ivermectin treatment in mice. Therefore the immunomodulating effects of ivermectin may provide an alternative approach for treatment of conditions involving immunosuppression. It has also been reported that specific antibody activity is increased after ivermectin treatment ^{16,17}.

Besides, in the clinical studies of bovines and a study of a horse in the treatment of a viral disease called cutaneous papillomatosis, ivermectin was used for its immunostimulant speciality and the successful results in the treatment had been acquired ²¹⁻²³.

However, our literature search revealed that no study concerning the use of ivermectin for the treatment of bovine dermatophytosis was previously performed. Therefore, the aim of this study was to investigate of the efficacy of ivermectin for the treatment of dermatophytosis in cattle.

MATERIAL and METHODS

Animals and Treatment

This study involved 30 (10 male, 20 female) young cattle aged between 3-14 months from different herds from Kars city and surrounding villages. Farm management practices were similar in all farms. All cases had clinical signs of ringworm. Animals were divided into two groups with regard to treatment regimen. A single long acting injection of ivermectin (Bovifort LA, Eczacibasi, Turkey), at a dose of 0.2 mg/kg was subcutaneously administered to the animals in Group I ($n = 20$). Animals were observed at 15-day intervals for 45 days. Animals in Group II ($n = 10$) served as a control and received no treatment.

Clinical Examination

A complete clinical examination including skin of all affected animals was performed. Clinical status of cases were scored on localization, size and number of lesions and condition of the cases and were as follows; mild (+), moderate (++) and severe (+++). According to this: animals with normal clinical condition and 2-4 lesions with sizes of 1-2 cm in diameter present in the head, neck and other parts of the body graded as mild (+); animals with mild weight loss and 4-8 lesions with sizes of 2-4 cm in diameter present in the head, neck and other parts of the body

graded as moderate (++); animals with prominent weight loss and more than 8 lesions with sizes of 4-6 cm in diameter present in the head, neck and other parts of the body graded as severe (+++). During the study period, farm management practices of the animals were not changed. To attain uniformity between the group I and group II according to the clinical condition, the group I consisted of 20 cattle; 7 cattle in mild, 7 in moderate and 6 in severe group. Group II was composed of 10 cattle of which 4 cattle was in mild, 3 in moderate and 3 in severe group.

Sampling and Mycological Analysis

The surface of the affected area was first rubbed with a cotton swab impregnated with 70% ethyl alcohol to remove surface adhering organisms. Skin scales were collected by scraping of the margin of the lesion using a sterile scalpel blade into sterile petri dish. Hairs were collected by removing dull broken hairs from the margin of the lesion using sterile tweezers as described ²⁴. Each sample collected was divided into two portions. One portion was used for direct microscopic examination with 10% potassium hydroxide. The second portion was cultured on Sabouraud Dextrose Agar. The cultures were incubated at 37°C for 2-6 weeks and inspected for colony formation daily. The macroscopical examination including time of appearance of the growth, colony morphology, color, shape, size and colony reverse side morphology, and microscopical examinations were performed to identify the pathogenic fungi ^{6,25,26}.

RESULTS

Clinical Signs

The skin of affected calves showed circular, circumscribed, grayish-white, crusty raised lesions (*Fig. 1A1*). Focal pityriasis and alopecia were observed. The lesions were most commonly found on the head, neck, dewlap, chest back and dorsal side. These lesions were observed only on the head of 15 animals (50%), head and neck of 9 (33.3%) and other areas of the body of 5 animals (16%).

Following medical treatment and 45 days of observation period, recovery was recorded 18 animals from Group I (90%) (*Fig. 1A2*). No recovery was observed in the Group II throughout the study period.

Culture

Prior to treatment, all of the animals in both groups were positive for *Trichophyton verrucosum* ringworm infestation. *T. verrucosum* was isolated from all cases (100%) before the induction of treatment.

DISCUSSION

Ringworm is a common skin disease of calves. The disease affects calves throughout the year with a higher incidence

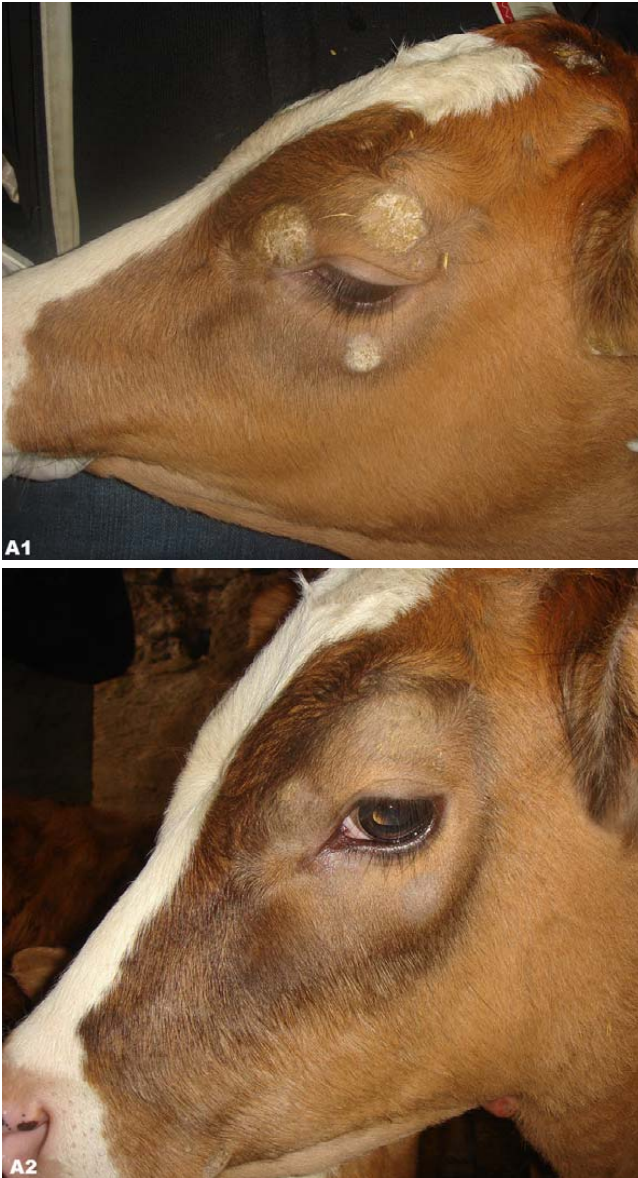

Fig 1. Calves with dermatophytosis in Group I, (A1) before treatment with ivermectin, (A2) recovery after treatment

Şekil 1. (A1) İvermektin ile tedavi edilmeden önce Grup I'deki buzağı resmi, (A2) tedavi sonrası iyileşme

during the winter season because of elevated humidity, which accelerates the growth of spores and makes calves more susceptible to infection ⁹. Animal susceptibility is determined largely by immunological status so those young animals are most susceptible ²⁷.

Furthermore, our clinical observations at the veterinary faculty revealed that ringworm is rather common infection in Kars region possibly due to the long winter period and inappropriate barn conditions including inadequate ventilation and humidity. However, the lack of literature and detailed study for the prevalence of dermatophytosis limits further postulations for the potential reasons of the high morbidity of this infection in the region.

Although, it is a superficial skin infection, ringworm in

cattle may have a significant impact on management and economics in affected herds. Once the disease is introduced into a herd, it spreads easily from one animal to another. Spores may survive in the environment for 2 to 3 years, and calves or purchased animals introduced into the herd are likely to come into contact with infection. The inflammation of the skin is associated with unthriftiness and general discomfort in affected animals. In addition, secondary bacterial infections may occur ². The typical lesion is a heavy, gray-white crust raised perceptibly above the skin. The lesions are circular and about 3 cm in diameter. These circular lesions are most frequently on the head and neck, especially around the eyes and face, but may in severe cases be found over the entire body ^{6,7,10,28,29}. As similar lesions were observed in this study.

The observation of the clinical signs on animals younger than 14 months supports the suggestions that young animals are sensitive to the disease ^{10,28}. In this study, the isolation of *T. verrucosum* from all infected animals also showed that the causative agent of ringworm is usually *T. verrucosum* as previously reported ^{1,6,7,10,28,30}.

The cellular branch of the immune system is crucial for protective immunity against dermatophyte infections ^{31,32}. The rise of protective immunity against this disease was found after natural or experimental infection ³³. It is obvious that the cell-mediated part of the immune response must be stimulated in order to acquire sufficient immunity against ringworm ². A study in calves indicated that a combination of cell-mediated and humoral responses is required for immunity and clearance of *T. verrucosum* infection ³⁴. Fungal elements in infected areas did not decrease until after both humoral and cellular responses had been established ². This may explain a proportionally comparable effect of ivermectin in this study, as ivermectin has already been reported to stimulate both cellular and humoral immunity.

In conclusion, this study indicated that ivermectin which is widely used as antiparasiter medicine, activate the immune system. For this reason, in the present study, for the first time, ivermectin was used in the treatment of dermatophytosis in ruminants with a 90% of recovery rate. These findings indicate that ivermectin can also be successfully utilised in the treatment of dermatophytosis infections occurring in cattle. We believe that our findings will contribute significantly to future studies conducted in this area.

REFERENCES

1. **Weber A:** Mycozoonoses with special regard to ringworm of cattle. *Mycoses*, 43, 20-22, 2000.
2. **Gudding R, Lund A:** Immunoprophylaxis of bovine dermatophytosis. *Can Vet J*, 36, 302-306, 1995.
3. **Randentz WH:** Fungal skin infections associated with animal contact. *Am Fam Physician*, 43, 1253-1256, 1991.
4. **Quinn PJ, Carter ME, Markey B, Carter GR:** Clinical Veterinary

Microbiology, 1st ed., pp. 1164-1167, Wolfe Publishing, London, 1994.

5. Connoles MD: Review of animal mycoses in Australia. *Mycopathologia*, 111, 133-164, 1990.

6. Kırmızıgül AH, Gökçe E, Özyıldız Z, Büyük F, Şahin M: Sığırlarda dermatofitozis tedavisinde enilconazole'ün (%10) topikal kullanımı: Klinik, mikolojik ve histopatolojik bulgular. *Kafkas Univ Vet Fak Derg*, 15 (2): 273-277, 2009.

7. Kırmızıgül AH, Gökçe E, Mitat Ş, Büyük F, Irmak K: Dermatofitozisli sığırlarda enilconazole'ün (%10'luk Pour-On) etkinliği. *Kafkas Univ Vet Fak Derg*, 14 (2): 141-144, 2008.

8. Stenwig H: Isolation of dermatophytes from domestic animals in Norway. *Nord Vet Med*, 37, 161-169, 1985.

9. Nooruddin M, Singh B: Dermatophytosis in buffaloes, cattle and their attendants. *Mykosen*, 30, 594-600, 1987.

10. Cam Y, Gumussoy KS, Kibar M, Apaydin N, Atalay O: Efficacy of ethylenediamine dihydriodide for the treatment of ringworm in young cattle. *Vet Rec*, 24, 408-410, 2007.

11. Gökçe G, Şahin M, Irmak K, Otlı S, Aydın F, Genç O: Sığır trichophytosis'inde profilaktik ve terapötik amaçla aşı kullanımı. *Kafkas Univ Vet Fak Derg*, 5 (1): 81-86, 1999.

12. Rybníkář A, Chumela J, Vrzał V, Krupka V: Immunity in cattle vaccinated against ringworm. *Mycoses*, 34, 433-436, 1991.

13. Rybníkář A, Vrzał V, Chumela J: Protective efficacy of vaccines against bovine dermatophytosis after double and single vaccination. *Mycoses*, 41, 83-86, 1998.

14. Wawrzekiewicz K, Wawrzekiewicz J: An inactivated vaccine against ringworm. *Comp Immunol Microbiol Infect Dis*, 15, 31-40, 1992.

15. Courtney CH, Roberson EL: Ivermectin. In: Adams HR (Ed): Veterinary Pharmacology and Therapeutics. p. 920, Iowa State University Press, Ames, Iowa, 1995.

16. Uhlir J: Effect of ivermectin on the development of serum antibody activity in rabbits infested with *Psoroptes cuniculi* (Acari: Psoroptidae). *Folia Parasitol (Praha)*, 38, 79-82, 1991.

17. Rao UR, Chandrashekar R, Subrahmanyam D: Effect of ivermectin on serum dependent cellular interactions to *Dipetalonema viteae* microfilariae. *Trop Med Parasitol*, 38, 123-127, 1987.

18. Dennis VA, Klei TR, Miller MA, Chapman MR, McClure JR: Immune responses of pony foals during repeated infections of *Strongylus vulgaris* and regular ivermectin treatments. *Vet Parasitol*, 42, 83-99, 1992.

19. Knab J, Darge K, Buttner DW: Immunohistological studies on macrophages in lymph nodes of onchocerciasis patients after treatment

with ivermectin. *Trop Med Int Health*, 2, 1156-1169, 1997.

20. Blakley BR, Rousseaux CG: Effect of ivermectin on the immune response in mice. *Am J Vet Res*, 52, 593-595, 1991.

21. Aslan Ö, Oruç E: Is it possible to treat equine papillomatosis with ivermectin given orally? *Kafkas Univ Vet Fak Derg*, 16 (6): 1065-1068, 2010.

22. Borku MK, Atalay O, Kibar M, Cam Y, Atasever A: Ivermectin is an effective treatment for bovine cutaneous papillomatosis. *Res Vet Sci*, 83, 360-363, 2007.

23. Kırmızıgül AH, Gökçe E, Sözmen M, Yıldırım Y, Beytut E: İvermektin'in sığır deri papillomatozisinde tedavi etkinliği. *Kafkas Univ Vet Fak Derg*, 16 (4): 627-631, 2010.

24. Cheesbrough M: Medical Laboratory Manual for Tropical Countries. Vol. 2, pp. 371-385, Tropical Health Technology, Butterworth-Heinemann, Great Britain, 1992.

25. Halley LD, Standard PG: Laboratory Methods in Medical Mycology. 3rd ed., pp. 41-57, US Department of Health, Education and Welfare, Center of Disease Control, Atlanta, 1973.

26. Quinn PJ, Carter ME, Markey B, Carter GR: The dermatophytes. In: Clinical Veterinary Microbiology. 5th ed., pp. 381-390, London, New York, Philadelphia, Sydney, Toronto, Mosby, 2002.

27. Pascoe RR: The epidemiology of ringworm in racehorses caused by *Trichophyton equinum* var *autotrophicum*. *Aust Vet J*, 55, 403-407, 1979.

28. Al-Ani FK, Younes FA, Al-Rawashdeh OF: Ringworm infection in cattle and horses in Jordan. *Acta Vet Brno*, 71, 55-60, 2002.

29. Imren HY, Sahal M: Trikofiti. In: Alacam E, Sahal M (Eds): Sığır Hastalıkları. Birinci Baskı. s. 201-202, Medisan, Ankara, 1997.

30. Stannard AA: Dermatophytosis. In: Smith BP (Ed): Large Animal Internal Medicine, 2nd ed., pp. 1419-1421, Philadelphia, London, Tokyo, Mosby, 1996.

31. Kaaman T: Dermatophyte antigens and cell-mediated immunity in dermatophytosis. In: McGinnis MR (Ed): Current Topics in Medical Mycology. Vol. 1, pp. 117-134, New York, Springer-Verlag, 1985.

32. Sohnle PG: Dermatophytosis. In: Murphy JW, Friedman H, Bendinello M (Eds): Fungal Infections and Immune Response. pp. 27-47, New York, Plenum, 1993.

33. Weigl E: Immunology in dermatophytoses. *Cesk Epidemiol Mikrobiol Immunol*, 36, 308-319, 1987.

34. Pier AC, Ellis JA, Mills KW: Development of immune response to experimental bovine *Trichophyton verrucosum* infection. *Vet Dermatol*, 3, 131-138, 1993.