

RESEARCH ARTICLE

Determinate of ECG, Oxidative Stress, and Angiogenesis in APAP-Induced Toxicity in Rats

Mustafa MAKAV ^{1,a (*)} Turgut DOLANBAY ^{2,b} Huseyin Fatih GUL ^{3,c} Emin KARAKURT ^{4,d}¹ Kafkas University, Faculty of Veterinary Medicine, Department of Physiology, TR-36100 Kars - TURKEY² Kafkas University, Faculty of Medicine, Department of Medical Emergency, TR-36100 Kars - TURKEY³ Kafkas University, Faculty of Medicine, Department of Medical Biochemistry, 36100, Kars Turkey⁴ Kafkas University, Faculty of Veterinary Medicine, Department of Pathology, TR-36100 Kars - TURKEYORCID: ^a 0000-0003-1879-8180; ^b 0000-0002-4092-1192; ^c 0000-0002-9828-1298; ^d 0000-0003-2019-3690

Article ID: KVFD-2021-25733 Received: 11.03.2021 Accepted: 22.07.2021 Published Online: 28.07.2021

Abstract

This study was aimed to evaluate the effects of N-acetyl-p-aminophenol (APAP) toxicity on the cardiovascular system as there exist relatively a few studies on this matter. The study included 14 female Wistar rats divided into two groups having 7 rats in each (control-APAP). Control group received no medication and APAP group was given single oral dose of 1g/kg APAP. ECG measurements of each animal in either group were obtained before the administration of APAP (0 h) and at the 1st, 6th, 12th and 24th h after the APAP administration. All animals were sacrificed at the end of the study. Heart tissue samples were obtained for biochemical and histopathological analyses. The levels of MDA, GSH, Apelin, Elabela, Meteorin, Endoglin, Keap1, and Nrf2 were measured in the tissue samples. Results revealed a statistically significantly prolonged QTc and QRS intervals and increased heart in the APAP group. A notable increase in MDA and Endoglin, and a significant decrease in GSH, Elabela, and Nrf2 levels occurred in the APAP group. Histopathologically, necrotic lesions were found in the APAP group. The use of high doses of APAP as an analgesic may cause permanent damage in the cardiovascular system.

Keywords: N-acetyl-p-aminophenol, ECG, Apelin, Elabela, Meteorin, Endoglin

Sıçanlarda APAP Kaynaklı Toksisitede EKG, Oksidatif Stres ve Anjiyogenezin Belirlenmesi

Öz

Bu çalışma, N-acetyl-p-aminophenol (APAP) toksisitesinin kardiyovasküler sistem üzerindeki etkilerini değerlendirmeyi amaçlamıştır çünkü bu konuda nispeten az sayıda çalışma bulunmaktadır. Çalışma kapsamında her grupta 7 rat (kontrol ve APAP) olacak şekilde 14 adet dişi wistar rat kullanıldı. Kontrol grubuna herhangi bir uygulama yapılmazken APAP grubuna tek doz 1 g/kg N-acetyl-p-aminophenol oral olarak verilmiştir. Apap uygulaması öncesi 0. saat ve uygulama sonrası 1. saat 6. saat 12. saat ve 24. saatte iki gruptaki tüm hayvanlara EKG ölçümü yapıldı. Çalışma sonunda tüm hayvanlar kurban edildi. Biyokimyasal ve histopatolojik analizler için kalp dokusu örnekleri alındı. Doku örneklerinden MDA, GSH, Apelin, Elabela, Meteorin, Endoglin, Keap1 ve Nrf2 ölçümleri yapıldı. Yapılan analizlere göre ekg verilerinde QTc, kalp atım sayısı ve QRS'de APAP grubunda istatistiksel anlamda artış belirlendi. Biyokimyasal verilerde ise APAP grubunda MDA ve Endoglinde anlamlı artış bulunurken GSH, Elabela ve Nrf2'de ise anlamlı bir azalma belirlenmiştir. Histopatolojik olarak APAP grubunda nekroze lezyonlara rastlanmıştır. Sonuç olarak analjezi olarak kullanılan APAP yüksek doz alımlarında kardiyovasküler sistemde kalıcı hasarlara yol açabilmektedir.

Anahtar sözcükler: N-acetyl-p-aminophenol, EKG, Apelin, Elabela, Meteorin, Endoglin

INTRODUCTION

Acetaminophen (paracetamol) is a commonly used analgesic-antipyretic drug in the US since 1955. Paracetamol overdose accounts for a significant number of emergency service admission ^[1,2]. When taken in therapeutic doses, the major

quantity of paracetamol is conjugated with glucuronic acid and sulphate, and the remaining small quantity is converted to the N-acetyl-p-benzoquinoneimine (NAPQI) metabolite by hepatic cytochrome P-450 dependent mixed-function oxidases in the liver ^[3,4]. Under normal circumstances, NAPQI is rapidly converted to its non-toxic

How to cite this article?

Makav M, Dolanbay T, Gul HF, Karakurt E: Determinate of ECG, oxidative stress, and angiogenesis in APAP-induced toxicity in rats. *Kafkas Univ Vet Fak Derg*, 27 (4): 483-488, 2021.
DOI: 10.9775/kvfd.2021.25733

(*) Corresponding Author

Tel: +90 474 242 6807/5165

E-mail: mustafamakav@gmail.com (M. Makav)



This article is licensed under a Creative Commons Attribution-NonCommercial 4.0 International License (CC BY-NC 4.0)

metabolites by glutathione (GSH). However, under GSH-deficient conditions NAPQI cannot be converted to non-toxic metabolites leading to liver damage. Paracetamol overdose can clinically manifest by metabolic acidosis, elevated lactate, hypoglycaemia, and acute nephrotoxicity and hepatotoxicity. There exist few studies on paracetamol cardiotoxicity. Several studies have focused on the direct toxic effects of acetaminophen on the heart [1,5].

Apelin, a cardiovascular system associated hormone, is particularly effective in regulating the blood flow and lowering the blood pressure. Elabela and Apelin antagonize the renin-angiotensin system; thus, playing a role in preventing the development and slowing the progression of cardiovascular diseases. Furthermore, apelin and related peptide receptors have also cardioprotective effects in atherosclerosis, myocardial infarction, heart failure, and pulmonary arterial hypertension [6].

Meteorin-like (Metrl) is a recently discovered adipokine that acts on insulin sensitivity favourably. Adipokines actively take part in lipid metabolism and inflammation. Adipokines are involved in cardiometabolic diseases including coronary diseases. The most important cause of coronary diseases is atherosclerosis. In such cases, Metrl causes increased levels of anti-inflammatory cytokines [7].

Endoglin is an essential co-receptor for transforming growth factor β (TGF- β) family, playing an important role in angiogenesis. Increased levels of circulating endoglin have been found in hypertensive or diabetic patients, in early stages of preeclampsia, and in some cancer patients. These suggest that endoglin can be a predictive biomarker in these pathological conditions [8].

The nuclear factor erythroid 2-related factor 2 (Nrf2) and Kelch-like ECH-associated protein 1 (Keap1) are proteins that play an active role in apoptosis. Simultaneous depletion of Nrf2 and Keap1 is known to prevent apoptosis. Nrf2 and Keap1 are also reported to have a protective effect against oxidative stress [9].

In this study, we aimed to find out whether cardiotoxic damage and cardiac rhythm disturbances develop in paracetamol toxicity, and to identify new biomarkers that could be used for early diagnosis.

MATERIAL AND METHODS

This study was approved by Kafkas University Animal Experiments Local Ethics Committee (Approval No: KAÜ-HADYEK 2019/122) Kars, Turkey. The study included 14 female, 4-6-month-old Wistar-Albino rats with an average weight of 190-250 g. All animals were fed ad-libitum, maintained at a room temperature of approximately 25°C, and kept under 12-h light-dark cycles. Animals were divided into two equal groups (7 rats in each). Paracetamol was obtained from Atabay Pharmaceuticals Inc.

The Experimental Groups

Group I (Control): Rats were administered only 0.9% NaCl orally.

Group II (Toxicity): Toxicity was induced in rats by administering a single oral dose of Paracetamol (1 g/kg) [10].

Electrocardiography (ECG) measurements were obtained from each animal in the experiment under anaesthesia [ketamine HCl (75 mg/kg) (Ketalar, Pfizer®), and xylazine HCl (10 mg/kg) (Rompun, 2%, Bayer®) intramuscular] [11] before the induction of toxicity (0 h) and at 1st, 6th, 12th, and 24th h after inducing toxicity using Nihon Kohden cardiofax S ECG-1250 device. Digital ECG records were obtained using the leads I, II, III, aVR, aVL, and aVF at a velocity of 50 mm/s, at a calibration of 1 mV=10 mm, and using a 50-Hz filter (Fig. 1). The device calculates the QTc data automatically; therefore, no further calculations were performed [12].

At the end of the study, animals were not fed overnight and cardiac tissue samples were collected after sacrificing via cervical dislocation under anaesthesia [11] in compliance with ethical principles.

Biochemical Measurements

The tissue samples were homogenized in phosphate buffer (pH 7.4) and centrifuged at 3000 rpm for 5 min. The obtained homogenates were kept at -20°C until analysis. Apelin, Elabela, Meteorin, Endoglin, Keap1, and Nrf2 levels were determined in the cardiac tissue by using commercially available Enzyme-Linked Immunosorbent Assay (ELISA-YL Biotech Company, Shanghai) kits in compliance with the manufacturer's instructions. The GSH and MDA levels in the cardiac tissue were analysed applying the methods described by Beutler et al. [13] and Yoshioka et al. [14], respectively.

Histological Analysis

The cardiac tissues were fixed in 10% buffered formaldehyde solution. The tissues were subjected to tissue processing in an automated device (Leica TP 1020). Sections of 5- μ m thickness were taken from the tissues that were manually embedded in paraffin and the sections were stained with Hematoxylin & Eosin. The sections were examined and photographed under a light microscope (Olympus BX46) [15].

Statistical Analyses

Before the study, power analysis was performed using G-Power 3.1.9.7. According to the analysis, the sample size was decided according to the test power of 0.95 and the significance level of 0.05. Analysis of independent samples t-test was conducted for all the biochemical and ECG parameters to test if there is a difference between the two groups. Analysis of repeated-measures ANOVA was conducted for ECG parameters obtained on different time.

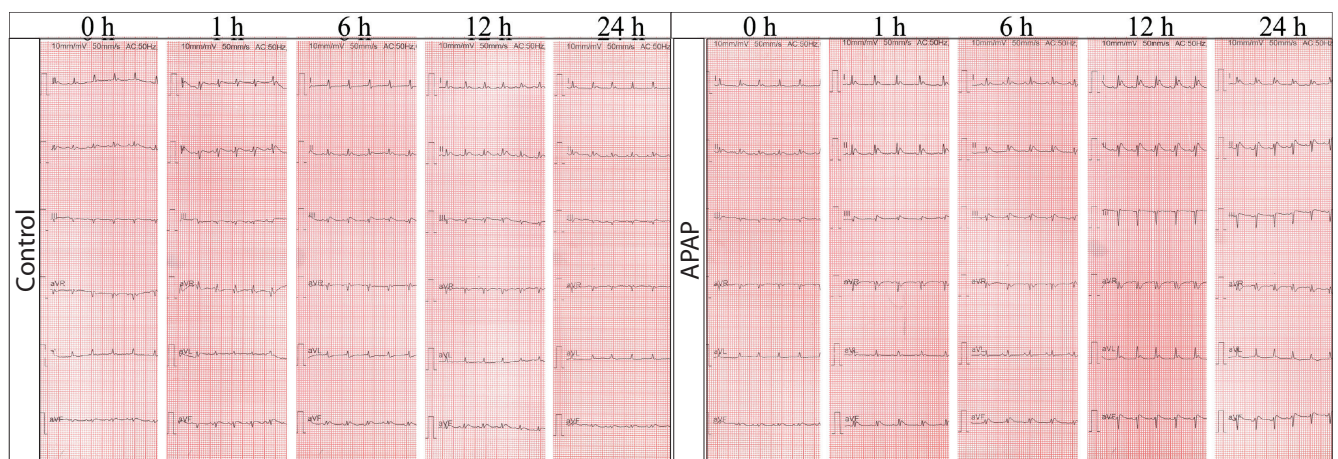
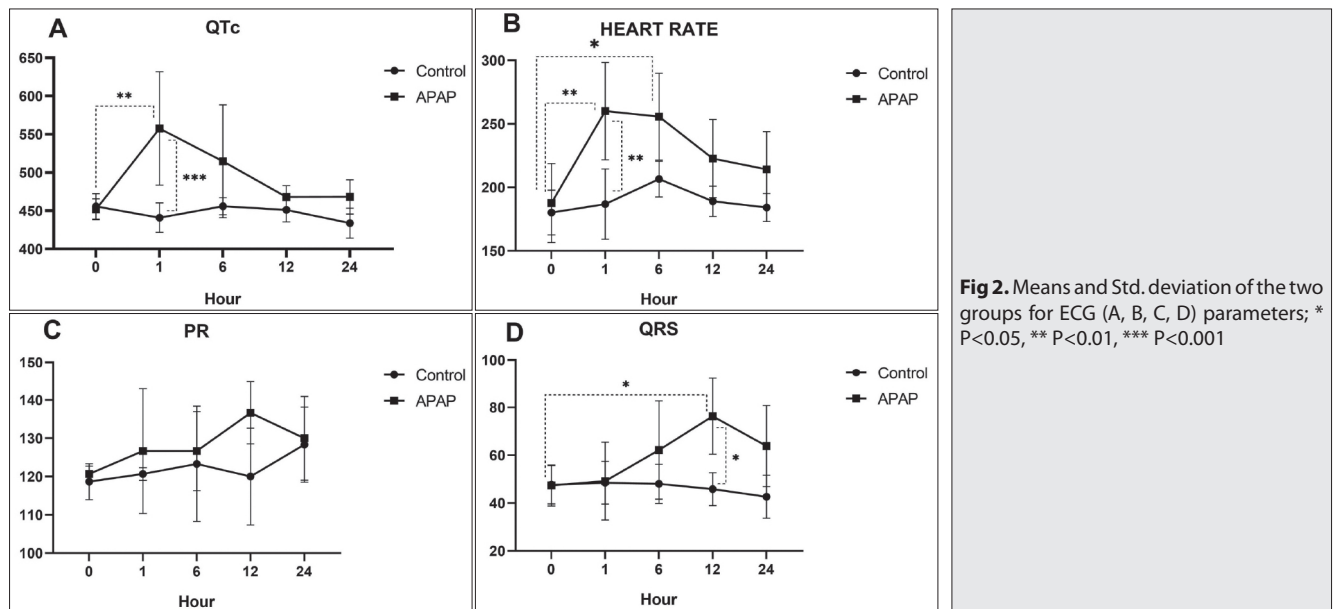


Fig 1. ECG changes according to time interval in control and APAP groups



A P-value of <0.05 was accepted as significant. GraphPad 8.1 (San Diego, CA, USA) was used for statistical analyses.

RESULTS

ECG Results

The QTc interval (*Fig. 2-A*) significantly increased at the 1st h in the APAP group compared to 0 hour ($P < 0.01$) and to that of the control group at the 1st h ($P < 0.001$).

The heart rate (*Fig. 2-B*) significantly increased both at the 1st ($P < 0.01$) and the 6th h ($P < 0.05$) in the APAP group compared to 0 h. When the APAP group was compared with the control group, a significant increase in the heart rate was observed in the APAP group at the 1st compared to the control group.

The PR interval (*Fig. 2-C*) did not change throughout the study between and within the groups.

A significant difference in the QRS complex (*Fig. 2-D*) was detected in the APAP group between the values at 0 h and the 12th h ($P < 0.05$). Similarly, a significant difference was determined between the APAP group and the control group in terms of QRS complex at the 12th h ($P < 0.05$).

Biochemical Results

Malondialdehyde levels significantly increased in the APAP group compared to the control group ($P < 0.05$) while GSH levels markedly decreased between the groups ($P < 0.01$, *Fig. 3-A,B*).

The analysis of Apelin, Meteorin, and Keap1 levels revealed no differences between the APAP and the control groups (*Fig. 3-C,D,E,F,G,H*). However, a statistically significant decrease in Elabela ($P < 0.001$) and Nrf2 ($P < 0.05$) levels, and a notable increase in Endoglin ($P < 0.05$) levels were noted between APAP and control groups.

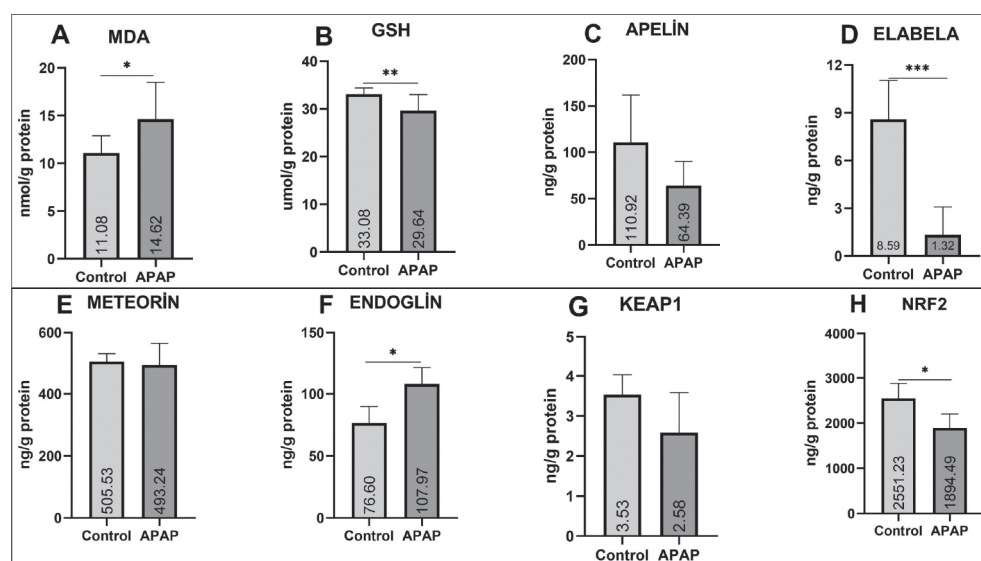


Fig 3. Means and Std. deviation of the two groups for biochemical (A, B, C, D, E, F, G, H) parameters. *P<0.05, **P<0.01, ***P<0.001

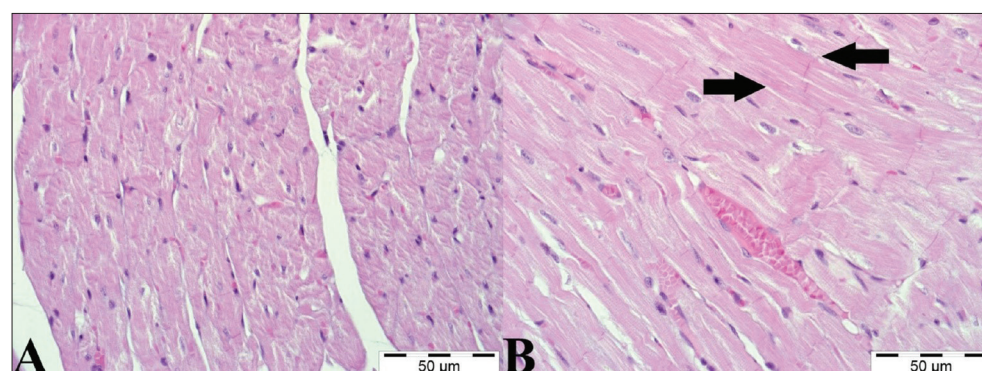
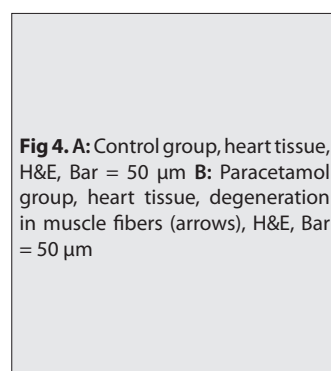


Fig 4. A: Control group, heart tissue, H&E, Bar = 50 μm **B:** Paracetamol group, heart tissue, degeneration in muscle fibers (arrows), H&E, Bar = 50 μm

Histological Results

On histopathological examinations, cardiac tissue was normal had no pathological changes in control group. In APAP group, muscle fibers were swollen and homogeneous in pink color, the transverse striation of the muscle fibers disappeared and in addition to degenerative changes, the presence of necrotic cells with pycnotic nuclei was remarkable (Fig. 4).

DISCUSSION

Raising awareness about recognizing new and early symptoms, signs, and biochemical markers in paracetamol overdose is important in the early diagnosis and treatment in order to reduce mortality and morbidity.

Cardiac autonomic dysfunction can be detected by various tests and some ECG findings (PR, QT interval, QTc, QRS complex). The relationship between a prolonged QT interval and sudden cardiac death in various diseases such as coronary artery disease and heart failure is known [16]. In our study, the increase in the length of the QTc interval and the heart rate has been demonstrated at the 1st h after paracetamol overdose compared to the control group. Furthermore, cardiac tissue damage in paracetamol overdose

has been shown histopathologically. The development of these findings after paracetamol overdose can be explained by the degeneration of cardiac cells leading to delays in cardiac conduction and changes in cardiac conduction pathways resulting in delayed action potentials.

N-acetyl-p-benzoquinoneimine formed in paracetamol overdose cases causes cellular injury and cell death by binding to cellular proteins [1]. We expect that the underlying mechanism of cardiac injury in paracetamol overdose is the cardiac cell damage resulting from the transport of NAPQI to the cardiac blood supply by the venous system.

An intraventricular conduction delay or a bundle branch block is considered in depolarization disorders of the cardiovascular system [17]. Afshari et al. [18] conducted a study and found out that paracetamol overdose was associated with a prolonged QRS complex detected via ECG monitoring.

This study found significant prolonged QRS complex at the 12th h compared to the zero h in the APAP group, suggesting a conduction delay consistent with previous studies. We assumed that the underlying reason was the impairment in the signal transduction pathway; affected by secondary to cardiac tissue damage. This condition is

supported by the levels of the inflammatory, oxidant, and antioxidant parameters determined in our study.

N-acetyl-p-benzoquinoneimine, induced by high-dose paracetamol, causes the formation of reactive oxygen species in cells resulting in lipid peroxidation. Lipid peroxidation leads to GSH deficiency and protein synthesis in hepatocytes, finally resulting in intracellular calcium (Ca^{+2}) imbalance in liver cells [19]. The GSH levels in our study significantly reduced in the APAP group compared to the control group. This may be attributed to high NAPQI causing reduction in GSH levels in cardiac cell injury resulting from impaired protein synthesis and changes in intracellular Ca levels. Another indicator of tissue damage is the increased MDA levels caused by lipid peroxidation [20] as was the case in the cardiac tissue in our study consistent with earlier studies where paracetamol induced increased MDA levels and reduced GSH levels [4,21]. Zhao et al. [22] reported elevated MDA levels and reduced GSH levels in doxorubicin-induced cardiotoxicity similar to the results of our study.

Both Apelin and Elabela are suggested to have cardio-protective, vasodilator, hypotensive, and strong positive inotropic effects [23]. In our study, the changes in apelin levels were not statistically significant but a notable decrease in Elabela levels was found in the paracetamol group. Elabela is heavily expressed in the cardiovascular endothelium. Elabela is required for normal heart development and angiogenesis and is available in the heart tissue more abundantly compared to apelin [24]. The reduction in Elabela levels may suggest the occurrence of damaged cells. Furthermore, Elabela and Apelin are reported to play an active role in preventing cardiovascular diseases by antagonizing the renin-angiotensin system [6]. Considering this feature, the numerical reduction in Apelin levels and the statistically significant reduction in Elabela levels in our study may represent a challenge to eliminate the effects of paracetamol toxicity.

Dadmanesh et al. [7] reported that coronary artery patients had significantly reduced Meteorin levels compared to the control group in their study. However, a numerical decrease in Meteorin levels was found in the cardiac tissue of the rats in the toxicity group in our study but no statistically significant differences were observed.

Endoglin is a transmembrane co-receptor involved in the transformation of the growth factor- β (TGF- β) expressed predominantly on proliferating endothelial cells. Endoglin-knockout mice die of cardiovascular defects at mid-gestation. Endoglin is expressed at low levels in cells of normal endothelial tissue, but its over activity can be observed in infected tissue during embryogenesis [25]. In our study, we expect that the Endoglin levels were found to be significantly high due to histopathologically confirmed cardiac cell damage. Jacob et al. [26] reported focal necrosis in myocardium due to APAP as was the case in our study. Kapur

et al. [27] investigated endoglin levels in cardiac fibrosis and reported the isolation of very high levels of endoglin in the fibrosis group. We found statistically high Endoglin levels in the toxicity group of our study consistent with the findings of the study reported by Kapur et al. [27]. Considering the effective role of endoglin in angiogenesis, the high levels of endoglin in the toxicity group in our study support the toxic effect of paracetamol on the heart. This finding also suggests that endoglin levels can potentially be used as a marker of the effects of paracetamol intoxication on the heart tissue.

The radicals produced in a variety of physiological conditions are neutralized by antioxidative defence mechanisms [8,28]. Free oxygen radicals are also reported to play an active role in apoptosis. Nrf2 and Keap1 are involved in cell regenerating processes together. However, their levels are significantly reduced during these processes [9]. Under the light of this information, the respectively numerical and statistical reductions in the Nrf2 and Keap1 levels in the toxicity group indicate the activation of apoptotic mechanisms in response to cellular injury. Zhao et al. [22] found a significant reduction in Nrf2 levels in the toxicity group, similar to the results of our study.

It is very important to detect early tissue and organ damage in paracetamol overdose. Our study shows the importance of the early recognition of ECG changes including the lengths of QTc interval and QRS complex, and the heart rate, especially at the first hours of intoxication. Paracetamol overdose induced heart injury might be associated with some novel biomarkers as such studied here.

FUNDING SUPPORT

The study was not sponsored by any funding sources.

AVAILABILITY OF DATA AND MATERIALS

The datasets during and/or analyzed during the current study available from the corresponding author on reasonable request.

CONSENT FOR PUBLICATION

N/A

CONSENT TO PARTICIPATE

Not applicable.

COMPETING INTERESTS

The authors declare that they have no competing interests

AUTHORS' CONTRIBUTIONS

MM and TD analyzed and interpreted the data and was a major contributor in writing the manuscript. EK and HFG analyzed and interpreted the data. All authors read and approved the final manuscript.

REFERENCE

- 1. Lancaster EM, Hiatt JR, Zarrinpar A:** Acetaminophen hepatotoxicity: An updated review. *Arch Toxicol*, 89 (2): 193-199, 2015. DOI: 10.1007/s00204-014-1432-2
- 2. Piotrowska N, Klukowska-Rötzler J, Lehmann B, Krummrey G, Haschke M, Exadaktylos AK, Liakoni E:** Presentations related to acute paracetamol intoxication in an Urban Emergency Department in Switzerland. *Emerg Med Int*, 2019:3130843, 2019. DOI: 10.1155/2019/3130843
- 3. Mucahit E:** Asetaminofen (Parasetamol) zehirlenmesi. *Türkiye Klinikleri J Emerg Med-Special Topics*. 2 (1): 51-57, 2016.
- 4. Cenesiz S:** The role of oxidant and antioxidant parameters in the infectious diseases: A systematic literature review. *Kafkas Univ Vet Fak Derg*, 26 (6): 849-858, 2020. DOI: 10.9775/kvfd.2020.24618
- 5. Salem GA, Shaban A, Diab HA, Elsaghayer WA, Mjedib MD, Hnesh AM, Sahu RP:** Phoenix dactylifera protects against oxidative stress and hepatic injury induced by paracetamol intoxication in rats. *Biomed Pharmacother*, 104, 366-374, 2018. DOI: 10.1016/j.biopha.2018.05.049
- 6. Acele A, Bulut A, Donmez Y, Koc M:** Serum elabela level significantly increased in patients with complete heart block. *Braz J Cardiovasc Surg*, 35 (5): 683-688, 2020. DOI: 10.21470/1678-9741-2019-0461
- 7. Dadmanesh M, Aghajani H, Fadaei R, Ghorban K:** Lower serum levels of Meteorin-like/Subfatin in patients with coronary artery disease and type 2 diabetes mellitus are negatively associated with insulin resistance and inflammatory cytokines. *PloS One*, 13 (9): e0204180, 2018. DOI: 10.1371/journal.pone.0204180
- 8. Rossi E, Bernabeu C, Smadja DM:** Endoglin as an adhesion molecule in mature and progenitor endothelial cells: A function beyond TGF- β . *Front Med*, 6:10, 2019. DOI: 10.3389/fmed.2019.00010
- 9. Ashino T, Yamamoto M, Numazawa S:** Nrf2/Keap1 system regulates vascular smooth muscle cell apoptosis for vascular homeostasis: Role in neointimal formation after vascular injury. *Sci Rep*, 6:26291, 2016. DOI: 10.1038/srep26291
- 10. Kuvandik G, Duru M, Nacar A, Yonden Z, Helvacı R, Koc A, Kozlu T, Kaya H, Sogut S:** Effects of erdosteine on acetaminophen-induced hepatotoxicity in rats. *Toxicol Pathol*, 36 (5): 714-719, 2008. DOI: 10.1177/0192623308320800
- 11. Gaertner DJ, Hallman TM, Hankenson FC, Batchelder MA:** Anesthesia and analgesia for laboratory rodents. In: Fish RE, Brown MJ, Danneman PJ, Karas AZ (Eds): *Anesthesia and Analgesia in Laboratory Animals*. 2nd ed., 239-297, Academic Press, San Diego, 2008. DOI: 10.1016/B978-012373898-1.50014-0
- 12. Hirota M, Ohtani H, Hanada E, Kotaki H, Sawada Y, Iga T:** Effects of hypokalaemia on arrhythmogenic risk of quinidine in rats. *Life Sci*, 62 (24): 2159-2169, 1998. DOI: 10.1016/S0024-3205(98)00193-3
- 13. Beutler E, Duron O, Kelly BM:** Improved method for the determination of blood glutathione. *J Lab Clin Med*, 61 (5): 882-888, 1963.
- 14. Yoshioka T, Kawada K, Shimada T, Mori M:** Lipid peroxidation in maternal and cord blood and protective mechanism against activated-oxygen toxicity in the blood. *Am J Obstet Gynecol*, 135 (3): 372-376, 1979. DOI: 10.1016/0002-9378(79)90708-7
- 15. Palabiyik SS, Karakus E, Akpınar E, Halıcı Z, Bayir Y, Yayla M, Kose D:** The role of urotensin receptors in the paracetamol-induced hepatotoxicity model in mice: Ameliorative potential of ırotensin II antagonist. *Basic Clin Pharmacol Toxicol*, 118 (2): 150-159, 2016. DOI: 10.1111/bcpt.12447
- 16. Garadah TS, Kassab S, Mahdi N, Abu-Taleb A, Jamsheer A:** QTc interval and QT dispersion in patients with thalassemia major: Electrocardiographic (EKG) and echocardiographic evaluation. *Clin Med Insights Cardiol*, 4 (3): 31-37, 2010. DOI: 10.4137/CMC.S4472
- 17. Schlant RC, Adolph RJ, DiMarco JP, Dreifus LS, Dunn MI, Fisch C, Garson Jr A, Haywood LJ, Levine HJ, Murray JA:** Guidelines for electrocardiography. A report of the american college of cardiology/american heart association task force on assessment of diagnostic and therapeutic cardiovascular procedures (Committee on electrocardiography). *Circulation*, 85 (3): 1221-1228, 1992. DOI: 10.1161/01.cir.85.3.1221
- 18. Afshari R, Maxwell S, Dawson A, Bateman DN:** ECG abnormalities in co-proxamol (paracetamol/dextropropoxyphene) poisoning. *Clin Toxicol*, 43 (4): 255-259, 2005. DOI: 10.1081/CLT-66069
- 19. Panduri V, Weitzman SA, Chandel NS, Kamp DW:** Mitochondrial-derived free radicals mediate asbestos-induced alveolar epithelial cell apoptosis. *Am J Physiol-Lung Cell Mol Physiol*, 286 (6): L1220-L1227, 2004. DOI: 10.1152/ajplung.00371.2003
- 20. Hung OL, Nelson LS:** Acetaminophen. In: Tintinalli JE, Stapczynski JS, Ma OJ, Yealy DM, Meckler GD, Cline DM (Eds): *Tintinalli's Emergency Medicine: A Comprehensive Study Guide*. 8th ed., 1269-1275, McGraw-Hill Education, United Kingdom, 2016.
- 21. Eroğlu HA, Makav M, Adalı Y, Çitil M:** Effects of ozone and L-carnitine on kidney MDA, GSH, and GSHPx levels in acetaminophen toxicity. *Kafkas Univ Vet Fak Derg*, 26 (1): 127-134, 2020. DOI: 10.9775/kvfd.2019.22456
- 22. Zhao L, Qi Y, Xu L, Tao X, Han X, Yin L, Peng J:** MicroRNA-140-5p aggravates doxorubicin-induced cardiotoxicity by promoting myocardial oxidative stress via targeting Nrf2 and Sirt2. *Redox Biol*, 15, 284-296, 2018. DOI: 10.1016/j.redox.2017.12.013
- 23. Shin K, Kenward C, Rainey JK:** Apelinergic system structure and function. *Compr Physiol*, 8 (1): 407-450, 2017. DOI: 10.1002/cphy.c170028
- 24. Zhang Y, Wang Y, Lou Y, Luo M, Lu Y, Li Z, Wang Y, Miao L:** Elabela, a newly discovered APJ ligand: Similarities and differences with apelin. *Peptides*, 109, 23-32, 2018. DOI: 10.1016/j.peptides.2018.09.006
- 25. Fonsatti E, Jekunen AP, Kairemo KJ, Coral S, Snellman M, Nicotira MR, Natali PG, Altomonte M, Maio M:** Endoglin is a suitable target for efficient imaging of solid tumors: *In vivo* evidence in a canine mammary carcinoma model. *Clin Cancer Res*, 6 (5): 2037-2043, 2000.
- 26. Jacob S, Cherian P, Preusz C, Kovacs R:** Heartbreaking case of acetaminophen poisoning. *Circulation*, 118, e513-e514, 2008. DOI: 10.1161/CIRCULATIONAHA.108.779520
- 27. Kapur NK, Wilson S, Yunis AA, Qiao X, Mackey E, Paruchuri V, Baker C, Aronovitz MJ, Karumanchi SA, Letarte M, Kass DA, Mendelsohn ME, Karas RH:** Reduced endoglin activity limits cardiac fibrosis and improves survival in heart failure. *Circulation*, 125 (22): 2728-2738, 2012. DOI: 10.1161/CIRCULATIONAHA.111.080002
- 28. Kuru M, Ögün M, Oral H, Kükürt A, Makav M, Kulaksız R:** The use of controlled internal drug release for synchronization augmented oxidative and nitrosative stress and leptin levels in Georgian goats. *J Cell Neurosci Oxid Stress*, 8 (1): 541-542, 2016.