

PEDIATRIC TYMPANIC MEMBRANE CHOLESTEATOMA: A RARE CASE REPORT

Pediatric Otolaryngology

Submitted : 20.04.2016

Accepted : 09.05.2016

Published : 09.05.2016

Selmin Karataylı Özgürsoy¹, Mustafa Mert Başaran¹, Haldun Umudum¹, Sefa Kaya¹

¹ Ufuk Üniversitesi Tıp Fakültesi

Özet

PEDİATRİK TİMPANİK MEMBRAN KOLESTEATOMU: NADİR BİR OLGU SUNUMU

Pediyatrik konjenital kolesteatomalar genellikle asemptomatik olan; bu nedenle kulak burun boğaz uzmanları ve pediatristler açısından tanı konması zor olan nadir bir hastalıktır. Timpan membran içerisinde konjenital kolesteatom daha da nadir görülmektedir. Orta kulak ve iç kulak hasarını önlemek amacıyla timpan membran kolesteatomalarının erken tanı ve tedavisi önemlidir. Kulak zarında görülen beyaz noktasal kitle kolesteatomayı düşündürmelidir. Ayırıcı tanıda, timpanoskleroz, yabancı madde, keratozis obliterans ve kolesterol granülomu akılda tutulmalıdır. Bu yazıda; 2 yaşında timpan membran kolesteatomu tanısı konan kız hasta sunuldu.

Anahtar kelimeler: *Keratinöz kist, Kolesteatoma, Konjenital kolesteatoma, Timpan Membran, Pediyatrik kolesteatoma*

Abstract

PEDIATRIC TYMPANIC MEMBRANE CHOLESTEATOMA: A RARE CASE REPORT

We present a rare case of tympanic membrane cholesteatoma (TMC) in a 2 year-old girl. Pediatric congenital cholesteatomas are rare and generally asymptomatic, making it difficult for otorhinolaryngologists and pediatricians to diagnose early. Congenital cholesteatomas within the tympanic membrane (TM) are even more rare. Early diagnosis and treatment of TMC is essential to avoid progressive destruction in the ear. A whitish spot on the TM should raise suspicion for cholesteatoma. In differential diagnosis, tympanosclerosis, foreign bodies, keratosis obliterans and cholesterol granuloma always should be kept in mind.

Keywords: *Cholesteatoma, Congenital cholesteatoma, Tympanic membrane, Keratinous cyst, Pediatric cholesteatoma.*

Introduction

Pediatric congenital cholesteatomas are rare and generally asymptomatic, making it difficult for otorhinolaryngologists and pediatricians to diagnose early. Congenital cholesteatomas within the tympanic membrane (TM) are even more rare. Tympanic membrane cholesteatoma (TMC) was first described in 1863 by Hinton [1,2]. Less than 25 cases of TMC without previous otorrhea or ear surgery have been reported to date in the literature [3-8]. Early diagnosis and treatment is essential since the lesion can advance just like any other cholesteatoma. A white spot on TM should raise suspicion for TMC [9]. We present a 2 year-old girl with left TMC located in the posterosuperior quadrant.

Case Report

A 2 year-old girl was presented to our outpatient clinic with persistent coughing for 2 months. Otolaryngologic examination did not reveal any abnormality except left TM. Otomicroscopic examination revealed a 2 mm whitish, clearly shaped, non-pulsatile mass at the posterosuperior quadrant of TM (**Figure 1**).

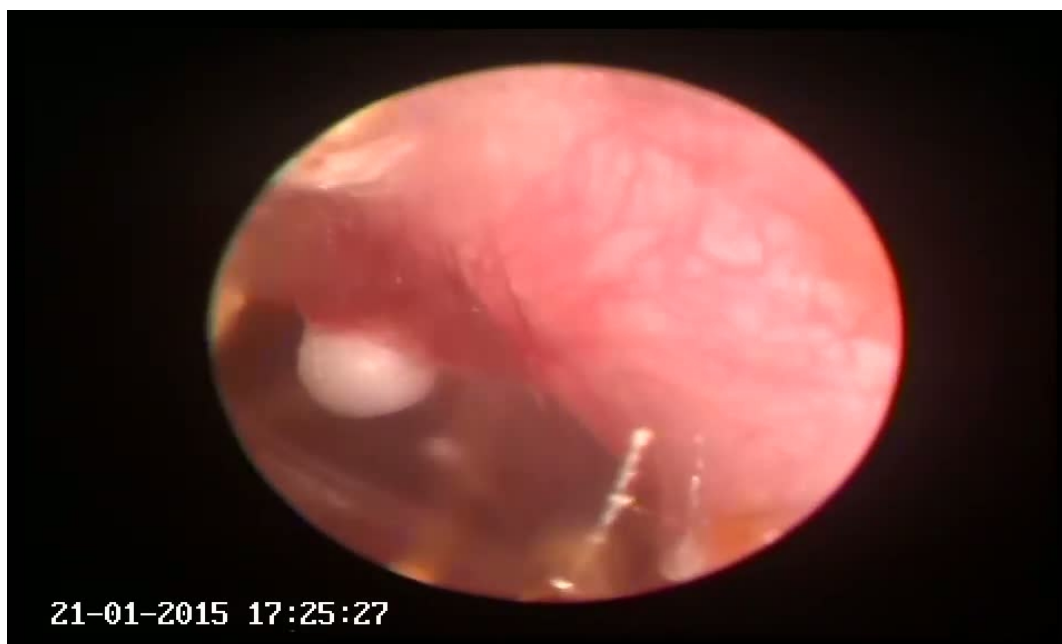

Figure 1

Otomicroscopic examination: whitish, clearly shaped, non-pulsatile mass at the posterosuperior quadrant of TM

Patient had no history of ear infection, otorrhea, trauma or ear surgery. Tympanograms were A type bilaterally. Acoustic reflexes were positive on both sides. An endaural approach surgery was performed under general anesthesia and the cholesteatoma pearl was peeled off from TM by the help of a curved peak. The pearl shaped mass involved only the outer epidermic layer of the TM without extension into the fibrous layer. After removal, fibrous layer of the TM was intact and myringoplasty was not required.

Pathological evaluation of excised material showed that specimen was 0.2 cm in diameter and it was composed of white-yellow granular material. All submitted tissue was processed. Histopathological evaluation showed that submitted tissue was composed of keratin fragments and fibrous granulation tissue. Histological features were compatible with cholesteatoma (Figure 2).

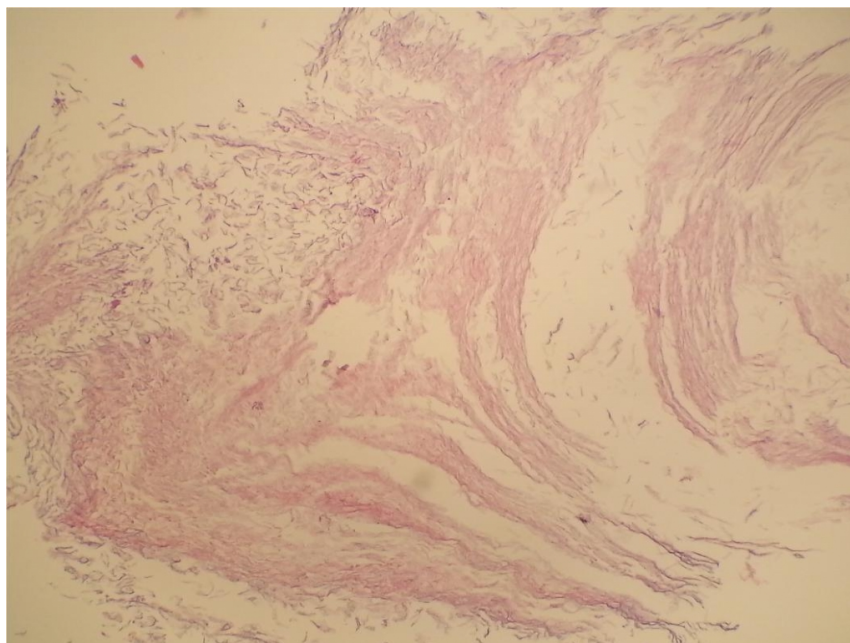


Figure 2

Histopathological evaluation of the excised tissue: keratin fragments and fibrous granulation tissue, compatible with cholesteatoma

At the 6 month follow up, otoscopic examination was normal with no recurrence. Tympanograms were type A bilaterally and patient had no complaints.

Discussion

Congenital cholesteatoma was first described by House in 1953 [9]. Unlike acquired cholesteatomas, the middle ear congenital cholesteatoma is usually identified behind an intact, normal-appearing TM. The patient often has no history of recurrent suppurative ear disease, previous otologic surgery, or TM perforation [10]. The incidence of ME congenital cholesteatoma comprises 2% to 5% of all cholesteatomas [8].

Several theories have been postulated on the pathophysiology of congenital cholesteatomas. The 'epithelial rest' theory supports persistence of an epidermoid formation (derivative of the first branchial groove) that normally regresses after 33rd week of gestation [11]. The 'metaplasia theory' postulates that inflamed middle ear mucosa transforms into stratified squamous epithelium [12]. Middle ear cholesteatomas might be explained by these theories, but TMCs can not. According to Atmaca et al [8], TMCs may best be explained by Ruedi's theory, in which he postulates that small inflammatory injuries to the TM in utero cause small perforations in the epithelium through which the basal epithelial squamous cell layer proliferates into protruding cones [13]. If these cones retain within an intact TM, TMCs could then be formed. Our case also can best be explained by Ruedi's theory since only the epithelial layer of TM is involved with spared fibrous layer.

Early diagnosis and treatment of TM congenital cholesteatoma is essential to avoid progressive destruction in the ear. A whitish spot on the TM should raise suspicion for cholesteatoma. In differential diagnosis, tympanosclerosis, foreign bodies, keratosis obliterans and cholesterol granuloma always should be kept in mind [14,15]. Especially in children, TM cholesteatoma does not initially cause hearing loss [2]. If remained untouched, they can cause several complications such as ossicular involvement and subsequent hearing conduction impairment similar to any other cholesteatoma of the middle ear. In addition, as the disease stage become advanced, the frequency of the invasion

to the epitympanum, hypotympanum, sinus tympani, facial recess, facial canal and the dura is increased [16]. In our case; early diagnosis of congenital TM cholesteatoma provided easy removal of the disease with an intact membrane remained and also avoided more invasive surgery and related complications which might have occurred in the future.

Although recurrence of TMC is less frequent than middle ear cholesteatoma [17], these lesions may also potentially involve the ossicles and middle ear [11,15]. For this reason, postoperative follow-up is essential. Our patient showed no recurrence in post-operative 4 months period.

References

1. Hinton J. Sebaceous tumor within the tympanum originating on the external surface of the membrane tympani, *Guy's Hosp. Rep.* 1863;9:264.
2. Yoshida T, Sone M, Mizuno T, Nakashima T. Intratympanic membrane congenital cholesteatoma. *International Journal of Pediatric Otorhinolaryngol.* 2009;79:1003-1005
3. Sakalli E, Kaya D, Celikyurt C, Erdurak SC. Extensive tympanic membrane cholesteatoma with marginal perforation: an unusual case. *Case Rep Otolaryngol.* 2013
4. Matsuda H, Satake K, Takahashi M, Horiuchi C, Tsukuda M. Two cases of congenital cholesteatoma of the tympanic membrane. *Indian J Otolaryngol Head Neck Surg.* 2012;64(1):79-81
5. Casale M, De Franco A, Negri M, Piazza F, Incammisa A, Salvinelli F et al. A congenital tympanic membrane cholesteatoma (CTMC) in the adult: a case report. *Eur Rev Med Pharmacol Sci.* 2012;16(5):699-700.
6. Lee BD, Park MK. Congenital cholesteatoma of the tympanic membrane. *Ear Nose Throat J.* 2011;90(12):36-7.
7. Shu MT, Lin HC, Yang CC, Chen YC. Congenital cholesteatoma in the tympanic membrane. *Ear Nose Throat J.* 2010;89(8):27.
8. Atmaca S, Seçkin E, Koyuncu M. Tympanic membrane cholesteatoma: a rare finding. *Turk J Pediatr.* 2010;52(3):309-11
9. House HP. An apparent primary cholesteatoma. A case report. *Laryngoscope* 1953;63:712-713.
10. De la Cruz A, Fayad JN. Detection and management of childhood cholesteatoma. *Pediatr Ann.* Jun 1999;28(6):370-3.
11. Michaels L. Origin of congenital cholesteatoma from a normally occurring epidermoid rest in the developing middle ear. *Int J Pediatr Otorhinolaryngol.* 1988;15:51-65
12. Sade J, Babiacki A, Pinkus G. The metaplastic and congenital origin of cholesteatoma. *Acta Otolaryngol.* 1983;96:119-129.
13. Ruedi L. Cholesteatoma formation in the middle ear in animal experiments. *Acta Otolaryngol.* 1959;50:233-242.
14. Reddy CE, Goodyear P, Ghosh S, Lesser T. Intratympanic membrane cholesteatoma: a rare incidental finding. *Eur Arch Otorhinolaryngol.* 2006;263:1061-1064.
15. Pasanisi E, Bacciu A, Vincenti V, Bacciu S. Congenital cholesteatoma of the tympanic membrane. *Int J Pediatr Otorhinolaryngol.* 2001;61:167-171
16. Park K, Park S, Chang K, Jung M, Yeo S. Congenital Middle Ear Cholesteatoma in Children; Retrospective Review of 35 Cases. *J Korean Med Sci.* 2009;24:126-31
17. Sobol SM, Reichert TJ, Faw KD, Stroud MH, Spector GJ, Ogura JH. Intramembranous and mesotympanic cholesteatomas associated with an intact tympanic membrane in children. *Ann. Otol. Rhinol. Laryngol.* 1980;89: 312-317.