

Evaluation of Fractures in Calves due to Forced Extraction during Dystocia: 27 Cases (2003-2008) ^[1]

Özgür AKSOY * 
Emine GÜNGÖR *

İsa ÖZAYDIN *
Başak KURT *

Engin KILIÇ *
Hasan ORAL **

Savaş ÖZTÜRK *

[1] A part of this study was previously presented in "XIst National Congress of Veterinary Surgery (25-28 July 2008, Kuşadası - Aydın, TURKEY)

* Department of Surgery, Faculty of Veterinary Medicine, University of Kafkas, Kars - TURKEY

** Department of Obstetrics and Gynaecology, Faculty of Veterinary Medicine, University of Kafkas, Kars - TURKEY

Makale Kodu (Article Code): 2008/100-A

Summary

This was a retrospective study evaluating fractures occurred in calves within a 6 year period (2003-2008) where dam had dystocia intervened by attending person. A total of 27 calves with fracture due to intervened dystocia were referred to the clinics within this period. The treated Fractures by using PVC bandage were located in corpus mandible in 10 cases, in metacarpus in 7 cases, in radius-ulna in 3 cases, in metatarsus in 2 cases, in tibia in 1 case and, in humerus in 1 case. Bilateral corpus mandible fractures in 8 cases were fixed by transfixation pinning and casting and these cases completely recovered. Two cases of metatarsus fracture were treated by intramedullar pinning. Three cases with metacarpus fracture, one unilateral and one bilateral open fracture cases were treated by transfixation pinning and casting with PMMA. The first case recovered but later case did not recover due to a severe infection. Two of radius-ulna fracture of three cases were subjected to PVC bandage. Recovery was obtained in femur fracture after intramedullar pinning. Supra- and inter-condylar fracture in humerus was treated by internal fixation but this case did not recover. The remaining cases (n=8) were either not eligible for treatment or data were not complete for evaluation. In conclusion, the healing based on the treatment techniques was successfully obtained in terms of the localizations, type, and open or closed condition of fracture.

Keywords: Calf, Dystocia, Fracture

Buzağılarda Güç Doğum Sırasında Hatalı Uygulamalar Sonucu Şekillenen Kırık Olgularının Değerlendirilmesi: 27 Olgu (2003-2008)

Özet

Bu retrospektif çalışmada, 6 yıllık periyotta (2003-2008) buzağılarda güç doğum sırasındaki hatalı ve/veya aşırı zorlamalar nedeniyle şekillenen kırık olguları değerlendirildi. Bu süre içerisinde kliniğimize getirilen 27 buzağıda güç doğuma bağlı kırık saptandı. Kırıklar, 10 olguda corpus mandibula, 7 olguda metacarpus, 3 olguda radius-ulna, 3 olguda femur, 2 olguda metatarsus, 1 olguda tibia ve 1 olguda humerusta lokalizeydi. Bilateral corpus mandibula kırığı olan olguların 8'inde transfixation pinning ve casting ile fiksasyon yapıldı ve tümü problemsiz iyileşti. Metatarsus kırık olgularının 2'sinde de intramedullar pin uygulamasıyla sağaltım gerçekleştirildi. Metacarpusta kırık şekillenen olguların 3'ünde sadece PVC'li bandaj ile iyileşme sağlanırken, tek taraflı açık kırık şekillenen 1 olgu ile bilateral açık kırık saptanan bir olguda transfixation pinning ve PMMA ile casting uygulandı. İlkinden olumlu sonuç alınırken diğerinde yaygın enfeksiyon nedeniyle olumlu sonuç alınamadı. Radius-ulna kırığı bulunan 3 olgunun 2'sinde PVC'li bandaj uygulamasıyla tedavi edildi. Femur kırığı bulunan olguların 1'inde intramedullar pinning uygulanarak iyileşme elde edildi. Humerusta supra ve intercondylar kırık bulunan olguda internal fixation ile sağaltım uygulandı ancak iyileşme sağlanamadı. Diğer olgularda tedavi ve sonuçları için yeterli veri oluşturulamadı veya herhangi bir sağaltım uygulanmadı. Sonuç olarak, kırığın şekillendiği bölge, kırık tipi ve açık-kapalı oluşuna göre uygulanan sağaltım teknikleriyle yüksek oranlarda iyileşme sağlanmıştır.

Anahtar sözcükler: Buzağı, Güç doğum, Kırık



İletişim (Correspondence)



+90 474 2426807/1277



drozgraksoy@hotmail.com

INTRODUCTION

The current studies of genetic improvement for high meat and milk production in cattle has a potential to cause a relative discordancy between dam and foetus, and this leads to increase the dystocia problems. Generally, inappropriate manipulation or manual and mechanical forces by owners and sometimes veterinarians to help parturition cause traumatic disorders in muscle, bone and joint, and nerve and other soft tissues which may often lead to dying of foetus during parturition or postnatal period. In some cases, dam also could be damaged in various grades.

It has been reported that the incidence of dystocia varies due to some factors such as age of mother, breed of animal, sex of fetus, nutrition, environmental and climate conditions, and the presentation or position of foetus ¹

During excessive and forced traction process, the trauma caused by using material during dystocia and/or inappropriate forced extraction lead to fractures and dislocations with various soft tissue lesions (the destroying of muscle, nerve and vessel) ¹ in firstly metacarpus/metatarsus ^{2,3}, mandible ⁴⁻⁶, femur ^{3,7}, tibia ^{2,3}, radius-ulna ^{2,3,8}, humerus ³ and ribs ^{9,10}.

In order to define treatment choice, it should be considered the type, localization and condition of fracture (open or closed), the economical value of animal, cost of treatment and required care conditions in healing period ³.

In farm animals, the bandaging technique supported with some materials such as Polyvinylchloride (PVC) and aluminum and the splinting such as Thomas Splint alone or combined with bandage have been frequently used as a treatment choice for external reduction of closed fractures ^{2,3,11-15}.

The transfixation pinning and casting methods are also used especially in the reduction and fixation of fractures of metacarpus/metatarsus, tibia and radius-ulna ^{2,8,12,13,16}. The internal fixation techniques applied by using some materials such as intramedullar pinning, cerclage wiring, screw, dynamic compression plate (DCP), interlocking pin are recommended particularly in reduction of the dislocated, fragmented and complicated fractures (with pieces) or in the fractures established in bones not suitable for bandaging or splinting ^{2,13,17,18}.

This retrospective study evaluated the types,

localizations and treatment techniques of fractures in calves occurred by the inappropriate forced extraction during dystocia in six-year period (2003-2008).

MATERIAL and METHODS

Twenty seven calves with fractures occurred during the inappropriate manipulations of dystocia were used in the study. These calves with various breed, age and sex were received to Kafkas University, Veterinary Faculty Surgery Clinics in the period of 2003-2008. The information based on the anamnesis obtained from the owners about the manipulations during dystocia was recorded. The types and localizations of the fractures were determined by physical and radiographic examination.

Seventeen cases of fractures encountered in extremities were treated by using the methods of the closed reduction with PVC bandage in five cases, the internal fixation (with intramedullar pin, screw, cerclage wire) in four cases, and the transfixation pinning and casting in two cases. Eight cases of bilateral mandible fracture were treated by transfixation pinning and fiberglass casting. The other fractures (six cases with extremities and two cases with mandible) were not evaluated because of unsuitability for treatment and/or obtaining insufficient data about the cases. While bandage applications were realized under sedation, the surgery for fractures of mandible and forelimbs were carried out under general anesthesia and the surgery in the hindlimbs were applied under general or spinal anesthesia.

The closed reduction with PVC bandage and internal fixations (using by cerclage wire, pin and screw) were applied by routine techniques in extremities. For transfixation pinning, two pins were replaced to both proximal and distal fragment of the fractured bone transversally and the pins were fixed by polymethyl metacrylate (PMMA). In the fracture of corpus mandible, three pins were replaced transversally into oral (two pins) and aboral (one pin) parts of fracture fragments and the reduction and stabilization were obtained by fiberglass casting.

The post-treatment period was followed by receiving the patents to the clinic, calling the owners to get the feed-backs, or visiting to patients based on the stage of cases.

In the cases treated by transfixation pinning, the pins were removed at the 5th-6th weeks after surgery based on the radiological findings.

Table 1. Animals and localization and type of fractures**Tablo 1.** Olgular ve bunlarda saptanan kırıkların tip ve lokalizasyonu

Case No	Animal			Localization and Type of Fracture
	Breed	Sex	Age (Day)	
1	Simmental	Female	1	Corpus mandible, bilateral, oblique, open
2	Simmental	Male	7	Metacarpus, distal diaphyseal, oblique, open
3	Swiss Brown	Female	1	Metatarsus, distal diaphyseal, oblique, closed
4	Swiss Brown	Male	4	Metatcarpus, distal diaphyseal, oblique, closed
5	Local	Female	1	Corpus mandible, bilateral, oblique, open
6	Mixed	Female	1	Corpus mandible, bilateral, oblique, open
7	Simmental	Male	1	Metatarsus, distal diaphyseal, oblique, closed
8	Swiss Brown	Male	20	Corpus mandible, bilateral, oblique, open
9	Simmental	Male	1	Metacarpus, distal diaphyseal, oblique, open bilateral
10	Swiss Brown	Male	20	Corpus mandible, bilateral, oblique, open
11	Simmental	Male	1	Metatcarpus, distal diaphyseal, oblique, closed
12	Simmental	Male	1	Metatcarpus, distal diaphyseal, oblique, closed
13	Swiss Brown	Female	30	Metatcarpus, distal diaphyseal, oblique, closed
14	Simmental	Male	3	Metatcarpus, distal diaphyseal, oblique, closed
15	Simmental	Male	3	Radius-ulna, distal diaphyseal, oblique, closed
16	Local	Male	1	Femur, middle diaphyseal, fragmented, closed
17	Swiss Brown	Female	1	Corpus mandible, bilateral, oblique, open
18	Swiss Brown	Male	12	Tibia, proximal diaphyseal, closed
19	Simmental	Male	5	Radius-ulna, distal diaphyseal, oblique, closed
20	Simmental	Male	2	Corpus mandible, bilateral, oblique, open
21	Swiss Brown	Male	10	Radius-ulna, distal diaphyseal, ulna-transversal, radius-oblik, closed
22	Simmental	Male	3	Humerus, inter- and supra-condyler, closed
23	Swiss Brown	Male	3	Corpus mandible, bilateral, oblique, open
24	Simmental	Female	2	Corpus mandible, bilateral, oblique, open
25	Simmental	Male	21	Corpus mandible, bilateral, oblique, open
26	Simmental	Male	2	Femur, distal diaphyseal, transversal, closed
27	Simmental	Female	10	Femur, distal diaphyseal, oblique, closed

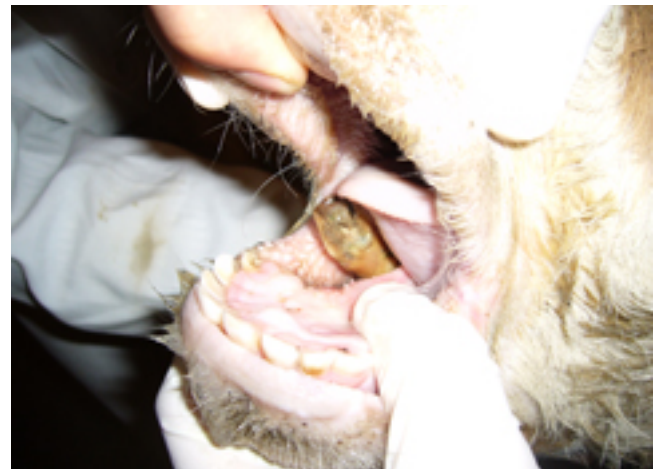RESULTS

Among 511 calves brought the clinic during the study period, 45 (%8.8) of fractures were observed by various reasons and 27 out of these 45 cases (60%) with fractures of different types and localizations were caused by inappropriate manipulations for dystocia. These 27 cases correspond to 5.4% of total calves received to the surgery clinic. The ages of calves were varied in 1-30 days; however, the majority of them were 1-3 day-old. The distribution of bred, sex and age of the calves are shown in *Table 1*.

Based on the anamnesis obtained from owners, the fractures were formed depending on the position and presentation of foetus after the owners forced the foetus by tying on metacarpal/metatarsal region with a rope or chain by extraction with hand, other animal forces, or tractor. It was also recognized that all of the mandible fractures were formed during the forced extraction by veterinarians during replacing a chain to margo interalveolaris of foetus.

All of the mandible fractures (n=10) localized in

margo interalveolaris were formed in bilateral as an oblique open fracture. One of these was not treated since it was brought to the clinic after three weeks of parturition and the necrosis was seen in mandible (*Figure 1*). Another case was not evaluated in terms of treatment and results. The remained 8 cases were

**Fig 1.** Bilateral open fracture in the corpus mandibula (necrosis)**Şekil 1.** Corpus mandibulada bilateral açık kırık (nekroz)

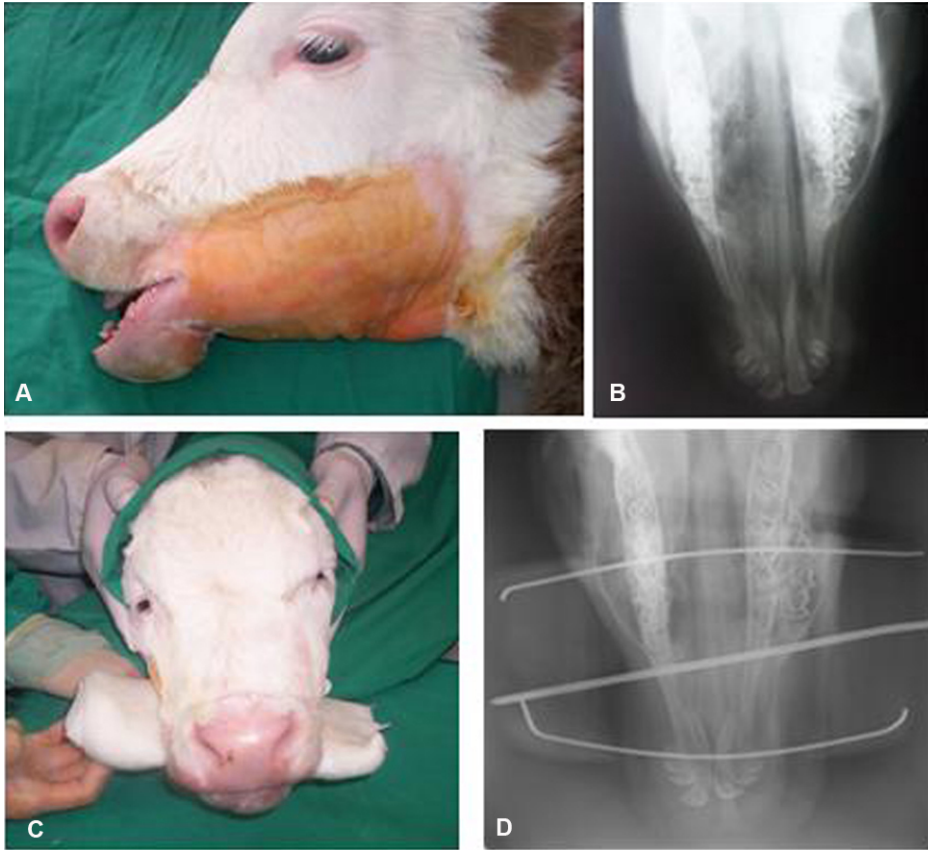
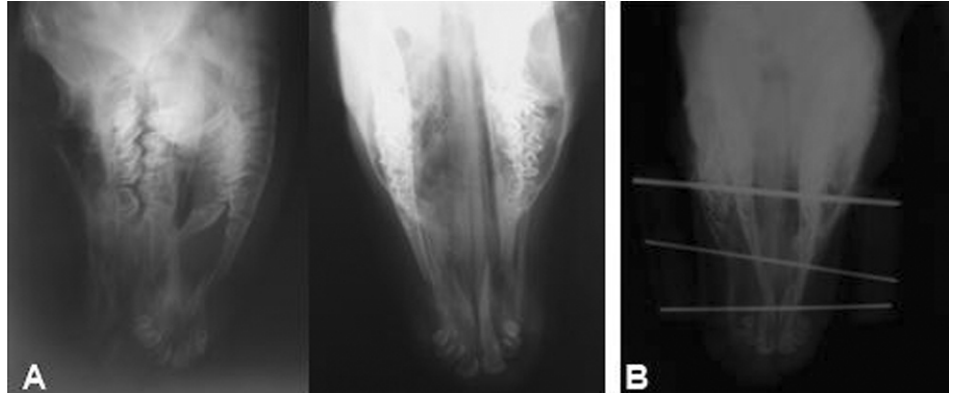


Fig 2. The fracture in the corpus mandibula. Clinical view (A), Radiographic image before surgery (B), Post-operative clinical view (C), Post-operative radiographic image (D)

Şekil 2. Corpus mandibula kırığı A- Klinik görünüm, B- Operasyon öncesi radyografik görünüm, C- Postoperatif klinik görünüm, D- Postoperatif radyografik görünüm

Fig 3. The fracture in the corpus mandibula. Radiographic images before (A) and after (B) the surgery

Şekil 3. Corpus mandibula kırığı A- Operasyon öncesi radyografik görünüm, B- Postoperatif radyografik görünüm



recovered by transfixation pinning and fiberglass casting techniques (*Figures 2 and 3*) without any complication. It was observed that all of these patients started sucking their mothers within 8-12 hours and taking their food without a help.

Six and one of metacarpus fractures formed as unilaterally and bilaterally in distal diaphyseal region of the bone, respectively. Five and two of them were oblique and transversal fracture, respectively. One bilateral and one unilateral open fractures observed in two cases were operated by transfixation pinning and PMMA casting methods. The unilateral fracture was recovered; however, the other animal was sent

to slaughterhouse because of a severe infection. While three cases of closed fracture were recovered by PVC bandage, the other two cases was not considered.

While two cases of metatarsus fracture formed in distal diaphyseal oblique fracture and one cases of femur with middle diaphyseal fragmented fracture were recovered by using intramedullary pinning, one of cases with supra- and inter-condylar humerus fracture was treated by intramedullar pin and screw fixation; however, it was not recovered due to early screw loosening and pin migration. One case with proximal diaphyseal tibia fracture was not evaluated based on the treatment and results.

All of the radius-ulna fractures (n=3) were localized in distal diaphysis. While the oblique fractures were observed in both bones of two cases, the oblique and transversal fractures were observed in radius and ulna in the other case, respectively. Two cases of these were treated by PVC bandaging and the remaining case was not evaluated.

DISCUSSION

In Turkey as well as many other countries, the meat and milk consuming has been obtained from small and large ruminants. Various improvement studies and genetic advances have been performed in order to get more productivity and yield by a lesser of management expenses and work. As a result of this condition, a remarkable increase of pure and crossbred cattle population compared with local breeds has been recently observed in Northeastern Anatolia especially within last 15-20 years. Consequently, this has caused to increase the incidence in losses (foetal death, traumatic conditions due to dystocia, predisposition to infections of calves and cows in postnatal and postpartal periods, etc.).

The incidence of dystocia is observed related with fetus and dam with higher frequency in beef cattle than that of in milk cattle. There are many reasons of dystocia such as inertial uterus, torsio uteri, relative narrowness of pelvic structure, insufficient widening in soft and hard structures of birth canal and disorders of presentation - position of foetus. In addition, the difference of breed between dam and foetus, nutrition, management conditions, climate conditions, the condition score of dam, sex of foetus (male foetus are more prone than females), twiness, the disorders of presentation and position of foetus also potentially cause dystocia ¹. The most of calves brought to our clinics were male and Simmental breed. As described above, this may be related to the combination of predisposition and causative factors (the predisposition of sex and breed, nourishment, nutrition and climate conditions etc.).

Görgül et al.³ reported that the incidence of the disorders of extremities in surgical disorders were 13.8% and 80.6% were caused by inappropriate manipulations during helping for birth in calves brought to the Surgery Clinics of Uludağ University, Veterinary Faculty, within a period of 8 years (1996-2003). In the present study of the calves brought to our clinics within a period of 6 years (2003-2008), the

rate of fractures cases in surgical disease was 8.8% and 60% of these (5.4% of all the calves) were caused by similar inappropriate manipulations during helping for birth in dystocia. It may be suggested that these data are not enough to reflect the current rates of the Kars Province because the most of calves in our clinics were brought from surrounding villages only. If the number cases of died calves during birth or after birth and the calves treated or non-treated by veterinarians are added to these rates, it can be concluded that the mentioned problems are significant problem of this region.

The rope or chain tied to extremities for traction of foetus causes to open or close fractures associated with soft tissues damages depending on presentation or position of foetus ^{2,3,8}. In some cases, more proximal bones may also be affected during this force. In addition, the excessive tractions also lead to the thoracal trauma in case of difficulties/impossibilities during the passing of fetus in birth canal ^{9,10}. As the material using for traction of foetus usually replaces on the metacarpal/metatarsal region, most of fractures during birth can be formed especially in these regions. Similarly, it has been reported that most of fractures (n=9) were observed in these regions in the present study. In addition, it was observed that open or closed fractures with accompanied with various soft tissue damage in the cases of the metacarpal/metatarsal fractures. It is importantly noticed that all of these cases had distal diaphyseal fractures and these findings agrees with the other references which explain that the fractures are caused by trauma occurred with the rope or chain to the region during traction of foetus ^{2,3}. It may be concluded that the other fractures were formed due to inappropriate biomechanical tractions (the application of traction in unsuitable angles).

It has been shown that the mandible fractures are rarely seen and especially presented as a case report ^{5,6}. In contrast, the rate of bilateral corpus mandibula fractures in our present report were 10 of 27 cases. Unfortunately, it was seen that some veterinarians had applied for mandibular traction in foetus for birth aid.

Various techniques for treatment of extremity fractures are recommended by surgeons as depending on some factors such as type and localisation of fracture, type and severe of trauma, choice of treatment, genetical value of animal, cost of treatment and the conditions of management. It was reported that highly successful results have been obtained in the calves treated with techniques of bandage and splint ^{2,3,11-15}, transfixation

pinning and PMMA cast ^{2,8,12,13,16}, internal fixation ^{2,13,17,18}. In the present study, following the 10 of 17 cases with extremity fracture were appropriately treated by a suitable techniques mentioned above, all the patients were recovered except for two patients. Also, the 8 of 10 cases with mandible fracture were successfully treated by transfixation pinning and fiber-glass cast.

In conclusion, it is understood that one of the most critical problems among surgical disorders in calves are fractures associated with other traumatic disorders formed during obstetrical processes. The etiology of these is contained by empirical methods by the owners and inappropriate manipulations of veterinarians without caring of biomechanical criteria during extraction force. It is suggested that the veterinarians should use appropriate techniques and avoid the owners of animal interfere unless necessary and not try to treat of fractures by empirical methods to reduce the economical losses. The caring attention to important criteria for helping of birth by veterinarians and owners of animal will contribute to decrease of economical losses. It should be remarkably noticed that the maintenance of profitability of an animal husbandry and management depend on the obtaining one calve per dam and continuation of regular profit for every year. Additionally, the appropriate applications and false treatments give very strong damage to foetus beside dam, cause predispositions for obstetrical and gynecological problems, and sometimes lead to complete infertility. The treatment of calves with fracture should be considered as a valuable profit to tolerate the economical waste in the calves having a value of high genetics. Because every untreated and lost calve create an additional costing to farm for another year. It must be considered that if an opportunity intercepts to treat in accurate time, the treatment methods can be more successful. Furthermore, under the light of results of this study, it is necessary that the informing and education of farmers regularly and continuously by faculties, civilian associations, ministry and field veterinarians.

REFERENCES

- Noakes DE:** Dystocia and Other Disorders Associated with Parturition. In, Noakes DE, Parkinson TJ, England GCW (Eds): Arthur's Veterinary Reproduction and Obstetrics. 8th ed. WB Saunders Co, Philadelphia, pp. 205-338, 2002.
- Steiner A:** Management of metacarpal, metatarsal, radial and tibial fractures in calves. *Nineth Annual ESVOT Congress*, 16-19 April, Munich - Germany, 1998.
- Görgül OS, Seyrek-İntaş D, Çelimli N, Çeçen G, Salcı H, Akın İ:** Buzağılarda kırık olgularının değerlendirilmesi: 31 Olgu (1996-2003). *Veteriner Cerrahi Dergisi*, 10 (3-4): 16-20, 2004.
- Trent AM, Ferguson JG:** Bovine mandibular fractures. *Can Vet J*, 26, 396-399, 1985.
- Singh KB:** Surgical repair of bilateral mandibular fracture in a buffalo calf. *Indian Vet J*, 74, 63-64, 1997.
- Yadav GU, Markandeya NM, Bhikane AU, Kale SB:** Management of mandibular fracture in a new born calf- A case report. *Indian Vet J*, 80, 1287, 2003.
- Ferguson JG, Dehghani, Petrali EH:** Fractures of the femur in newborn calves. *Can Vet J*, 31, 289-291, 1990.
- St-Jean G, Debowes RM:** Transfixation pinning and casting of radial-ulnar fractures in calves: A review of three cases. *Can Vet J*, 33, 257-262, 1992.
- Schuh JoAnn CL:** A retrospective study of dystocia-related vertebral fractures in neonatal calves. *Can Vet J*, 29, 830-833, 1988.
- Çeçen G, Görgül OS:** Holstein ırkı buzağıda bilateral kosta kırığı ve akciğer yaralanması. *Veteriner Cerrahi Dergisi*, 12 (1,2,34): 107-108, 2006.
- Görgül OS, Yanık K:** Koaptasyon ve destek materyali olarak Polivinylidyn chloride (PVC) atellerin kullanımı üzerine klinik çalışmalar. *Ankara Üniv Vet Fak Derg*, 29 (3-4): 401-405, 1982.
- St-Jean G, Debowes RM:** Transfixation pinning and casting of tibial fractures in calves: Five cases (1985-1989). *JAVMA*, 198 (1): 139-143, 1991.
- Newman KD, Anderson DE:** Fracture management in llamas and alpacas. *Small Rum Res*, 61, 241-258, 2006.
- Latrach R, Segard E, Frikha MR:** Cas clinique: Traitement d'une fracture du tibia chez un veau par un pansement Robert-jones associe'a des atelles. *Revue Med Vet*, 158 (7): 354-361, 2007.
- Gangl M, Grulke S, Sertejn D, Touati K:** Retrospective study of 99 cases of bone fractures in cattle treated by external coaptation or confinement. *Vet Rec*, 158, 264-268, 2006.
- Anderson DE, St-Jean G:** Repair of fractures of the radius and ulna in an ewe using positive profile transfixation pins and casting. *Can Vet J*, 34, 686-688, 1993.
- Aslanbey D, Sağlam M, Kaya A, Bilgili H:** Bir buzağıda distal diafizler parçalı metacarpus kırığının DCP plak kullanılarak sağaltımı. *Veteriner Cerrahi Dergisi*, 3 (1): 40-43, 1997.
- Thilagar S, Ganesh TN, George RS, Kumaresan A:** Management of comminuted fracture of metatarsus using dynamic compression plate and position screw in a calf. *Indian Vet J*, 82, 195-197, 2005.