



PIRFENIDONE ATTENUE EPIDURAL FIBROSIS IN RATS BY SUPPRESSING TNF- α , IL-1, AND α -SMA

Yahya GÜVENÇ¹,
Deniz BILLUR²,
Pınar BAYRAM³,
Yaşar ÖZTÜRK⁴,
Mesut Emre YAMAN⁵,
Sevim AYDIN²,
Erkan KAPTANOĞLU¹

¹ Marmara University, School of Medicine, Department of Neurosurgery, İstanbul, Turkey

² Department of Histology and Embryology, Ankara University School of Medicine, Ankara, Turkey.

³ Kafkas University School of Medicine, Department of Histology and Embryology, Kars, Turkey

⁴ Yenimahalle Training and Research Hospital, Department of Neurosurgery, Ankara, Turkey

⁵ Gazi University, School of Medicine, Department of Neurosurgery, Ankara, Turkey

ORCID Numbers:

Yahya GUVENC:
0000-0002-4813-0854
Deniz BILLUR:
0000-0001-8541-8251
Pınar BAYRAM:
0000-0001-9924-7051
Yaşar ÖZTÜRK:
0000-0003-0923-5941
Mesut Emre YAMAN:
0000-0003-0049-1316
Sevim AYDIN:
0000-0003-2445-2346
Erkan KAPTANOĞLU:
0000-0002-9945-8817

Address: Yahya Güvenç,
Marmara University, School of Medicine,
Department of Neurosurgery, Basıbuyuk
Healt Campus, Maltepe, İstanbul, Turkey.
Phone: +90 505 899 46 39
E-Mail: dr.yahyaguvenc@gmail.com
Received: 24th January, 2018.
Accepted: 16th May, 2018.

ABSTRACT

Aim: Postlaminectomy epidural fibrosis is implicated as a main case of failed back surgery syndrome and associated with increased risk of complications during revision surgery. Various materials or drugs have been used to inhibit formation of epidural fibrosis and reduce the compressive effect on neural structures. Nevertheless, the effects are not satisfied.

Pirfenidone is a broad-spectrum anti-inflammatory and anti-fibrotic molecule that has been shown to inhibit the fibrosis progression in patients with idiopathic pulmonary fibrosis and animal models. Anti-fibrotic mechanism of pirfenidone is associated with antagonism of activities mediated by TNF- α and TGF-B. In present study, pirfenidone was studied to investigate its anti-fibrotic effects on reducing epidural fibrosis after laminectomy in a rat model.

Methods: Thirty two Wistar albino rats were divided randomly into four equal groups: control spongostan, systemic pirfenidone and local pirfenidone groups. In all groups, total L3-L5 laminectomy was performed. At 4 weeks postsurgery, the animals euthanized and their tissue samples at the laminectomy site were assessed both immunohistochemistry of anti-IL-1, anti- TNF- α and anti- α -SMA antibodies on epidural fibrosis of animal groups and histological evaluation for; dura thickness, epidural fibrosis grading, scar tissue consistency and inflammatory response grading and presence of arachnoid involvement. All data was evaluated by statistically.

Results: Our data suggests that rats treated with pirfenidone at 4 weeks post-laminectomy had less , dura thickness, epidural fibrosis, scar tissue consistency and inflammatory response and arachnoid involvement in comparison with the control and spongostan groups. Pirfenidone treated groups show weaker labeling for anti-IL-1, anti- TNF- α and anti- α -SMA antibodies than control and spongostan groups. Moreover, the local applicaton of pirfenidone had shown better results than systemic administration for all parameters.

Conclusion: The results of our study suggested that pirfenidone has anti-fibrotic effects on epidural fibrosis, its effectiveness especially increased when it is used locally.

Keywords: Laminectomy, epidural fibrosis, pirfenidone, immunohistochemistry IL-1, TNF- α , α -SMA

Level of Evidence: Experimental animal study, Level-II

INTRODUCTION

Laminectomy for treating spinal disorders often results in formation epidural fibrosis and it can lead to failed back surgery syndrome and persistent back and leg pain ⁽²³⁾. Epidural hematoma, epidural fat accumulation and muscle invasion induce fibroblasts activity thus,

formation of epidural fibrosis occur at the laminectomy site after operation⁽²¹⁾. Surgical methods and biological, non-biological materials for the prevention of epidural fibrosis have been studied however clearly results has not been obtained from this studies. Preventing EF formation is considered the best approach to manage this problem.

During the last decades, studies have been focus on inflammatory process and fibroblast apoptosis.

Pirfenidone (PFD) (5-methyl-1-phenyl-2-[1H]-pyridone) has both anti-inflammatory and antifibrotic effects, acting through the regulation of tumor necrosis factor (TNF- α) and (TNF- β) pathways⁽¹⁷⁾. Some studies have shown that pirfenidone inhibits proliferation and activation of fibroblasts so it inhibit the pathogenesis of fibrosis^(9,13,22). Pirfenidone has been used treatment of idiopathic pulmonary fibrosis in some country. It's efficacy has been showed for Crohn's disease and intestinal fibrosis on the experimental studies^(12,14).

In present study, pirfenidone was studied to investigate its anti-fibrotic effects on reducing epidural fibrosis after laminectomy in a rat model.

MATERIAL AND METHODS

Animals

Adult, male, 32 Wistar Albino rats (mean weight = 280g) were used for this study. The experimental part of the study was conducted at the Ankara Training and Research Hospital laboratory after obtaining consent from the Ankara Training and Research Hospital Animal Experiments Local Ethics Committee. All subjects were kept under stable and standard environmental conditions during the experiment and were fed on standard animal food and water.

Operative procedure

Each animal underwent an laminectomy. Surgery was conducted with the animals under general anesthesia using xylazine (10 mg/kg, Rompun, Bayer, Turkey) and ketamine hydrochloride (50 mg/kg, Ketalar, Parke Davis, Turkey) administered intraperitoneal. Rats were placed in the prone position. The lumbar area of the rat was shaved. The surgical field was then prepared in a sterile manner using povidone-iodine solution. The surgical site was then draped in a standard fashion. All of the operative procedures were performed carefully using a surgical microscope (Zeiss OPMI- Carl Zeiss Meditec Company, Oberkochen, Germany) by the same surgeon (YG) . A longitudinal mid-line skin incision was made over the L3-L5 levels and carried down to the spinous process. The L5 lamina was identified by counting up from the sacrum.

The lumbosacral fascia was then incised and the paraspinal muscles were subperiosteally detached to expose laminae. At the L3-L5 level total laminectomy was performed. The ligamentum flavum and epidural fat were removed. The dura mater was fully exposed and the hemostasis was obtained by using cotton sheet. The laminectomy site were treated with different agents. In control and

systemic drug administration groups, only laminectomy was carried out. Following that, the dorsal spinous fascia was reposed using absorbable suture, whereas the wounds were closed in anatomical layers using the same suture material (prolen polypropylene sutures, Ethicon, Ethicon endo – surgery, Inc., Cincinnati, OH, USA). There were no complication, wound infections or ant adverse effect s observed relevant to pirfenidone. The animals were euthanized on the 4 weeks post operative day using a lethal dose of pentobarbital (60 mg/kg, IE. Ulagay, Istanbul, Turkey).

Experimental Groups

All rats were randomly divided into four groups. Control group (n=8): only laminectomy was performed without treatment; Spongostan group (n=8): a spongostan (Ethicon Endo-Surgery, Inc.) soaked with 2cc/kg saline solution and was left on the dura mater after laminectomy. Systemic (S) Pirfenidone group (n=8): Pirfenidone was given 25 mg/kg/d via oral gavage. Local (L) Pirfenidone group (n=8): 25 mg/kg/d pirfenidone was locally applied with a spongostan soaked with 0,5 ml of the solution and was left on the dura mater.

Tissue processing

The tissue samples at the laminectomy site were harvested after the rats were euthanized. Specimens were fixed in phosphate buffered 10% formalin for one week. Then tissue washed in tap water and decalcified in 25% formic acid for 3 days. Tissue were then washed in tap water and this was followed by dehydration; immersion in 70%, 80%, 90% and 100% ethanol. After dehydration tissues were cleared in xylene and embedded in paraffin wax.

Histological analysis

- Light Microscopic Evaluations

Sections were cut in 5 μ m thickness using a microtome (Leica RM 2125RT) and stained with Masson's trichrome. Slides were examined and photographed using an Axio Scope-A1 (Carl Zeiss, Germany) microscope at x100 magnification. All sections were evaluated in a blinded manner by the same histologist, who analyzed dura thickness, epidural fibrosis, arachnoid involvement, scar tissue consistency and inflammatory response

Dura thickness were measured using the Axiovision software program at the three predetermined segments that previously described by Cemil et al⁽⁴⁾. Epidural fibrosis was graded according to the method of He *et al*⁽⁸⁾ (Table-1).

The scar tissue consistency and inflammatory response were graded using the scoring system proposed by Miyamoto *et al*¹⁵. These researchers used a 4-point scoring system (Table -2).

Involvement of the arachnoid layer with the presence of arachnoidal adhesions to the dura mater was also noted.

Table-1. Epidural fibrosis grading table.

Grade	Explanation
0	Dura mater was free of scar tissue
1	Only thin fibrosis bands between the scar tissues and the dura mater were observed.
2	Continuous adhesion was observed but made up less than two-thirds of the laminectomy defect
3	Scar adhesion was large and involved more than two-thirds of the laminectomy defect, and/or extended to the nerve roots.

Table-2. Scar tissue consistency and inflammatory response grading table.

Grade	Explanation
0	loose connective tissue with small collagen bundles, the presence of highly vascular adipose tissue, with moderate macrophage and inflammatory cell activity
1	connective tissue density, edges of defect with evidence of new bone formation, and mild macrophage and inflammatory cell activity.
2	dense connective tissue and/or fibrocartilage, absence of adipose tissue, avascular tissue, and absence of macrophage and inflammatory cell activity
3	dense collagenous connective tissue, absence of adipose tissue, avascular tissue, and absence of macrophage and inflammatory cell activity

Immunohistochemistry

For immunohistochemistry analysis, sections were deparaffinized and rehydrated by using xylen and a graded series of ethanol, followed by 5 min washes in phosphate buffered saline (PBS). Antigen retrieval was performed in trypsin at 37°C for 30 min and washed in PBS for 3x5 min. Afterwards, the sections were incubated for 15 min in 1% H₂O₂ in methanol to block endogenous peroxidase activity, washed in PBS for 3x5 min, blocked at room temperature for 30 min by using blocking solution (Histostain Plus Kit, 85-9043, USA) and incubated in a humidified chamber 1 h at 37°C with the primary antibodies anti - α -SMA (1:200;A5228 mouse monoclonal,Sigma Aldrich), Anti-IL-1 β (1:200, SC-7884 rabbit polyclonal,Santa Cruze), anti TNF- α (1:200, SC-1350, goat polyclonal, Santa Cruz). Sections were washed in PBS (3x5 min) and incubated at room temperature for 1 h with the biotinylated

secondary antibodies (for anti- α -SMA and Anti-IL-1 β ; Histostain Plus Kit, 85-9043, USA, and for TNF- α ; Vector Laboratories BA-5000). After a wash with PBS (3x5 min), the sections were incubated with ready-to-use streptavidin peroxidase at room temperature for 30 min and well rinsed with PBS. Colors were developed with a DAB kit. The sections were then counterstained with hematoxylin, dehydrated, and mounted. Negative controls were prepared by substituting PBS for the primary antibodies.

H-Score

The evaluation of the immunohistochemical labeling of IL-1, TNF- α and α -SMA in samples from experimental and control groups was performed using H-SCORE². Briefly, sections were evaluated using an Axioscope microscope (Zeiss, Oberkochen, Germany). Three randomly selected slides, each of five different fields at 200 x magnification, were evaluated for immunohistochemical labeling of IL-1, TNF- α and α -SMA. The labeling was scored in a semi quantitative fashion that included the intensity of specific labeling in sections. The evaluations were recorded as percentages of labeled cells of all types in each of four intensity categories, denoted as 0 (no labeling), 1+ (weak labeling but detectable above control), 2+ (distinct labeling) and 3+ (intense labeling). For each tissue, an H-SCORE value was derived by summing the percentages of cells that were labeled at each intensity multiplied by the weighted intensity of the labeling: $H-SCORE = \sum P_i(i+1)$, where “i” is the intensity score and P_i is the corresponding percentage of the cells. Two observers blinded to the experimental groups performed the H-SCORE evaluations, and the average score was used.

Statistical analysis

All data were analyzed using SPSS for Windows version 11,5 (SPSS Inc.,Chicago, IL, USA) and statistically significant values were defined as $p < 0,05$. The data for dura thickness and H-score were reported as the mean \pm standard deviation (SD). Differences between groups were calculated by the analysis of variance (one-way ANOVA) and Bonferroni post hoc test.

A Fisher’s exact test was used to determine significant difference in grades of epidural fibrosis, scar tissue consistency and inflammatory response as well as the presence of arachnoid involvement.

RESULTS

The mean thickness of the dura mater was different in four groups ($F(3,28) = 13,789$ $p < 0,001$). In control group, the mean thickness of the dura mater was found to be higher than the other three groups (respectively,

$p<0,001$, $p<0,001$, $p<0,05$), however the difference between the spongostan and S.Pirfenidone group were not significant ($p>0,05$). The mean thickness of the dura mater for L.Pirfenidone was significantly lower than the other three group's (respectively, $p<0.001$, $p<0.05$ ve $p<0.05$).

There was a significant difference between the distribution of groups in to epidural fibrosis grade categories ($p=0.028$). Control group was mainly accumulated in grade 2 and 3. There was mostly grade 1 in L.Pirfenidone group. (Fig 1, Table 3).

The scar tissue consistency and inflammatory response grades in pirfenidone treatment groups were lower than control and spongostan groups. All of the rats In L. pirfenidone group were grade 1 ($p<0.001$) (Table-3).

Arachnoidal involvement was observed in 62.5% of the rats in the control group, 37.5% of the rats in the Spongostan group, 25% of the rats in S.Pirfenidone group and the was no arachnoidal involvement in L.pirfenidone group. The difference between the groups was slightly non-significant ($p=0,064$).

The mean of the H-score for IL-1 was different in four groups ($F(3,28)= 25,651$ $p<0,001$). In the control group, the mean of the H-score was statistically significantly higher than the other three groups (respectively $p<0,01$, $p<0,001$, $p<0,001$). There was no difference between spongostan and S.pirfenidone groups ($p>0,05$). However L. Pirfenidone group was significantly lower than spongostan group ($p<0,01$). When S.pirfenidone and L. Pirfenidone group was compared, the difference was slightly non-significant. ($p=0.055$) (Fig 2-3, Table 3).

The mean of the H-score for TNF- α was different in four groups ($F(3,28)=9,508$ $p<0,001$). There was no significant difference between Control, Spongostan and S.Pirfenidone groups ($p>0,05$ for all). The mean of the H-score for TNF- α was significantly lower in L.Pirfenidone group than the control and spongostan groups (respectively $p<0,01$, $p<0.01$). There was no significant difference between L.Pirfenidone and S.Pirfenidone groups ($p>0,05$) (Fig 2-3, Table-3).

The mean of the H-score for α -SMA was different in four groups ($F(3,28)= 42,092$ $p<0,001$). There was no difference between control and spongostan groups and means of both groups were significantly higher than the S.Pirfenidone and L.Pirfenidone groups ($p<0,001$ for all). There was no difference between S.Pirfenidone and L. Pirfenidone groups. ($p>0,05$) (Fig 2-3, Table-3).

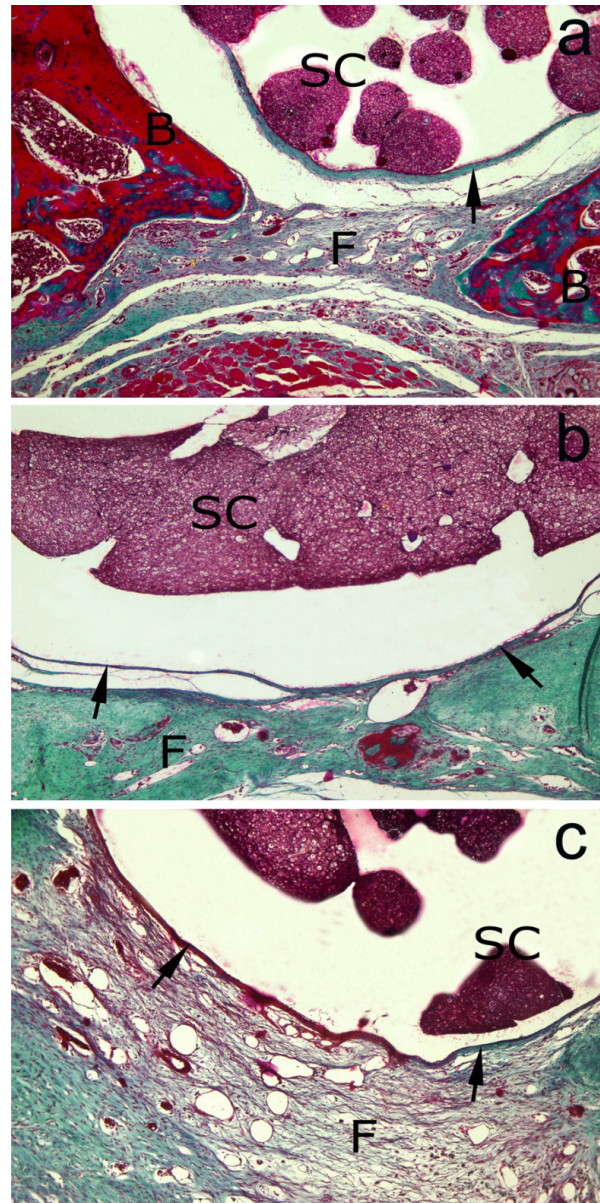


Figure-1. Representative micrograph of the rat dural tube and epidural fibrosis 4 weeks following laminectomy. **a)** Grade-1 epidural fibrosis is observed in pirfenidone treatment groups. Dura mater is free and Only thin fibrous band (arrow) is observed between the fibrosis (F) and the dura. B: new bone formation. **b)** Grade-2 epidural fibrosis in spongostan group. Fibrosis that dense connective tissue covered less than two-thirds of the laminectomy defect and adhere to the dura mater (arrow). **c)** Grade 3 epidural fibrosis is observed in control group. Epidural fibrosis (F) that highly vascular loose connective tissue covered more than two-thirds of the laminectomy defect and adhered to dura mater (arrow). SC: spinal cord. Masson's trichrome x 100

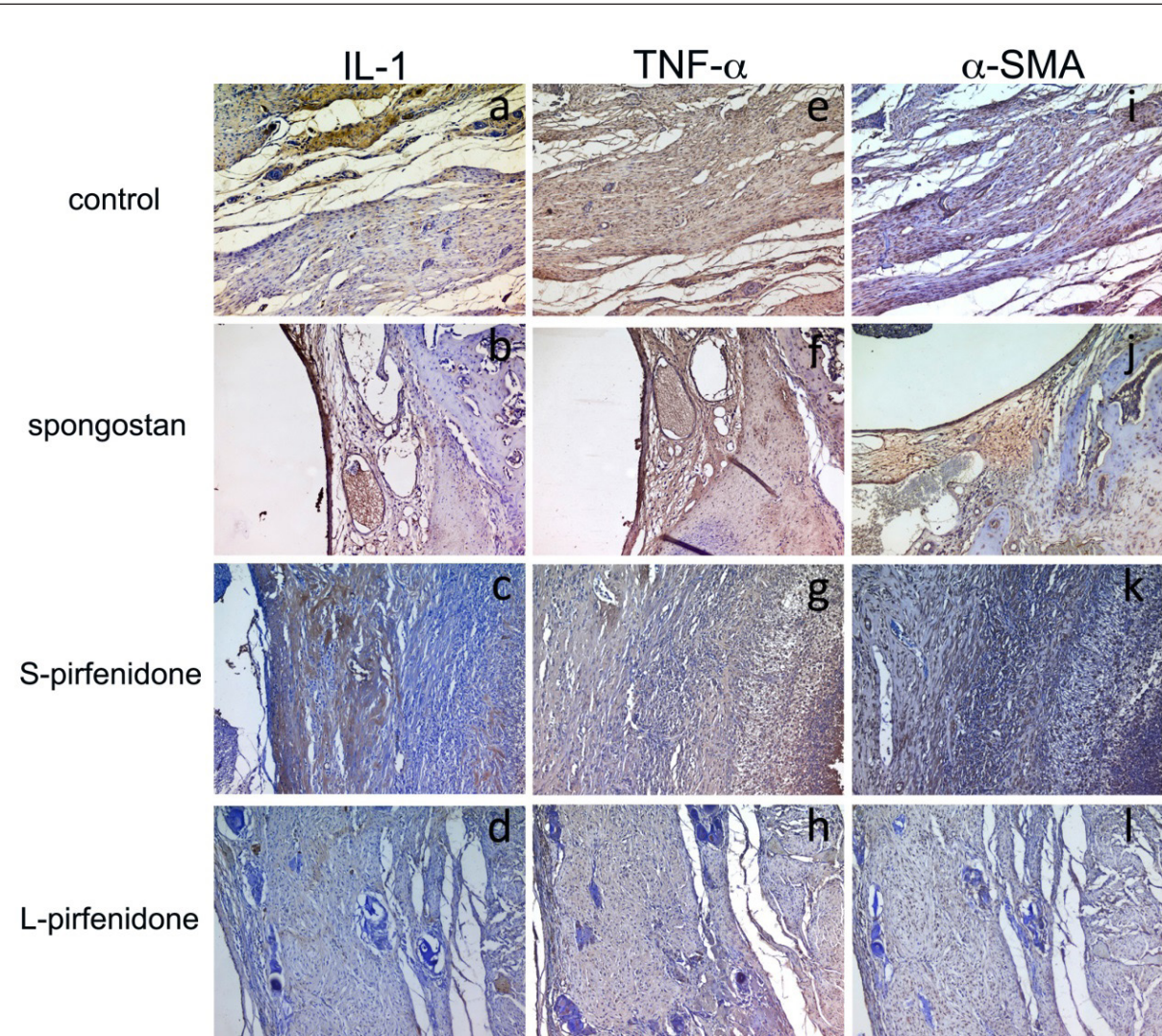


Figure-2. Immunohistochemistry of IL-1 (a, b, c, d), TNF- α (e, f, g, h) and α -SMA (i, j, k, l) on epidural fibrosis of control, spongostan, S-pirfenidone and L-pirfenidone rats. The magnification was 200x.

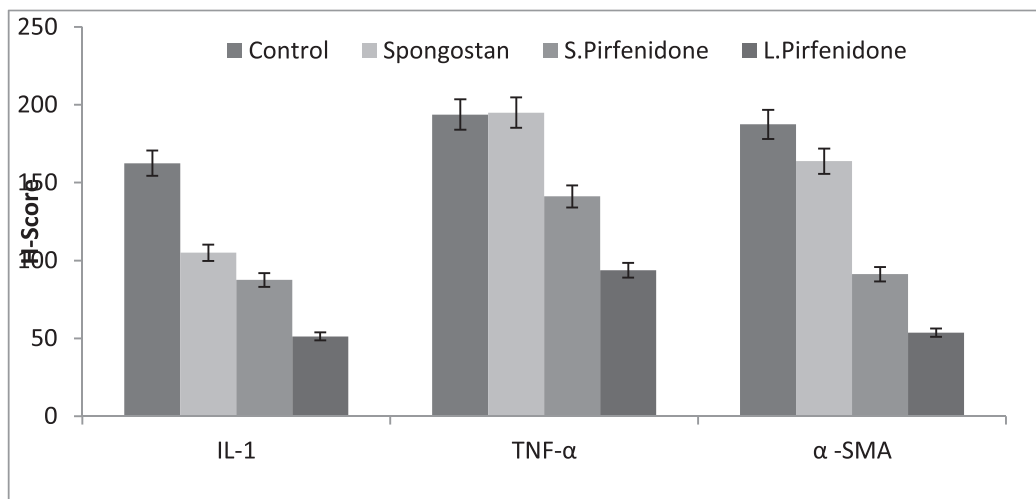


Figure-3. The distribution of immunostaining intensity (H-score) in epidural fibrosis samples with anti-IL-1, anti-TNF- α and anti α -SMA antibodies.

Table-3. The scar tissue consistency and inflammatory response grades in pirfenidone treatment groups were lower than control and spongostan groups. All of the rats in L. pirfenidone group were grade-1 ($p<0.001$).

Variables	Control	Spongostan	S.Pirfenidone	L.Pirfenidone	p
Dura mater thickness, <i>Mean±SD</i>	23.5±4.4	16.7±4.7	16.8±3.67	11.1±1.9	<0.001
H Score Results, <i>Mean±SD</i>					
IL-1	162.5±32.4	105.0±30.7	87.5±16.7	51.25±20.3	<0.001
TNF- α	193.8±59.7	195.0±62.1	141.2±45.5	93.75±33.8	0.001
α –SMA	187.5±30.6	163.8±35.8	91.2±20.3	53.75±17.7	<0.001
Epidural Fibrosis, n (%)					
Grade 1	0 (0%)	3 (37.5%)	5 (50%)	5 (62.5%)	0.028
Grade 2	2 (25%)	3 (37.5%)	1 (12.5%)	3 (37.5%)	
Grade 3	6 (75%)	2 (25%)	3 (37.5%)	0(0%)	
Scar tissue consistency and inflammatory response, n (%)					
Grade 1	0 (0%)	2 (25%)	6 (75%)	8 (100%)	<0.001
Grade 2	4 (50%)	4 (50%)	2 (25%)	0 (0%)	
Grade 3	4 (50%)	2 (25%)	0 (0%)	0(0%)	
Arachnoidal involvement, n(%)					
Yes	5 (62.5%)	3 (37.5%)	2 (25%)	0 (0%)	0.064
No	3 (37.5%)	5 (62.5%)	6 (75%)	8 (100%)	

SD, Standart Deviation

DISCUSSION

Laminectomy techniques are widely used techniques in spinal disorders surgery and they often results in the formation of epidural fibrosis. Epidural fibrosis is the major cause of postoperative morbidities such as persistent low back pain and disability⁽²³⁾. In an effort to find a solution to this problem, numerous methods have been studied to prevent EF by surgical methods and various biological agents. Nevertheless, clinical results of these methods have been limited because the effects were not as satisfactory as expected. The new treatment methods should be developed for prevent EF.

The new-targeted therapies of EF is against to fibrosis mechanism. However, mechanism of fibrosis formation is still unclear, a study has shown that after lomber laminectomy epidural hematoma, epidural fat accumulation and muscle invasion at the laminectomy site plays important role in the formation of epidural fibrosis⁽²¹⁾. Some reports have shown that fibroblast proliferation was the main reasons for epidural fibrosis⁽³⁾.

Additionally, the number of fibroblasts is considered as a parameter for determining the density of epidural fibrosis⁽³⁾. Another study suggested that activated fibroblasts/myofibroblasts are critical effector cells associated with the progression of fibrosis^(25,27).

Pirfenidone (5-methyl-N-phenyl-2- (1H)-pyridone is a drug with anti-fibrotic and anti-inflammatory effects. Pirfenidone's antifibrotic properties have shown in various clinical and animal-based experimental studies⁽⁵⁾. Pirfenidone is first drug of choice for IPF. Pirfenidone has been accepted for the treatment of idiopathic pulmonary fibrosis in many countries and it is first drug of choice for IPF, now. Latest studies have shown that pirfenidone has beneficial effect for Crohn's disease and intestinal fibrosis⁽¹⁴⁾. Some animals studies have shown that pirfenidone inhibit progression of fibrosis and prevent the formation of fibrotic lesions on rat hepatic, pulmoner, bladder, renal , cardiac cells^(1,6-7,9,22).

Pirfenidone has been shown to prevent the accumulation of hydroxyproline, procollagen I and III, inflammatory cells and transforming growth factor-beta TGF- β ⁽¹¹⁾. Pirfenidone exerts many effects, that is, a decrease in fibroblast proliferation, reduction of TFG- β stimulated reactions, lowered levels of a myofibroblast marker alpha smooth muscle actin (α -SMA)⁽¹⁶⁾.

Proinflammatory cytokines for example tumor necrosis factor TNF- α , interleukin IL-1 β and vascular endothelial growth factor (VEGF) playing important roles in inflammation process. Pirfenidone effect some pro-inflammatory cytokines, including IL-1 β , IL-6, IL-12, IL17, and TNF- α . Suna at. All Show that treatment

with pirfenidone reduce the expression of IL-1 β , IL-6, and IL-12⁽²⁴⁾. We showed that the H-score for IL-1 was significantly lower in the L-pirfenidone group when compared with spongostan group. Our study showed that pirfenidone reduce the expression of IL-1.

Myofibroblast differentiation is important event of the pathogenesis of fibrosis. α -SMA is specific marker molecule of myofibroblast differentiation. In order to evaluate the effects of pirfenidone, we evaluated the expression of α -SMA. We showed that α -SMA expression was significantly suppressed by pirfenidone.

TNF- α is potent activator of the intracellular signaling molecules, it stimulates the proliferation of fibroblasts via TGF- β 1. The H-score for TNF- α was significantly lower in L.Pirfenidone group than the control and spongostan groups, in this study (respectively p<0,01, p<0.01).

The mean thickness of the dura mater for L.Pirfenidone, the scar tissue consistency and inflammatory response grades in pirfenidone treatment groups, epidural fibrosis grade in pirfenidone groups were lower than other groups.

Histological and immunohistochemistry analysis have showed that pirfenidone attenuate EF in the postlaminectomy rat model.

REFERENCES

1. Azuma A, Nukiwa T, Tsuboi, E, Suga M, Abe S, Nakata K, Taguchi Y, Nagai S, Itoh H, Ohi M, Sato A, Kudoh S. Double-blind, placebo-controlled trial of pirfenidone in patients with idiopathic pulmonary fibrosis. *Am J Respir Crit Care Med* 2005; 171: 1040–1047.
2. Bacus S, Flowers JL, Press MF, Bacus JW, McCarty KS Jr. The evaluation of estrogen receptor in primary breast carcinoma by computer-assisted image analysis. *Am J Clin Pathol* 1988; 90(3): 233–239.
3. Burton CV. Causes of failure of surgery on the lumbar spine: ten-year follow-up. *Mt Sinai J Med* 1991; 58(2): 183–187.
4. Cemil B, Kurt G, Aydın C, Akyurek N, Erdogan B, Ceviker N. Evaluation of tenoxicam on prevention of arachnoiditis in rat laminectomy model. *Eur Spine J* 2011; 20(8): 1255–1258.
5. Conte E, Gili E, Fagone E, Fruciano M, Iemmolo M, Vancheri C. Effect of pirfenidone on proliferation, TGF- β -induced myofibroblast differentiation and fibrogenic activity of primary human lung fibroblasts. *Eur J Pharm Sci* 2014; 58: 13–19.
6. Di Sario A, Bendia E, Svegliati BG, Ridolfi F, Casini A, Ceni E, Saccomanno S, Marzioni M, Trozzi L, Sterpetti P, Taffetani S, Benedetti A. Effect of pirfenidone on rat hepatic stellate cell proliferation and collagen production. *J Hepatol* 2002; 37: 584–591.
7. Duan L, Qi J, Huang T, Gu X, Xu D, Kong X, Qian X. Pirfenidone attenuates bladder fibrosis and mitigates deterioration of bladder function in a rat model of partial bladder outlet obstruction. *Mol Med Rep* 2015; 12: 3639–3647.
8. He Y, Revel M, Loty B. A quantitative model of post-laminectomy scar formation. Effects of a nonsteroidal anti-inflammatory drug. *Spine* 1995; 20: 557–563.
9. Hewitson TD, Kelynack KJ, Tait MG, Martic M, Jones CL, Margolin SB, Becker GJ. Pirfenidone reduces in vitro rat renal fibroblast activation and mitogenesis. *J Nephrol* 2001; 14: 453–460.
10. Inomata M, Kamio K, Azuma A, Matsuda K, Kokuho N, Miura Y, Hayashi H, Nei T, Fujita K, Saito Y, Gemma A. Pirfenidone inhibits fibrocyte accumulation in the lungs in bleomycin induced murine pulmonary fibrosis. *Respir Res* 2014; 15: 16–30.
11. Iyer SN, Hyde DM, Giri SN. Anti-inflammatory effect of pirfenidone in the bleomycin-hamster model of lung inflammation. *Inflammation* 2000; 24: 477–491.
12. Kadir S, Wenzel Kragstrup T, Dige A, Kok JS, Dahlerup J, Kelsen J. Pirfenidone inhibits the proliferation of fibroblasts from patients with active Crohn's disease. *Scand J Gastroenterol.* 2016; 51: 1321–1325.
13. Lin X, Yu M, Wu K, Yuan H, Zhong H. Effects of pirfenidone on proliferation, migration, and collagen contraction of human Tenon's fibroblasts in vitro. *Investig. Ophthalmol Vis Sci* 2009; 50: 3763–3770.
14. Meier R, Lutz C, Cosín-Roger J, Fagagnini S, Bollmann G, Hünerwadel A, Mamie C, Lang S, Tchouboukov A, Weber F, Weber A, Rogler G, Hausmann M. Decreased fibrogenesis after treatment with pirfenidone in a newly developed Mouse model of intestinal fibrosis. *Inflamm Bowel Dis* 2016; 22: 569–582.
15. Miyamoto K, Masuda K, Inoue N, Okuma M, Muehlemann C, An HS. Anti-adhesion properties of a thrombin-based hemostatic gelatin in a canine laminectomy model: A biomechanical, biochemical, and histologic study. *Spine* 2006; 31: E91–97.
16. Nakayama S, Mukae H, Sakamoto N, Kakugawa T, Yoshioka S, Soda H, et al. Pirfenidone inhibits the expression of HSP47 in TGF- β 1-stimulated human lung fibroblasts. *Life Sci* 2008; 82: 210–7.
17. Oku H, Nakazato H, Horikawa T, Tsuruta Y, Suzuki R. Pirfenidone suppresses tumor necrosis factor- α , enhances interleukin-10 and protects mice from endotoxic shock. *Eur J Pharmacol* 2002; 446: 167–176.
18. Oku H, Shimizu T, Kawabata T, Nagira M, Hikita I, Ueyama A, Matsushima S, Torii M, Arimura A. Antifibrotic action of pirfenidone and prednisolone: different effects on pulmonary cytokines and growth factors in bleomycin-induced murine pulmonary fibrosis. *Eur J Pharmacol* 2008; 590: 400–408.
19. Rodríguez-Castellanos M, Tlacuilo-Parra A, Sánchez-Enríquez S, Vélez-Gómez E, Guevara-Gutiérrez E. Pirfenidone gel in patients with localized scleroderma: a phase II study. *Arthritis Res Ther* 2014; 16(6): 510.

-
20. Schelegle SN, Leonard S, Shi X, Margolin SB, Vallyathan V. Effects of pirfenidone on the generation of reactive oxygen species in vitro. *J Environ Pathol Toxicol Oncol* 1999; 18: 169-177.
 21. Sen O, Kizilkilic O, Aydin MV, Yalcin O, Erdogan B, Cekinmez M, Caner H, Altinors N. The role of closed-suction drainage in preventing epidural fibrosis and its correlation with a new grading system of epidural fibrosis based on MRI. *Eur Spine J* 2005; 14: 409-414.
 22. Shi Q, Liu X, Bai Y, Cui C, Li J, Li Y, Hu S, Wei Y. In vitro effects of pirfenidone on cardiac fibroblasts: proliferation, myofibroblast differentiation, migration and cytokine secretion. *PLoS One* 2011; 6: e28134.
 23. Songer MN, Rauschnig W, Carson EW, Pandit SM. Analysis of peridural scar formation and its prevention after lumbar laminotomy and discectomy in dogs. *Spine* 1995; 20: 71-80.
 24. Suna YW, Zhanga YY, Keb XJ, Wuc XJ, Chena Z, Chia P. Pirfenidone prevents radiation-induced intestinal fibrosis in rats by inhibiting fibroblast proliferation and differentiation and suppressing the TGF- β 1/Smad/CTGF signaling pathway. *Eur J Pharmacol* 2018; 822: 199-206.
 25. Wynn TA. Cellular and molecular mechanisms of fibrosis. *J Pathol* 2008; 214: 199-210.
 26. Tang W, Zhang Y, Qian C, Yuan Z, Du J. Induction and mechanism of apoptosis by hydroxycamptothecin in human Tenon's capsule fibroblasts. *Invest Ophthalmol Vis Sci* 2012; 53: 4874-4880.
 27. Zeisberg M, Kalluri R. Cellular mechanisms of tissue fibrosis. Common and organ-specific mechanisms associated with tissue fibrosis. *Am J Physiol Cell Physiol* 2013; 304: C216-C225.