

## A Case of Ectrodactyly and Micromelia with Flexural and Rotational Tarsal Deformity in a Simmental Calf

### (Simmental Bir Buzağıda Fleksural ve Rotasyonel Tarsal Deformite İle Birlikte Şekillenen Ektrodaktili ve Mikromeli Olgusu)

Uğur AYDIN <sup>1,a</sup> Uğur YILDIZ <sup>1,b</sup> Emin KARAKURT <sup>2,c</sup> Özgür AKSOY <sup>1,d</sup>

<sup>1</sup> Department of Surgery, Faculty of Veterinary Medicine, Kafkas University, TR-36100 Kars - TURKEY

<sup>2</sup> Department of Pathology, Faculty of Veterinary Medicine, Kafkas University, TR-36100 Kars - TURKEY

ORCIDS: <sup>a</sup> 0000-0001-5756-4841; <sup>b</sup> 0000-0002-4782-1012; <sup>c</sup> 0000-0003-2019-3690; <sup>d</sup> 0000-0002-4800-6079

Article Code: KVFD-2020-24137 Published Online: 05.05.2020

#### How to Cite This Article

Aydın U, Yıldız U, Karakurt E, Aksoy Ö: A case of ectrodactyly and micromelia with flexural and rotational tarsal deformity in a Simmental calf. *Kafkas Univ Vet Fak Derg*, 26 (4): 577-578, 2020. DOI: 10.9775/kvfd.2020.24137

#### Dear Editor,

Congenital anomalies are common in cattle breeding and this problem causes great economic losses <sup>[1,2]</sup>. It has been determined that 26.6% of congenital anomalies occur in the musculoskeletal system in calves in Kars region, Turkey <sup>[2]</sup>. Micromelia is the small and imperfect development of one or more limbs <sup>[3,4]</sup>. Ectrodactyly is the congenital absence of all or part of one or more phalanges <sup>[1,3,4]</sup>.

Many environmental factors and genetic disorders act alone or together in the formation of these malformations <sup>[2,3]</sup>. It is known that a dominant gene causes the formation of ectrodactyly in calves <sup>[3]</sup>. Also, nutritional disorders including some vitamin and mineral deficiencies, various teratogenic agents, stress factors, the use of bulls with genetic disorders, and not preferred artificial insemination in reproduction have important roles in etiology <sup>[2]</sup>.

In congenital musculo-skeletal malformations, mostly dystocia occurs. Also, the calf has difficulty in moves and feeding. Even if existing disorders are treated and calves live, these animals have no reproductive value.

For the presented case, an informed consent form was taken from the owner.

A conformational disorder was observed in the back left leg of a 4-day, male, Simmental calf brought to the surgical outpatient clinic of Kafkas University Veterinary Faculty Animal Hospital. The tarsal joint was in the hyperflexion position in the cranial-dorsal direction, and it was found that the joint had no movement capacity during passive strains. It was determined that the entire part of the

extremity at the distal of the tarsal joint was atrophic, and only the metatarsus-3 and its phalanges were shaped, and the metatarsus-4 and related fingers were absent, considering the rotational state of the limb. In addition, the limb section distal from the tarsal joint had a 180° rotational view. Due to this rotational structure, the solea part of the nail was located at the dorsal (*Fig. 1*). Radiological examination revealed that metatarsus-3 did not have a proximal physical line and it was determined that tarsal bones showed an abnormal structure and localization. In addition, phalanx 1 and 2 were similarly fused to one bone appearance, fused together (*Fig. 2*).

With the evaluations made, it was thought that keeping the relevant extremity under the abdomen in the flexion position without touching the ground would not cause much trouble in terms of sustaining the animal's life. The fact that the relevant limb was shaped in a rudimentary structure and rotationally created an unfavorable picture for operative intervention. In addition, operation was not required due to the known risks of amputation and not to cause extra economic losses.

Congenital anomalies are frequently encountered in calves, and many of them are considered unfavorable for operative treatment. Generally, it is known that the patient cannot stand and feed on its own in musculoskeletal anomalies. Although there are anatomical defects in the other extremity in our case, the fact that the patient can stand up and meet its needs until it can be cut is considered as an important criterion. The described case is considered as a congenital malformation whose multifactorial factors need to be determined, such as different, interesting and other patterns.



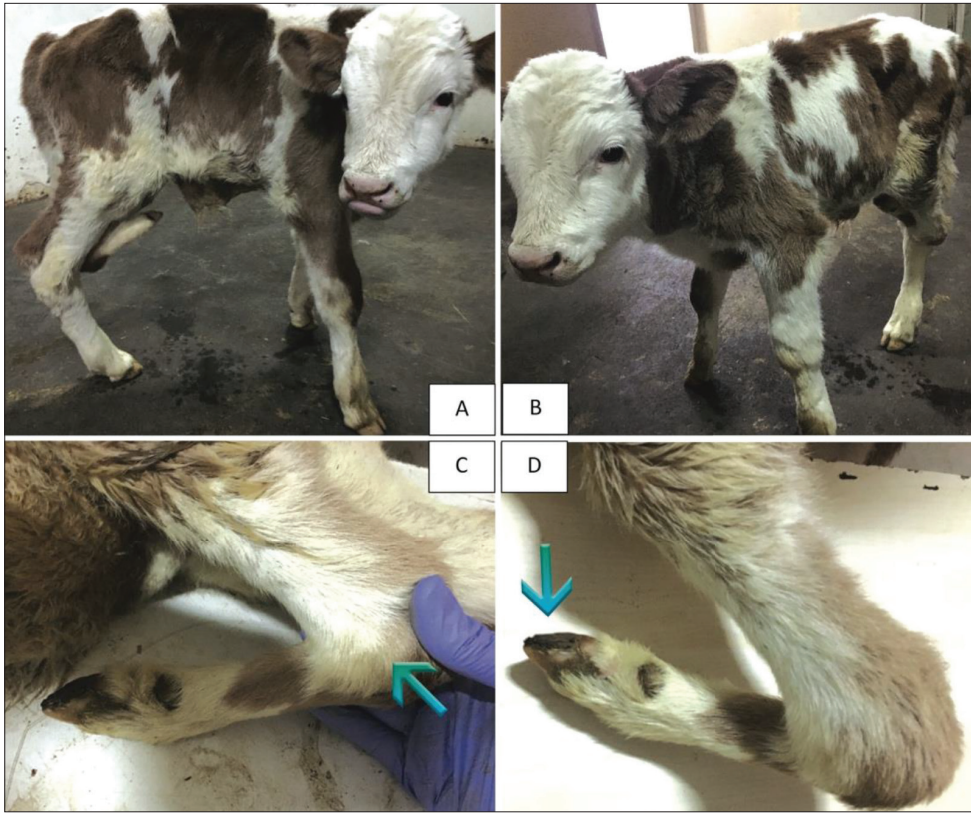#### Correspondence



+90 474 2426807/5222

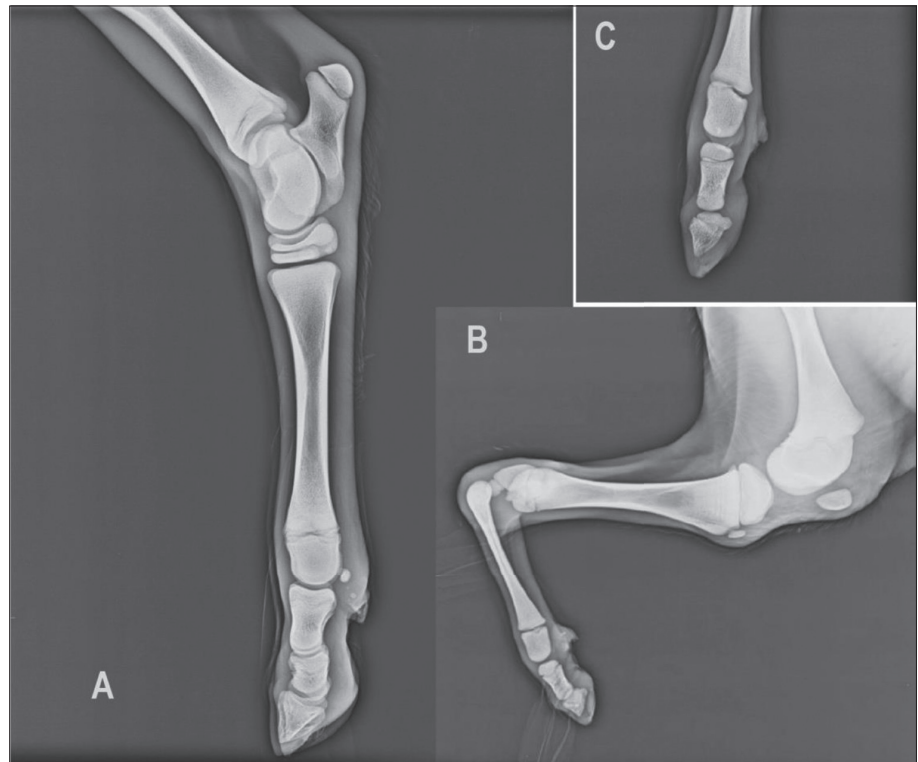


uguraydin076@hotmail.com



**Fig 1. A, B:** View of the patient from right and left side with the animal standing; The animal can easily stand and walk on three limbs; **C:** Excessive flexural deformity and appearance of torsioned joint (arrow). The front face of the limb is at the back and the front of the back is at the distal part of the distal part of the tarsal joint (there is approximately 180° rotation); **D:** In the rotated limb, the solea part of the 3<sup>rd</sup> phalanx was located dorsally (arrow)

**Fig 2. A:** Normal appearance of tarsal joints, metatarsus and phalanges in intact limbs. It is noteworthy that the 2<sup>nd</sup> phalanx and proximal sesamoid bones are not normal in this extremity, even if the bone roof of the limb has a normal appearance; **B:** The appearance of the absence of proximal growth plate of metatarsus 3, with the abnormal localization of the tarsal bones in the limb with anomaly. Proximal sesamoid bones were not formed in the metatarsus 4 and its associated phalanges and anomaly leg; **C:** Phalanx 1 and 2 are formed together, but their borders are not clear. Phalanx 1 has a very small structure and seems to be fused with phalanx 2



## REFERENCES

1. Leipold HW, Hiraga T, Dennis SM: Congenital defects of the bovine musculoskeletal system and joints. *Vet Clin North Am Food Anim Pract*, 9 (1): 93-104, 1993. DOI: 10.1016/S0749-0720(15)30674-5
2. Aksoy Ö, Kılıç E, Öztürk S, Özaydın İ, Kurt B, Baran V: Buzağı, kuzu

ve oğlaklarda karşılaşılan doğumsal anomaliiler: 1996-2005 (262 Olgu). *Kafkas Univ Vet Fak Derg*, 12 (2): 147-154, 2006.

3. Alkan F, Tuzcu M, Koç Y, Oğurtan Z: Bir buzağıda ectrodactyly ile birlikte şekillenmiş micromelia. *Vet Bil Derg*, 13 (2): 129-131, 1997.

4. Özenç E: Bir buzağının tüm ekstremitelerinde gözlemlenen peromelia olgusu. *Kocatepe Vet J*, 7 (2): 57-59, 2014.