

Immunological Effects of Autogenous Vaccine Administration in Cattle with Cutaneous Papillomatosis

Hakan AYDIN¹ , Volkan GELEN² , Emin ŞENGÜL³ , Serkan YILDIRIM⁴ 

¹Department of Virology, Atatürk University Faculty of Veterinary Medicine, Erzurum, Turkey

²Department of Physiology, Kafkas University Faculty of Veterinary Medicine, Kars, Turkey

³Department of Physiology, Atatürk University Faculty of Veterinary Medicine, Erzurum, Turkey

⁴Department of Pathology, Atatürk University, Faculty of Veterinary Medicine, Erzurum, Turkey

Cite this article as: Aydın, H., Gelen, V., Şengül, E., Yıldırım, S., 2020. Immunological Effects of Autogenous Vaccine Administration in Cattle with Cutaneous Papillomatosis. Acta Vet Eurasia 2020; 46: 98-103.

ORCID IDs of the authors: H.A. 0000-0003-2200-1744; V.G. 0000-0002-5091-1262; E.Ş. 0000-0003-1566-1816; S.Y. 0000-0003-2457-3367

Abstract

Papillomavirus is a viral agent that induces the formation of benign tumors in mammals. There are different treatment methods for cutaneous papilloma caused by the bovine papillomavirus (BPV), and one of them is autogenous vaccination. We aimed to investigate the immunological effects of autogenous vaccination in cattle. In this study, 30 cattle with cutaneous papillomatosis were included. The diagnosis was made by histopathology and polymerase chain reaction, and a phylogenetic tree was constructed. As a result of the phylogenetic analyses, the pathogen responsible for the papilloma was classified as BPV-2 type in the genus of *Delta papillomavirus*. The papilloma tissue specimens collected from each animal were used to prepare the autogenous vaccine. The autogenous vaccine was administered once a week for 4 weeks.

The blood samples collected before and after the vaccination were immunologically analyzed. It was determined that the autogenous vaccination led to an increase in the leukocyte, lymphocyte, and interleukin-6 (IL-6) levels. Once the vaccine was administered, regression started in the cutaneous papilloma in the first month. As a result, bovine papillomatosis is an economically important infection for dairy farming. It has been concluded that autogenous vaccination is a practical therapeutic method that causes lesions to regress, especially by triggering IL-6 and lymphocyte production in the cattle infected with papillomavirus.

Keywords: Autogenous vaccination, bovine papillomatosis, interleukin-6, lymphocyte

Introduction

Papillomaviruses are epitheliotropic, non-enveloped, double-stranded DNA viruses. The *Papillomaviridae* family consists of 5 genera affecting cattle, including *Deltapapillomavirus*, *Xipapillomavirus*, *Epsilonpapillomavirus*, *Dyoxipapillomavirus*, and *Dyokappapapillomavirus*. Among these genera, 24 types of bovine papillomaviruses (BPVs) have been reported to date (Daudt et al., 2018). BPV infections are widespread around the world. Cutaneous papillomas are usually benign tumors that have a complex etiology and pathogenesis and are characterized by epithelial proliferation. Papillomatosis is formed by the host and tissue-specific papillomaviruses of the *Papillomaviridae* family. While direct contact is a significant method

of transmission in the formation of cutaneous papillomatosis, contaminated materials, such as leashes, ear tagging, milking equipment, castration, injections, immune suppression, genetics, and mutation-like factors, also play a role (Atasever et al., 2005; Dagalp et al., 2017; Daudt et al., 2018). Papilloma infections especially tend to spread among the immunosuppressed animals (Alcigir et al., 2016; Alcigir and Timurkan, 2018). Cattle are the main source and natural carriers of the virus. The virus usually enters the cracks and other defects on the skin. The disease is encountered in all the age groups but is seen more in young cattle. While cutaneous papilloma in cattle is seen in every part of the body, they are usually formed in the regions of the head and neck. There are different treatment methods of BPV infection, including antimony preparations, homeopathic

Address for Correspondence: Hakan AYDIN • E-mail: hakanaydin.dr@gmail.com

Received Date: 19.01.2020 • Accepted Date: 02.06.2020 • Available Online Date: 23.07.2020 • DOI: 10.5152/actavet.2020.20002

Available online at actavet.org



This work is licensed under a Creative Commons Attribution-NonCommercial 4.0 International License.

drugs, ivermectin, and autogenous vaccination (Ranjan et al., 2013). This study aimed to investigate the immunological effects of autogenous vaccination in cattle with cutaneous papillomatosis.

Materials and Methods

Breed of animals

This study was carried out on 30 cattle with a mean age of 15 months in the Selim district of the province of Kars in eastern Turkey. Papilloma samples taken in 3 pieces were subjected to different procedures for identification and characterization of the virus, histopathology of the papilloma tissue, and vaccine preparation. Practices on the animals have been carried out in accordance with ethical rules and approved by the Ethics Committee of the Atatürk University Veterinary Faculty (Protocol no: 2018/77).

Histopathological analysis

The cutaneous tissue samples collected for the histopathological analysis were fixed with a 10% formalin solution for 48 hours. As per the routine tissue follow-up procedures, they were embedded in paraffin blocks, and 4- μ m thick cross-sections were obtained from all the blocks. The preparations prepared for the histopathological analysis were stained by hematoxylin-eosin and examined by light microscopy (Leica DM 1000, Germany).

Identification and phylogenetic analysis of BPV

A commercial kit was used for nucleic acid isolation (Vivantis Technologies, Malaysia). After the isolation, the nucleic acid suspension was stored at -20°C until polymerase chain reaction (PCR).

The L1 gene region, which is used frequently in the taxonomy of papillomaviruses and is highly protected, was preferred as the targeted gene region in the study. The partial L1 gene region was amplified with the BPV specific primers; forward: FAP59 (5'-TAA CWG TIG GIC AYC CWT ATT-3'); reverse: FAP64 (5'-CCW ATA TCW VHC ATI TCI CCA TC-3'). Reaction conditions were maintained as previously reported (Melo et al., 2014), first denaturation step at 95°C for 7 min and 35 cycles at 95°C for 1.5 min, at 52°C for 2 min, and 72°C for 1.5 min; the final extension step was at 72°C for 5 min. The length of the 480-bp product was obtained by PCR. The amplicons were evaluated using the gel electrophoresis process. One randomly selected sample from the positive samples was subjected to sequencing. The raw data resulting from the sequencing were analyzed by the BioEdit version 7.2.5 and the MEGA 5.1 software (Hall et al., 2011; Tamura et al., 2013). Our sequence has been entered into the World Gene Bank. GenBank accession number of our BPV Kars strain is MT178264. As a result of the analysis, the phylogenetic location of our BPV strain was determined by comparison with the reference strains obtained from GenBank.

Preparation and application of the autogenous vaccination

Approximately 25–30 g of tumor tissue was obtained from each animal, and 48 mL of tris buffer (pH 7.5) was added to the tumor

tissue. The tissue samples were disintegrated in the muller at cold conditions (4°C) for 15–20 min by sterilized sand that was autoclaved. Half of the mixture (36 mL) was made up to 60–65 mL with the tris buffer, and 10 mL vaccines were prepared by adding 0.5% formalin to the suspension, which was topped up by crystal penicillin. The vaccines were stored at 4°C until used. The autogenous vaccines were administered 4 times subcutaneously at 1-week intervals in 10 mL dosages. Hematological and immunological analyses were performed by collecting the blood samples before and after each vaccination.

Hematological analyses

For hematological analyses, the blood samples were collected in ethylenediaminetetraacetic acid (EDTA) containing test tubes. By using a blood count device for veterinarians (PCE-210VET, Erma Inc., Tokyo, Japan), the leukocyte (white blood cell $10^3/\text{mm}^3$), lymphocyte%, neutrophil%, and monocyte% parameters were determined in the blood samples. The interleukin-6 (IL-6) parameter in the serum samples was analyzed using an immunoassay kit (Cattle IL-6 ELISA Kit). The results were calculated based on the procedure instructed in the kit. The obtained data are reported as the mean value+standard deviation (SD) (ng/mL).

Statistical analysis

The quantitative values were analyzed using one-way analysis of variance and Tukey's test in the IBM Statistical Package for the Social Sciences version 20.00 (IBM SPSS Corp.; Armonk, NY, USA) software and are reported as means \pm SD with a significance level of $p < 0.05$.

Results

After 1 month of autogenous vaccination, significant regression occurred in the papilloma tissues, and within 3 months, the papilloma tissues disappeared completely.

Virological findings

In our study, BPV was identified in the samples obtained from cattle with skin papillomatosis. Phylogenetic analyses of the L1 gene region showed that Brazilian, American, and Turkish strains were assembled in the same group with BPV-2 types in the *Deltapapillomavirus* genus (Figure 1).

Effect of autogenous vaccination on some hematological parameters

Blood samples were collected from the cattle before and after autogenous vaccination. It was observed that the leukocyte counts in the collected blood samples after the 3rd and 4th vaccinations significantly increased compared to those in the 3rd and earlier weeks ($p < 0.05$, Figure 2a, $n = 30$). Moreover, in the blood samples, lymphocyte, neutrophil, and monocyte parameters were investigated. It was found that the lymphocyte% values significantly increased after the 3rd and 4th vaccinations ($p < 0.05$, Figure 2b, $n = 30$), while the neutrophil% and monocyte% values relatively increased ($p > 0.05$, Figure 2c and d, $n = 30$).




Figure 1. Phylogenetic analysis of the L1 gene region of the papillomavirus (480bp). The star symbol indicates Turkish BPV-2 strain

It was determined that after the 3rd and 4th vaccinations, the IL-6 levels significantly increased compared to those in the first weeks ($p < 0.05$, Figure 3, $n=30$).

Histopathological findings

Macroscopically, cauliflower-like tumoral structures were seen on the head and neck regions of the animals. It was determined that some of these tumors had hemorrhages and sections of the structures were rigid, the middle part was gray white, and the outer part was necrotic. Microscopically, we detected hyperkeratosis, mild acanthosis, excess proliferation of the stratum spinosum, hydropic degeneration of the epithelium, and intracytoplasmic inclusion body (Figure 4-7).

Discussion

It is known that the L1 gene region is highly protected in papillomaviruses; therefore, it is often used to determine the taxonomic location of BPVs. In the phylogenetic analysis, our study strain was clustered with KX924601 strain in the BPV type-2 of the *Deltapapillomavirus* genus.

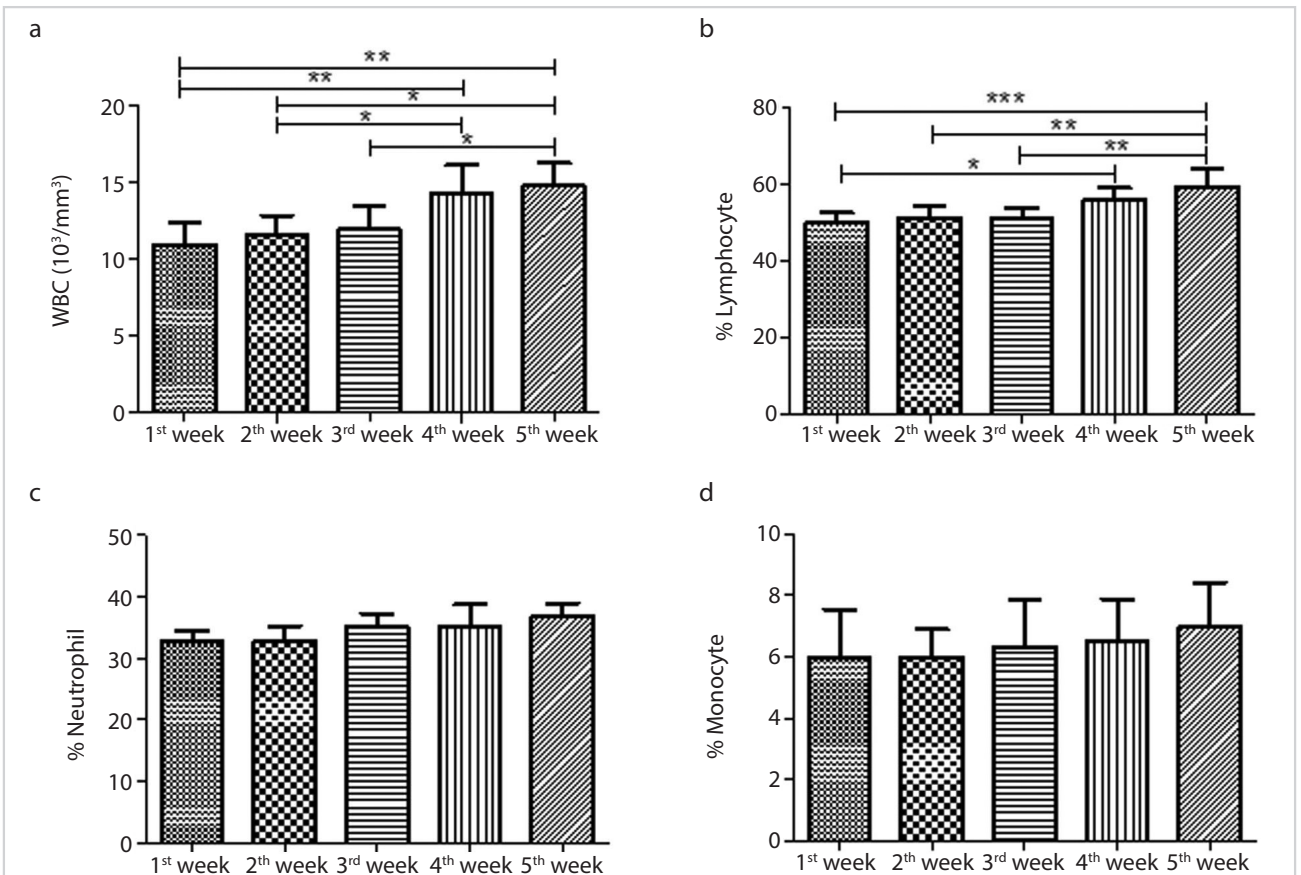


Figure 2. a-d. Immunological parameters in blood samples taken from cattle before and after autogenous vaccination. A: Leukocyte values ($n=30$, *, $p < 0.05$, **, $p < 0.01$). B-C-D: %Lymphocyte, %Neutrophil and %Monocyte values ($n=30$, *, $p < 0.05$)

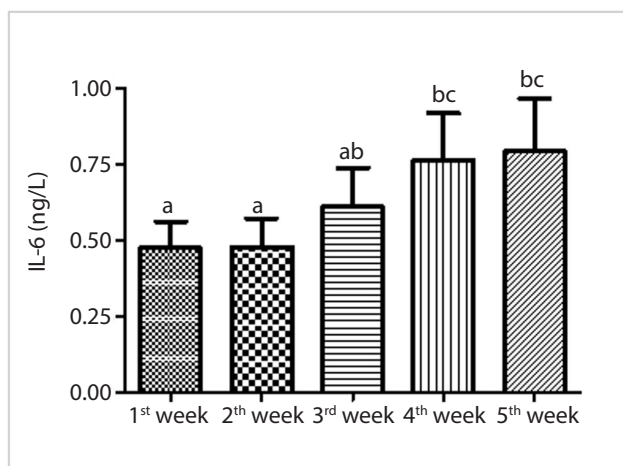


Figure 3. IL-6 levels at 1, 2, 3, 4 and 5 weeks in blood samples taken from vaccinated cattle (n=30,***; p<0.01)

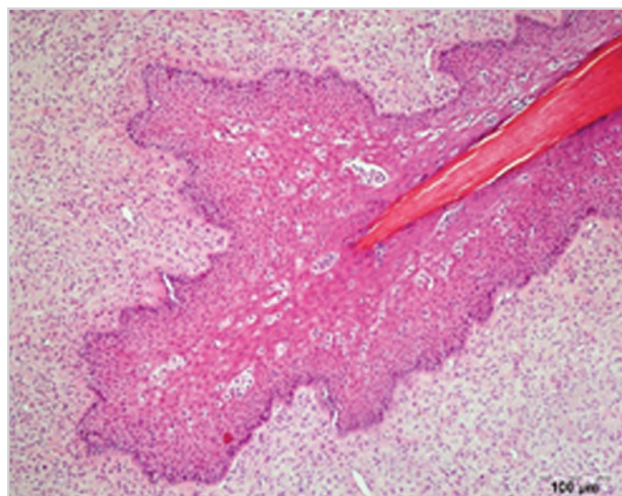


Figure 5. Acanthosis and proliferation of stratum spinosum, hydropic degeneration in epithelium, H&E, Bar: 100 µm

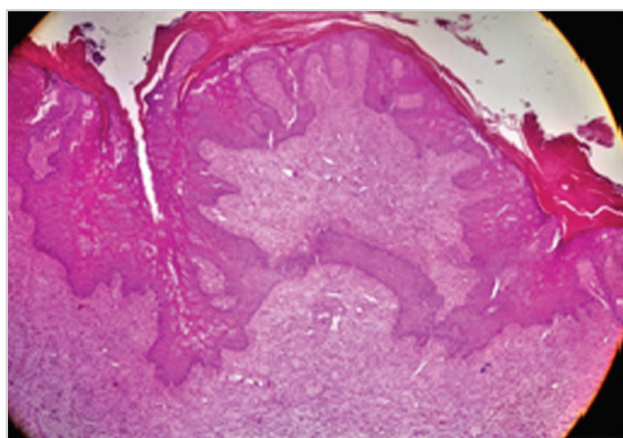


Figure 4. Hyperkeratosis, mild acanthosis and excessive proliferation of stratum spinosum, H&E, Bar: 200 µm

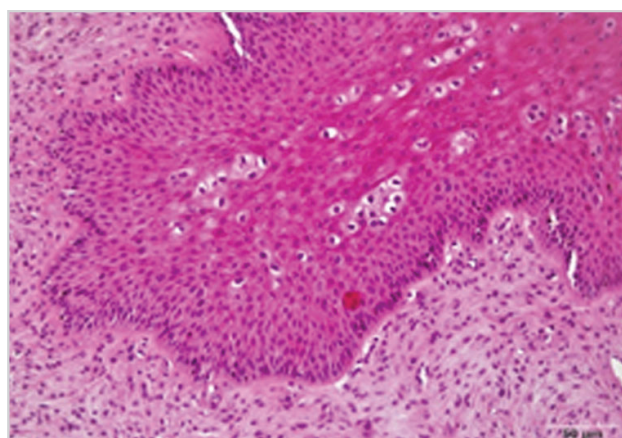


Figure 6. Proliferation of stratum spinosum, hydropic degeneration in epithelium, H&E, Bar: 50 µm

BPV-2 was reported as a possible agent for malignant bladder tumors and cutaneous fibropapilloma (Melo et al., 2014; Timurkan and Alcigir, 2017). In our study, BPV-2 was determined as the etiological agent of the cutaneous papilloma cases. BPV-1 and BPV-2 were also reported in equine sarcoid cases in horses. Papilloma cases have also been reported in other studies conducted in our country and evaluated as BPV-1 and BPV-2 (Ataseven et al., 2016; Tan et al., 2012).

There are 24 different types of BPV known, and co-infections related to these types are frequently observed. Different colors and sizes of papilloma may be observed in BPV co-infected cattle based on the type differences of the virus (Ranjan et al., 2013). In our study, all the papillomas were macroscopically and microscopically uniform, and phylogenetically, they were included in the BPV-2 type of *Deltapapillomavirus* genus.

In previous studies, the pathological analysis of the cutaneous papilloma revealed noticeable acanthosis, hyperkeratosis, and hyperplasia of keratinocytes at the level of the stratum spinosum and rete-ridge objects that were noticeable at the border of the epidermis-dermis. Additionally, degenerative changes characterized by wide vacuolization incidents and peripherally located hyperchromatic nuclei were observed in the acanthosis toward the dermis and the cytoplasm of cells in the epidermis. In cases where the tumors were contaminated with secondary bacterial infection, determined neutrophil leukocyte exudation and erosion ulceration at the dermal and epidermal layers were observed (Atasever et al., 2005; Kirmizigul et al., 2010). We detected similar findings in our study.

Cutaneous papillomavirus causes benign tumors that are usually characterized by epithelial proliferation commonly seen in cattle. Genetic factors, humoral diseases, immune systems, and

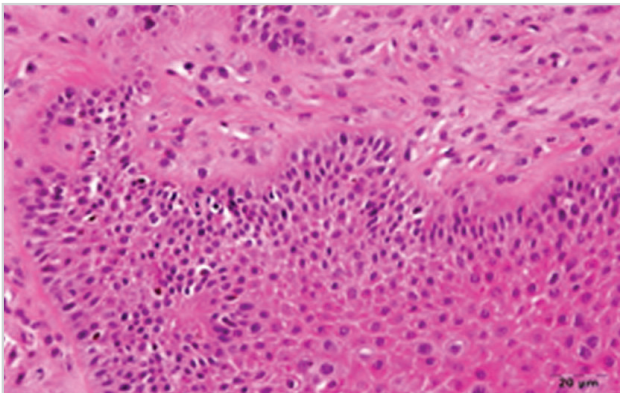


Figure 7. Hyperchromasia, hydropic degeneration and intracytoplasmic inclusion bodies in proliferating epithelium, H&E, Bar: 20 μ m

sunlight play a role in the pathogenesis of papillomaviruses, such that these lesions may transform into cancers based on these negative factors (Ranjan et al., 2013). The long and cold winters of the region, where our study population is located, have negative effects on the immune system.

There are different treatment methods in cattle with papillomatosis, including cauterization, excision, cryotherapy, local anesthesia, autologous or heterologous vaccination, autohemotherapy, and administration of immune-stimulating drugs (Archana et al., 2019; Kale et al., 2019; Rothacker, et al., 2015). It has been determined that autohemotherapy administration at certain intervals caused regression of the papilloma tissues (Chand et al., 2018; Kale et al., 2019; Rothacker et al., 2015). Kirmizigul et al. (2010) determined that ivermectin administration led to regression in the papilloma tissues by stimulating the immune system in animals, and the papilloma tissues disappeared completely in 3 months. Chand et al. (2018) observed that regression took place in almost all the animals that were administered autohemotherapy. The immune system plays an important regulating role in the papillomavirus infections. It was reported that cellular immunity was more effective than humoral immunity in the regression of lesions (Borges et al., 2017; Nicholls and Stanley, 2000). In the case of long-term anticancer treatment in dogs, cutaneous papillomas have been observed to increase with the suppression of the immune system, deterioration of T cell responses, IgM deficiency, and hypogammaglobulinemia (Bredal et al., 1996; Lucroy et al., 1998). In equine sarcoids, it was reported that usage of the immuno-modulatory agents stimulates a host response (Rothacker et al., 2015). Moreover, corticosteroid administration with the autogenous vaccine has been reported to cause regression of papillomas (Le Net et al., 1997). In our study, in compliance with the literature, it was determined that autogenous vaccination led to an increase in the leukocyte counts and especially lymphocyte ratios. It was concluded that autogenous vaccination led to regression in the tumor tissue by increasing the lympho-

cyte cells that are responsible for cellular immunity and neutrophil cells that are responsible for the phagocytic activity.

IL-6 is a cytokine that has proinflammatory activity, and it plays an important role in the immune-system-related response. It is produced as a response to the tumor necrosis factor- α and IL-1, which have a main role in the formation of the immune and inflammatory responses. IL-6 is mainly secreted in vascular endothelial cells, mononuclear phagocytes, fibroblasts, and activated T-lymphocytes (Flemming, 2017; Mansell and Jenkins, 2013; Rose-John, 2012). In compliance with the literature, autogenous vaccination stimulated IL-6 formation in our study. Increasing the level of IL-6 leads to the stimulation of hematopoietic stem cells in the bone marrow, activation of assistive T-lymphocytes, and T-lymphocytes' induction of plasma cells from B-lymphocytes, creating antibodies. Additionally, IL-6 stimulates phagocytic cells in addition to T- and B-lymphocytes and increases the regression of the papilloma tissue by both cellular and humoral immunity (Streck, 2002). It is believed that the therapeutic treatment that we applied in our study achieved papilloma regression with this mechanism.

In conclusion, we evaluated the phylogenetic classification of the papillomavirus in cattle with cutaneous papillomatosis, histopathological evaluation of the tumor tissue, and the effects of autogenous vaccination on the immune system in this study. Unfortunately, there is no vaccine that can be used as a therapeutic or prophylactic agent against BPV in Turkey. Therefore, autogenous vaccination is an appropriate method. This practice, which stimulates the immune system, provides different responses to treatment based on the type of the virus, the growth stage of the papilloma, preparation method of vaccination, and implementation protocol. It was concluded that autovaccination may provide a therapeutic effect by activating the humoral and cellular immunity in BPV-2 infections.

Ethics Committee Approval: Ethics committee approval was received for this study from the ethics committee of Atatürk University Faculty of Veterinary (Protocol no: 2018/77).

Peer-review: Externally peer-reviewed.

Author Contributions: Concept - H.A., V.G., E.Ş., S.Y.; Design - H.A., V.G., E.Ş., S.Y.; Supervision - H.A., V.G.; Resources - H.A., V.G.; Materials - V.G.; Data Collection and/or Processing - V.G.; Analysis and/or Interpretation - H.A., V.G., E.Ş., S.Y.; Literature Search - H.A., V.G., E.Ş., S.Y.; Writing Manuscript - H.A., V.G., E.Ş., S.Y.; Critical Review - H.A., V.G., E.Ş., S.Y.; Other - V.G., S.Y.

Acknowledgements: The authors declare that there is no conflict of interest. There is no funding source. Data from the study were previously presented at the International Conference on Agriculture, Forest, Food, Veterinary Sciences and Technologies (ICAFOF-2018).

Conflict of Interest: The authors have no conflicts of interest to declare.

Financial Disclosure: The authors declared that this study has received no financial support.

References

- Alcigir, M.E., Atalay Vural, S., Timurkan, M.O., 2016. Investigation of E2, E5 and E6 gene expression and DNA in situ fragmentation findings associated with progressive and regressive changes in benign neoplastic cutaneous lesions arising naturally from bovine papillomavirus-1 infection. *Medycyna Weterynaryjna* 72, 549-557. [\[Crossref\]](#)
- Alcigir, M.E., Timurkan, M.O., 2018. The association between insulin-like growth factors I, II and bovine papillomavirus type-1 expressions in naturally occurring bovine fibropapilloma cases. *Ankara Üniversitesi Veteriner Fakültesi Dergisi* 65, 115-122. [\[Crossref\]](#)
- Archana, S.N., Prasad, A., Davis, J., Seena, T.X., 2019. Bovine papillomatosis and its treatment under farm condition. *International Journal of Current Microbiology and Applied Sciences* 8, 2880-2884. [\[Crossref\]](#)
- Ataseven, V. S., Kanat, Ö., Ergün, Y., 2016. Molecular identification of bovine papillomaviruses in dairy and beef cattle: First description of Xi-and Epsilonpapillomavirus in Turkey. *Turkish Journal of Veterinary and Animal Sciences* 40, 757-763. [\[Crossref\]](#)
- Atasever, A., Cam, Y., Atalay, O., 2005. Bir siğir sürüsünde deri papillomatosis olguları. *Ankara Üniversitesi Veteriner Fakültesi Dergisi* 52, 197-200.
- Bredal, W.P., Thoresen, S.I., Rimstad, E., Aleksandersen, M., Nafstad, P.H., 1996. Diagnosis and clinical course of canine oral papillomavirus infection. *Journal of Small Animal Practice* 37, 138-142. [\[Crossref\]](#)
- Borges, O.M.M., Araújo, C.L.M., Ramalho, G.C., da Silva, R.M.N., Tanikawa, A., de Souza, A.P., 2017. Effects of autohemotherapy on hematologic parameters and morphology of canine oral papillomatosis. *Acta Scientiae Veterinariae* 45, 1-6.
- Chand, N., Sirohi, A.S., Tyagi, S., 2018. Autohemotherapy for management of cutaneous papillomatosis in a bull. *Intas Polivet* 19, 96-98. Retrieved from <https://link.gale.com/apps/doc/A563571908/AONE?u=googlescholar&sid=AONE&xid=470c585f>. Accession date: 21.01.2019
- Dagalp, S.B., Dogan, F., Farzani, T.A., Salar, S., Bastan, A., 2017. The genetic diversity of bovine papillomaviruses (BPV) from different papillomatosis cases in dairy cows in Turkey. *Archives of Virology* 162, 1507-1518. [\[Crossref\]](#)
- Daudt, C., da Silva, F.R., Cibulski, S.P., Streck, A.F., Laurie, R.E., Munday, J.S., Canal, C.W., 2019. Bovine papillomavirus 24: a novel member of the genus Xipapillomavirus detected in the Amazon region. *Archives of Virology*, 164, 637-641. [\[Crossref\]](#)
- Flemming, A., 2017. Tumour immunology: Immune atlas sheds light on anticancer responses. *Nature Reviews Immunology* 17, 347. [\[Crossref\]](#)
- Hall, T., Biosciences, I., and Carlsbad, C., 2011. BioEdit: An important software for molecular biology. *GERF Bulletin of Biosciences* 2, 60-61.
- Kale, M., Saltik, H.S., Hasircioglu, S., Yildirim, Y., Yavru, S., Mamak, N., Atli, K., 2019. Treatment of Bovine papillomavirus-induced teat warts in a cow by using Podophyllin magistral formula and autologous vaccine applications together. *Indian Journal of Animal Research* 53, 832-836. [\[Crossref\]](#)
- Kirmizigül, A.H., Gökçe, E., Sozmen, M., Yildirim, Y., Beytut, E., 2010. İvermektin'in siğir deri papillomatosisinde tedavi etkinliği. *Kafkas Üniversitesi Veteriner Fakültesi Dergisi* 16, 627-631.
- Le Net, J.L., Orth, G., Sundberg, J.P., Cassonnet, P., Poisson, L., Masson, M.T., George, C., Longeart, L., 1997. Multiple pigmented cutaneous papules associated with a novel canine papillomavirus in an immunosuppressed dog. *Veterinary Pathology* 34, 8-14. [\[Crossref\]](#)
- Lucroy, M.D., Hill, F.I., Moore, P.F., Madewell, B.R., 1998. Cutaneous papillomatosis in a dog with malignant lymphoma following long-term chemotherapy. *Journal of Veterinary Diagnostic Investigation* 10, 369-371. [\[Crossref\]](#)
- Mansell, A., Jenkins, B.J., 2013. Dangerous liaisons between interleukin-6 cytokine and toll-like receptor families: a potent combination in inflammation and cancer. *Cytokine and Growth Factor Reviews* 24, 249-256. [\[Crossref\]](#)
- Melo, T.C., Carvalho, R.F., Mazzucchelli-de-Souza, J., Diniz, N., Vasconcelos, S., Assaf, S.L.M.R., Araldi, R.P., Ruiz, R.M., Kerkis, I., Beçak, W., Stocco, R.C., 2014. Phylogenetic classification and clinical aspects of a new putative Deltapapillomavirus associated with skin lesions in cattle. *Genetics and Molecular Research* 13, 2458-2469. [\[Crossref\]](#)
- Nicholls, P. K., Stanley, M. A., 2000. The immunology of animal papillomaviruses. *Veterinary Immunology and Immunopathology* 73, 101-127. [\[Crossref\]](#)
- Ranjan, R., Ghumman, S.P.S., Bhatt, G.R., Singh, R.S., 2013. Efficacy of autogenous vaccine and auto-hemotherapy in bovine cutaneous papillomatosis. *Intas Polivet* 14, 411-415.
- Rothacker, C.C., Boyle, A.G., Levine, D.G., 2015. Autologous vaccination for the treatment of equine sarcoids: 18 cases (2009-2014). *Canadian Veterinary Journal* 56, 709-714.
- Rose-John, S., 2012. IL-6 trans-signaling via the soluble IL-6 receptor: importance for the pro-inflammatory activities of IL-6. *International Journal of Biological Sciences* 8, 1237-1247. [\[Crossref\]](#)
- Streck, R.E., 2002. A short introduction to papillomavirus biology. *Intervirology* 45, 287-289. [\[Crossref\]](#)
- Tamura, K., Stecher, G., Peterson, D., Filipski, A., Kumar, S., 2013. MEGA6: Molecular evolutionary genetics analysis version 6.0. *Molecular Biology and Evolution* 30, 2725-2729. [\[Crossref\]](#)
- Tan, M.T., Yildirim, Y., Sozmen, M., Dagalp, S.B., Yilmaz, V., Kirmizigül, A.H., Gökçe, E., 2012. A histopathological, immunohistochemical and molecular study of cutaneous bovine papillomatosis. *Kafkas Üniversitesi Veteriner Fakültesi Dergisi* 18, 739-744. [\[Crossref\]](#)
- Timurkan, M. O., Alcigir, M. E., 2017. Phylogenetic analysis of a partial L1 gene from bovine papillomavirus type 1 isolated from naturally occurring papilloma cases in the northwestern region of Turkey. *The Onderstepoort Journal of Veterinary Research* 84, e1-e6. [\[Crossref\]](#)