

## RESEARCH ARTICLE

# Immunohistochemical Assessment of MDA and 8-OHdG Expression in the Skin, Lungs and Kidneys of Lambs Naturally Infected with Sheepox Virus Confirmed with PCR

Emin KARAKURT <sup>1(\*)</sup> , Nüvit COŞKUN <sup>2</sup> , Enver BEYTUT <sup>1</sup> , Serpil DAĞ <sup>1</sup> ,  
Volkan YILMAZ <sup>2</sup> , Hilmi NUHOĞLU <sup>1</sup> , Ayfer YILDIZ <sup>1</sup> , Emre KURTBAŞ <sup>3</sup> 

<sup>1</sup> Faculty of Veterinary Medicine, Kafkas University, Department of Pathology, TR-36100 Kars - TÜRKİYE

<sup>2</sup> Faculty of Veterinary Medicine, Kafkas University, Department of Virology, TR-36100 Kars - TÜRKİYE

<sup>3</sup> Institute Health Sciences, Kafkas University, TR-36100 Kars - TÜRKİYE



(\*) **Corresponding author:** Emin KARAKURT

Phone: +90 474 242 6836/5152

Cellular phone: +90 506 702 1110

Fax: +90 474 242 6853

E-mail: mehmeteminkarakurt@hotmail.com

How to cite this article?

Karakurt E, Coşkun N, Beytut E, Dağ S, Yılmaz V, Nuhoglu H, Yıldız A, Kurtbaş E: Immunohistochemical assessment of MDA and 8-OHdG expression in the skin, lungs and kidneys of lambs naturally infected with sheepox virus confirmed with PCR. *Kafkas Univ Vet Fak Derg*, 29 (5): 483-490, 2023.  
DOI: 10.9775/kvfd.2023.29448

Article ID: KVFD-2023-29448

Received: 25.03.2023

Accepted: 11.08.2023

Published Online: 04.09.2023

## ABSTRACT

This study aimed to assess the role of free radicals in the pathogenesis and progression of sheepox with the immunohistochemical investigation of MDA and 8-OHdG expressions. The study material comprised of 24 lamb carcasses (suspected of being infected with sheepox), which were referred to the Pathology Department for routine diagnosis, and 6 healthy lambs used for control purposes. Commercial MDA and 8-OHdG were used for labeling with the avidin-biotin-Peroxidase complex technique by the manufacturer's instructions. By using PCR the correct-sized amplicon was obtained from eight of the samples. Characteristic pox nodules were detected in the skin, lung, and liver tissues. In histopathological examinations, sheepox cells and Guarneri bodies, which are quite typical for the diagnosis of the disease, were found in the internal organs. All of the sheepox-infected cases yielded positive results for MDA and 8-OHdG immunostainings. When compared to the control group, the sheepox-infected group displayed statistically higher levels of MDA and 8-OHdG expressions. In conclusion, increased MDA and 8-OHdG expressions in the visceral organs of lambs naturally infected with the sheepox virus demonstrated that sheepox is associated with the disruption of the antioxidant/oxidant balance and the occurrence of significant oxidative stress-induced damage to macromolecules such as lipids and the DNA. The positive correlation detected between the severity of the disease and the expression of these biomarkers showed that free radicals are actively involved in the development of pox lesions.

**Keywords:** Free radicals, Immunohistochemistry, Lipid peroxidation, Oxidative stress, Sheepox virus

## INTRODUCTION

Sheepox is a highly contagious viral disease of sheep <sup>[1,2]</sup>. The causative agent of the disease, the sheepox virus (SPPV), together with the goatpox virus (GTPV) and lumpy skin disease virus (LSDV), belongs to the genus Capripoxvirus, which is classified under the family Poxviridae <sup>[3]</sup>. The disease is spread primarily by inhalation. Nonetheless, the causative viral agent may also be transmitted mechanically by infected animals and insect bites, and through contact with contaminated material. Experimental infection can be induced by intradermal and subcutaneous injections <sup>[4]</sup>. The clinical manifestation of the disease may range from moderate to

severe, depending on viral factors and the host status <sup>[5]</sup>. Sheepox is characterized by fever, conjunctivitis, rhinitis, dyspnea, generalized and internal pox lesions, and lymphadenopathy <sup>[6]</sup>. The typical lesions of the disease are localized mainly to the skin <sup>[7,8]</sup>. However, in cases of systemic infection, lesions also occur in the visceral organs, including among others, the lungs, kidneys, liver, heart, adrenal glands, thyroid, and pancreas <sup>[9]</sup>. Skin lesions are of either papulovesicular or nodular form and are localized particularly to the inguinal region, axillar region, underneath the tail, perineum, face, ears, lips and periocular region <sup>[10]</sup>. While sheepox occurs in animals of all ages, the mortality rate of the disease may rise to 80-100% mostly in young animals <sup>[11]</sup>.



Although having been eradicated in Europe, sheepox still exists in several African (except South Africa) and Asian countries, including Turkey<sup>[12,13]</sup>. Being the cause of mortality, stillbirth, abortion, decreased milk production, wool and leather quality, sheepox results in major economic losses in the international trade of animals and animal products<sup>[14,15]</sup>. Thus, sheepox is classified by the World Organization for Animal Health (OIE) as a notifiable disease, which has a potential for very serious and rapid spread and requires primary and immediate control<sup>[2,6,16]</sup>.

In a healthy organism, there is a balance between oxidants and antioxidants. The disruption of this balance in favor of oxidants results in the development of oxidative stress<sup>[4]</sup>. Oxidative stress leads to the generation of free radicals<sup>[5]</sup>. Free radicals attack macromolecules such as lipids, carbohydrates, proteins, and nucleic acids, and thereby, cause oxidative damage<sup>[4,17]</sup>. Malondialdehyde (MDA), the end-product of the oxygenation of polyunsaturated fatty acids, is a highly reliable biomarker used for the detection of lipid peroxidation<sup>[18,19]</sup>. MDA is one of the major molecules involved in free radical-induced cell degeneration<sup>[5,6]</sup>. On the other hand, 8-hydroxy-2'-deoxyguanosine (8-OHdG) is one of the most common parameters used to assess reactive oxygen species (ROS)-induced DNA oxidation<sup>[20]</sup>.

This study was aimed at the immunohistochemical investigation of MDA and 8-OHdG expression to assess the role of free radicals in the pathogenesis and progression of sheepox.

## MATERIAL AND METHODS

### Ethics Board Approval

This study was conducted under the approvals of the General Directorate for Food and Control of the Ministry of Agriculture and Forestry of the Republic of Türkiye (E-71037622-325.01-7907977) and the Local Ethics Board for Animal Experiments of Kafkas University (KAÜ-HADYK-2021/065).

### Animals

The study material comprised 24 lamb carcasses (suspected of being infected with sheepox), which were referred to the Pathology Department of Kafkas University Faculty of Veterinary Medicine for routine diagnosis, and 6 healthy lambs used for control purposes.

### Molecular Methods

Paraffin-embedded tissue blocks were used as the material for nucleic acid extraction. Ten-micrometer-thick sections were cut from the blocks and placed into 1.5-mL polystyrene tubes. Extraction was performed as described by Pikor et al.<sup>[21]</sup>. The polymerase chain reaction (PCR) technique was employed for the investigation of the presence of Capripox virus nucleic acids. Primer pairs targeting the conservative A4L gene homologue were chosen. Forward primer and reverse designs are 5'-GGCCATGGCGATGGACTTCATGAAAAAATATAC-3' and 5'-GGAAGCTTTTGTGCTGTTATATCATCTAG-3' respectively. PCR was performed with PCR Master Mix (Hibrogen, Türkiye), 10 picomols of each primer and 3 µL of template DNA under optimized cycling parameters: 95°C for 5 min, 35 cycles of denaturation (95°C for 45 sec), annealing (53°C for 45 sec) and extension (72°C for 1 min), followed by a final extension step at 72°C for 10 min<sup>[22]</sup>. The expected amplicon size was 486 bp. PCR products were visualized on an UV transilluminator after running electrophoresis in 1% agarose gel containing the Safe-Red DNA stain (Safe View™ Cat No: G108-R, Canada).

### Histopathological Examination

Tissue samples taken at the systemic necropsy of the animals were fixed in a 10% formaldehyde solution for 24-48 h. After routine tissue processing, 5-micrometer-thick serial sections were cut from the paraffin blocks on a rotary microtome. For the examination of the histopathological findings in the tissue samples, the sections were stained with hematoxylin and eosin (H&E). The sections were examined under a light microscope and pox-associated findings were imaged with a digital camera attached to the microscope.

### Immunohistochemical Examination

Four-micrometer-thick serial sections, cut from the paraffin-embedded tissue blocks, were stained with the avidin-biotin-peroxidase complex (ABC) technique using commercial anti-MDA and anti-8-OHdG antibodies in accordance with the manufacturer's instructions. The clone numbers, incubation periods, and dilution rates of the primary antibodies used in this study are presented in [Table 1](#). All immune labeling were performed using the Thermo Scientific Histostain IHC Kit (HRP, broad-spectrum, REF: TP-125-HL). Amino-ethyl carbazole (AEC, Thermo Scientific, REF: TA-125-HA) was used as a chromogenic substrate and was incubated for 15 min. The

**Table 1.** Information on the primary antibodies used in the immunohistochemical stainings

Primary Antibodies	Pretreatment	Company and Catalogue Numbers	Dilution	Incubation Conditions
MDA	Microwave open	Abcam, ab6463, Polyclonal	1/1500	Overnight, 4°C
8-OHdG	Microwave open	Bioss Antibodies, bs-1278R, Polyclonal	1/1500	Overnight, 4°C

slides were washed with distilled water for 5 min before being stained with Mayer's hematoxylin. Next, the slides were coverslipped with an AEC-mounting solution.

The preparations were examined under a light microscope (Olympus Bx53) and were imaged with the Cell ^P software (Olympus Soft Imaging Solutions GmbH, 3,4). Detailed analyses of the images were made with the Image J software (1.51j8).

The results of the immunohistochemical staining were analyzed with a scoring system. System is based on the number of positive cells in the regions displaying the most intense staining as identified by the assessment of immunopositive reactions. For each tissue section, three different areas were examined at 50x magnification. The number of cells displaying positive staining was recorded for each area. Then the mean value of the five areas was noted as the mean number of positive cells in that particular case. The scoring was performed as follows: (-) no immunoreactivity; (+) weak, 1-10% positivity; (++) moderate immunoreactivity, 11-59% positivity; (+++) strong immunoreactivity,  $\geq 60\%$  positivity<sup>[23]</sup>.

### Statistical Analysis

The statistical analyses of the results were performed with the SPSS® software (SPSS 26.0, Chicago, IL, USA). The comparison of the control group and the sheeppox-infected group was made with the Mann-Whitney U-test. The results are given as mean  $\pm$  standard error (SE) of the mean. When assessing the results, statistical significance was set at  $P < 0.05$ .

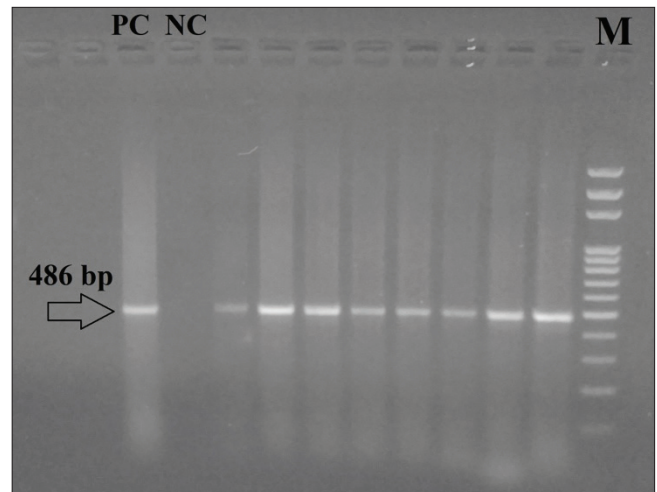
## RESULTS

### Molecular Results

Eight of the samples demonstrated correct sized (approx. 486 bp) amplicon (*Fig. 1*).

### Macroscopic Findings

Papulovesicular skin lesions were localized mostly to regions either lack of fleece or covered with very little fleece. These regions include the ventral surface of the tail, the inner surface of the legs, the preputium, mammary



**Fig 1.** Agarose gel image of the positive samples. Lane marked with M contains the DNA ladder (100 bp plus Thermo-Scientific), PC: Positive Control, NC: Negative Control. Samples 1-8 are placed between the DNA ladder and the negative control

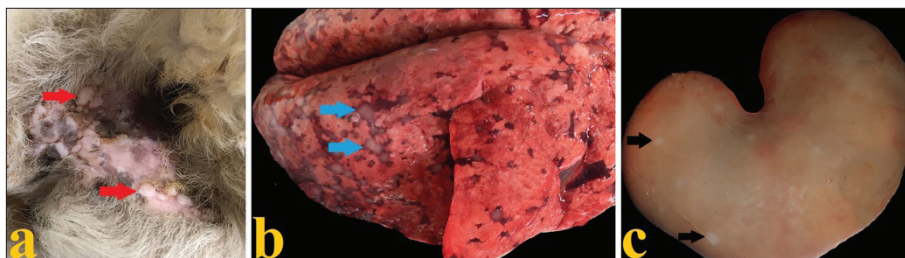
glands, vulva, scrotum, eyelids, bucca and nostrils (*Fig. 2-a*).

Multiple whitish round nodules were observed in the lungs, and particularly in the dorsocaudal lobes. The diameter of the nodules ranged from a few millimeters to 2-3 cm. These nodules were very hard and demarcated from the surrounding normal pulmonary tissue by a hyperemic ring-shaped region (*Fig. 2-b*).

Whitish pale-colored miliary foci of varying size were observed throughout the renal cortex (*Fig. 2-c*).

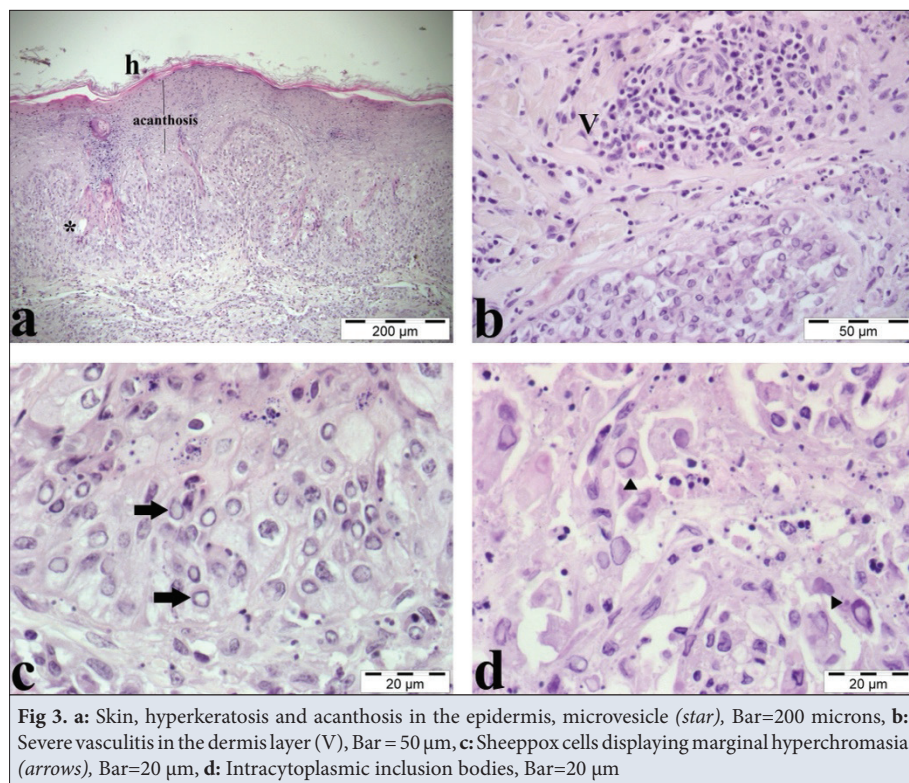
### Microscopic Findings

The epidermis layer of the skin displayed acanthosis, as well as hyperkeratotic and parakeratotic alterations. Furthermore, cells lining the stratum spinosum presented balloon-like hydropic degeneration. Fluid-filled microvesicles, formed by the merge of these degenerated cells after undergoing necrosis, were observed. Degenerated epithelial cells contained intracytoplasmic eosinophilic inclusion bodies, also known as Guarneri bodies. Severe mononuclear cell infiltration was observed in the dermis. The histiocyte-like sheeppox cells (cellules claveleuses),

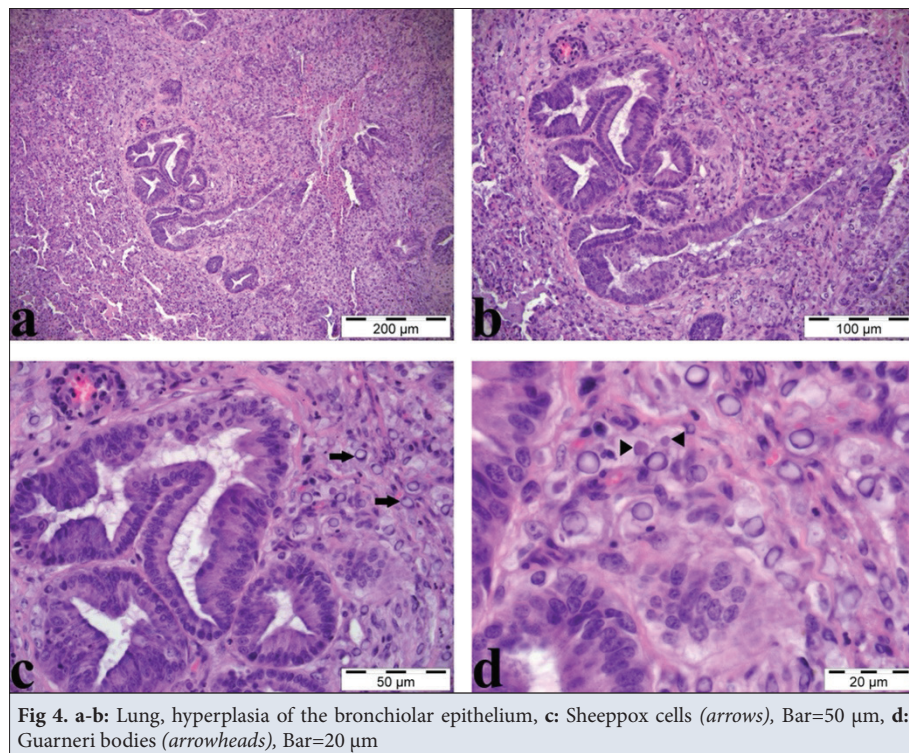


**Fig 2. a:** Papular lesions on the skin and the ventral surface of the tail (red arrows), **b:** Lung, multiple pox nodules, each surrounded by a hyperemic ring and some of which were merged, in the dorsocaudal lobes (blue arrows), **c:** Kidney, pale whitish foci distributed throughout the cortex (black arrows)





**Fig 3.** a: Skin, hyperkeratosis and acanthosis in the epidermis, microvesicle (star), Bar=200 microns, b: Severe vasculitis in the dermis layer (V), Bar = 50 µm, c: Sheeppox cells displaying marginal hyperchromasia (arrows), Bar=20 µm, d: Intracytoplasmic inclusion bodies, Bar=20 µm



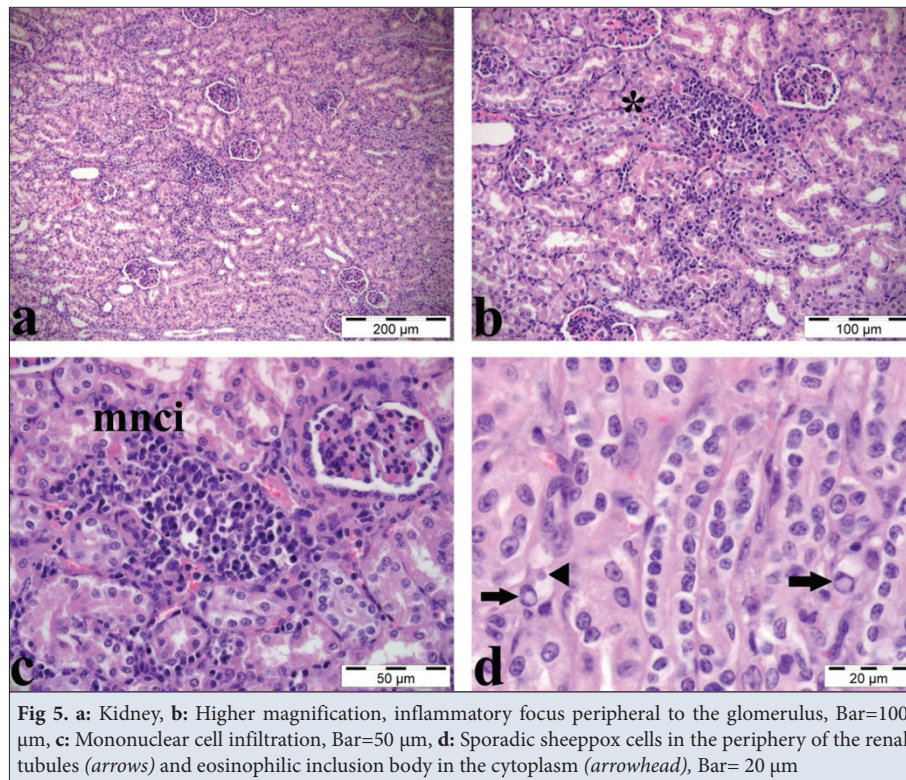
**Fig 4.** a-b: Lung, hyperplasia of the bronchiolar epithelium, c: Sheeppox cells (arrows), Bar=50 µm, d: Guarneri bodies (arrowheads), Bar=20 µm

which are characteristic of the disease and aid in differential diagnosis, presented with marginal hyperchromasia in their nuclei. Eosinophilic inclusion bodies were also detected in the cytoplasm of these cells. Inflammatory cell infiltration, comprised mainly of mononuclear cells, but also of edema, was present. Few neutrophil leukocytes

were detected. Moreover, the dermis also presented with vasculitis (Fig. 3).

The most prominent finding in the lungs was the epithelial hyperplasia of the alveoli, bronchi, and bronchioles. A single layer of cuboidal type-2 pneumocytes lined the alveolar wall, largely. Intracytoplasmic inclusion bodies were





**Fig 5.** a: Kidney, b: Higher magnification, inflammatory focus peripheral to the glomerulus, Bar=100 µm, c: Mononuclear cell infiltration, Bar=50 µm, d: Sporadic sheeppox cells in the periphery of the renal tubules (arrows) and eosinophilic inclusion body in the cytoplasm (arrowhead), Bar= 20 µm

detected in the proliferated epithelial cells of the alveoli and bronchioles. Thickening of the alveolar wall was observed due to the infiltration of mononuclear cells, sheeppox cells, and a few neutrophil leukocytes. The sheeppox cells displaying marginal hyperchromasia had a slightly basophilic cytoplasm. In the proliferated epithelium of the bronchioles, cells with hydropic degeneration presented with both marginal hyperchromasia and inclusion bodies. Perivascular, peribronchial, and peribronchiolar lymphoid cell infiltrations were observed in the areas, to which the lesions were localized. Some cases displayed slight fibrotic changes and alveolar edema (Fig. 4).

The kidneys presented focal nonpurulent interstitial nephritis. Mononuclear cell infiltration was observed in the periphery of the glomeruli and blood vessels. Different from the skin and lungs, the kidneys contained only very few sheeppox cells (Fig. 5).

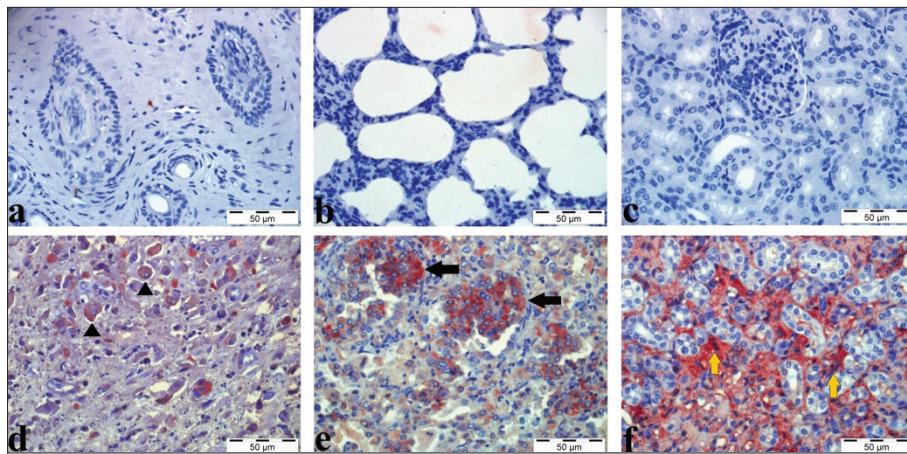
### Immunohistochemical Findings

Although at low levels, MDA and 8-OHdG expressions were detected in the healthy pulmonary tissues of the control animals. All of the sheeppox-infected cases yielded positive results for MDA and 8-OHdG immunostainings. When compared to the control group, the sheeppox-infected group displayed statistically higher levels of MDA and 8-OHdG expressions (Table 2). Stainings for these two oxidative stress markers were much more intense in cases with more severe disease-related pathological findings. MDA-positive stainings were

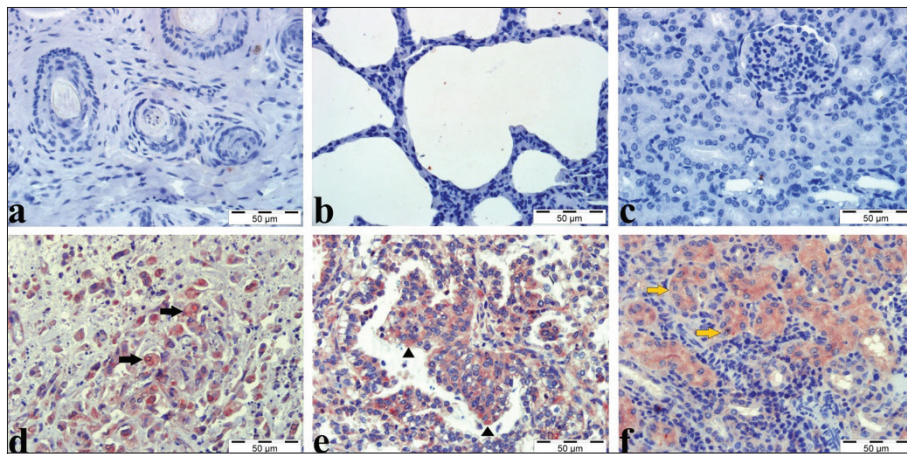
detected mostly in the cytoplasm of the sheeppox cells in the dermis layer. Apart from these cells, mononuclear cells that had infiltrated into the same layer were also positive for MDA immunoreactivity. MDA expression was also detected in the degenerated keratinocytes of the epidermis. In the lungs, inflammatory cells in the interalveolar septa, as well as alveolar macrophages and the sheeppox cells displayed cytoplasmic MDA-positive staining. Moreover, proliferated epithelial cells of the bronchi and bronchioles were also identified as being immunopositive for MDA expression. In the kidneys, mostly the interstitial cells displayed MDA expression. Positive stainings were observed in very few mononuclear cells in the inflammatory foci. Weak reactions were present in the epithelium of the degenerated and necrosed renal tubules (Fig. 6). 8-OHdG-positive stainings were most intense in the cytoplasm of the sheeppox cells found in the skin, and particularly in the epidermis. Apart from these cells, degenerated cells of the stratum spinosum and mononuclear cells also displayed intracytoplasmic reactions. In the lungs, positive stainings were localized particularly to the cytoplasm of the proliferated epithelial

**Table 2.** Mean  $\pm$  standard error values of the sheeppox-infected and control groups

Groups	8-OHdG	MDA
Control	0.33 $\pm$ 0.21	0.50 $\pm$ 0.22
Sheeppox-infected	1.96 $\pm$ 0.14	2.63 $\pm$ 0.10
P value	0.0003	0.0001



**Fig 6.** a: Control group, skin, Bar=50 µm, b: Control group, lung, Bar=50 µm, c: Control group, kidney, Bar=50 µm d: Sheppox-infected group, skin, intracytoplasmic MDA-positive staining in the sheppox cells (arrowheads), Bar=50 µm, e: Sheppox-infected group, lung, strong MDA expression in the cytoplasm of sheppox cells in the proliferated bronchioles (black arrows), Bar=50 µm, f: Sheppox-infected group, kidney, intracytoplasmic MDA-immunoreactivity in cells localized to the interstitium (yellow arrows), Bar=50 µm



**Fig 7.** a: Control group, skin, Bar=50 µm, b: Control group, lung, Bar=50 µm, c: Control group, kidney, Bar=50 µm, d: Sheppox-infected group, skin, 8-OHdG-immunoreactivity in the cytoplasm of sheppox cells displaying marginal hyperchromasia in the dermis layer (black arrows), Bar=50 µm, e: Sheppox-infected group, lung, intracytoplasmic 8-OHdG-positive staining in the proliferated epithelial cells of the bronchioles, Bar=50 µm, f: Sheppox-infected group, kidney, 8-OHdG expression in degenerated tubular epithelium (yellow arrows), Bar=50 µm

cells lining the bronchi and bronchioles. Moreover, the inflammatory cells and sheppox cells in the alveolar wall also reacted positively for 8-OHdG expression. In the kidneys, 8-OHdG immunoreactivity was predominant in the cytoplasm of the epithelial cells lining the degenerated tubules. Furthermore, mononuclear cells presented with weak reactions (Fig. 7).

## DISCUSSION

Free radicals play an important role in the pathogenesis of many diseases, and several viruses, including poxviruses, are known to increase the generation of free radicals [5]. Previous research has demonstrated that while poxviruses cause damage to visceral organs, oxygen-based reactants play an active role in this damage [24]. Literature review

showed that there are reports on the blood MDA levels of sheep naturally infected with the sheppox virus [4-6,18]. In the present study, it was determined that, compared to the control animals with no pathological lesions, the animals naturally infected with sheppox displayed significantly higher levels of MDA expression in the dermal, pulmonary, and renal tissues. Blood levels reported in previous research [4-6,18] confirm the results of the present study. Moreover, MDA expression was ascertained to increase in parallel with the severity of lesions and inflammatory infiltration in the visceral organs in lambs. These findings suggest that free radical-induced lipid peroxidation is involved in the progression of organ damage associated with sheppox.

By interacting with DNA, ROS cause the generation of



more than 20 products of oxidative base damage. Among these products, 8-OHdG is one of the most common biomarkers used to detect oxidative stress-induced DNA damage [25-27]. It is considered that the increased expression of 8-OHdG may be associated with poor prognosis in several types of cancer [28]. In multiple studies carried out in human medicine, the hepatitis B and C viruses, herpes simplex virus (HSV), and human immunodeficiency virus (HIV) have been reported to trigger oxidative stress, and it has also been indicated that individuals infected with these viruses display significantly increased levels of 8-OHdG [29-33]. The present study is valuable in that it provides data on the detection of oxidative stress-induced DNA damage in cases of sheeppox infection. As was the case with lipid peroxidation, 8-OHdG-positive stainings were observed to be more intense in cases with severe lesions, localized particularly to the proliferated epithelia of the bronchi and bronchioles. Based on these findings, it is evident that in cases of infection with the sheeppox virus, ROS-induced DNA damage occurs in the skin and several visceral organs including the lungs and kidneys.

In conclusion, increased MDA and 8-OHdG expressions in the visceral organs of lambs naturally infected with the sheeppox virus demonstrated that sheeppox is associated with the disruption of the antioxidant/oxidant balance and the occurrence of significant oxidative stress-induced damage to macromolecules such as lipids and the DNA. The positive correlation detected between the severity of the disease and the expression of these biomarkers showed that free radicals are actively involved in the development of pox lesions.

#### Availability of Data and Materials

The authors declare that the data that support the findings of this study are available from the corresponding author (E. Karakurt), upon reasonable request.

#### Acknowledgements

The authors thank Dr. Mushap Kuru for his contribution to the statistical analysis

#### Financial Support

This research was not funded financially by any institution or company.

#### Competing Interest

The authors have no conflicts of interest to declare. All co-authors have seen and agree with the contents of the manuscript and there is no financial interest to report. We certify that the submission is original work and is not under review at any other publication

#### Authorship Contribution

Histopathological and immunohistochemical stainings: HN, AY, EKü, Histopathological and immunohistochemical analysis: EB, SD, EKü, Molecular analysis: NC, VY, Idea, concept, and writing the article: EKü, NC

## REFERENCES

1. Haligur M, Ozmen O: Immunohistochemical demonstration of caspase inhibition in skin and visceral organ lesions in naturally occurring sheep poxvirus infection. *Isr J Vet Med*, 71 (4): 21-26, 2016.
2. Karapinar Z, İlhan F, Dincer E, Yildirim S: Pathology and phylogenetic analysis of capripoxvirus in naturally infected sheep with sheeppox virus. *Pak Vet J*, 37 (1): 78-84, 2017.
3. Hasoksuz M, Gulyaz V, Sarac F: Molecular characterizations of sheeppox virus strains. *İstanbul Üniv Vet Fak Derg*, 40 (1): 95-102, 2014.
4. Issi M, Gul Y, Yilmaz S: Clinical, haematological and antioxidant status in naturally poxvirus infected sheep. *Revue Méd Vét*, 159 (1): 54-58, 2008.
5. Bozukluhan K, Merhan O, Gökçe Hİ, Ögün M, Atakişi E, Kızıltepe Ş, Gökçe G: Determination of some acute phase proteins, biochemical parameters and oxidative stress in sheep with naturally infected Sheeppox virus. *Kafkas Univ Vet Fak Derg*, 24 (3): 437-441, 2018. DOI: 10.9775/kvfd.2017.19167
6. Kirmizigül AH, Ogun M, Ozen H, Erkilic EE, Gokce E, Karaman M, Kukurt A: Oxidative stress and total sialic acid levels in sheep naturally infected with pox virus. *Pak Vet J*, 36 (3): 312-315, 2016.
7. Milli ÜH, Alçığır G, Altınsoy MS: Koyun çiçeğinde akciğer lezyonlarının ışık ve electron mikroskopik incelenmesi. *Ankara Üniv Vet Fak Derg*, 38 (1-2): 138-163, 1991.
8. Haligur M, Ozmen O: Immunohistochemical detection of matrix metalloproteinases (MMP) and epidermal growth factor receptor (EGFR) during sheep pox infection. *Revue Méd Vét*, 160 (12): 574-581, 2009.
9. Gulbahar MY, Cabalar M, Gul Y, Icen H: Immunohistochemical detection of antigen in lamb tissues naturally infected with sheeppox virus. *J Vet Med B Infect Dis Vet Public Health*, 47 (3): 173-181, 2000. DOI: 10.1046/j.1439-0450.2000.00321.x
10. Sağnak O, Çakır L: Koyun çiçeği ve bulaşıcı ektima (ORF) enfeksiyonu tanısı konulmuş koyunlara ait deri lezyonlarında matriks metalloproteinaz ve vasküler endotelial gelişme faktörünün immunohistokimyasal teknikle saptanması. *ERÜ Sağlık Bilimleri Dergisi*, 23 (2): 86-91, 2014.
11. Erokşuz Y, Bulut H, Gulacti I, Ceribasi AO: Seasonal distribution of sheeppox cases in lambs in eastern Turkey. *J Anim Vet Adv*, 7 (5): 638-642, 2008.
12. Sözdutalmaz İ, Bulut H: Koyun-keçi çiçeği hastalığının polimeraz zincir reaksiyonu ile tanısında farklı klinik örneklerin kullanımı. *Atatürk Üniv Vet Bil Derg*, 5 (3): 113-119, 2010.
13. Şener R, Türk T: Spatiotemporal and seasonality analysis of sheep and goat pox (SGP) disease outbreaks in Turkey between 2010 and 2019. *Trop Anim Health Prod*, 55 (2):65, 2023. DOI: 10.1007/s11250-023-03487-6
14. Yazici Z, Oguzoglu TC, Gumusova SO: Detection and phylogenetic analysis of local capripoxvirus from necropsy specimens of sheep suspected of sheeppox infection. *Vlaams Diergeneesk Tijdschr*, 77 (78): 97-100, 2008.
15. Hamdi J, Bamouh Z, Jazouli M, Boumart Z, Tadlaoui KO, Fihri OF, El Harrak M: Experimental evaluation of the cross-protection between Sheeppox and bovine Lumpy skin vaccines. *Sci Rep*, 10 (1): 8888, 2020. DOI: 10.1038/s41598-020-65856-7
16. Wolff J, Beer M, Hoffmann B: Cross-protection of an inactivated and a live-attenuated lumpy skin disease virus Vaccine against sheeppox virus infections in sheep. *Vaccines (Basel)*, 11 (4):763, 2023. DOI: 10.3390/vaccines11040763
17. Merhan O, Bozukluhan K, Kuru M, Büyük F, Özden Ö, Kükürt A: Investigation of oxidative stress index and lipid profile in cattle with Brucellosis. *Kafkas Univ Vet Fak Derg*, 23 (6): 933-937, 2017. DOI: 10.9775/kvfd.2017.18004
18. Cam Y, Atalay Ö, Atasever A: Plasma malondialdehyde level and erythrocyte catalase activity in lambs and ewes infected with sheep pox. *Indian Vet J*, 86, 525-526, 2009.
19. Kuru M, Ögün M, Kulaksız R, Kükürt A, Oral H: Comparison of oxidative/nitrosative stress, leptin and progesterone concentrations in pregnant and non-pregnant Abaza goats synchronized with controlled internal drug release application. *Kafkas Univ Vet Fak Derg*, 24 (6): 887-892,

2018. DOI: 10.9775/kvfd.2018.20222

20. Çenesiz S: The role of oxidant and antioxidant parameters in the infectious diseases: A systematic literature review. *Kafkas Univ Vet Fak Derg*, 26 (6): 849-858, 2020. DOI: 10.9775/kvfd.2020.24618

21. Pikor LA, Enfield KS, Cameron H, Lam WL: DNA extraction from paraffin embedded material for genetic and epigenetic analyses. *J Vis Exp*, (49): 2763, 2011. DOI: 10.3791/2763

22. Madhavan A, Venkatesan G, Kumar A, Arya S, Pandey AB: Comparative sequence and structural analysis of the ORF095 gene, a vaccinia virus A4L homolog of capripoxvirus in sheep and goats. *Arch Virol*, 165 (6): 1419-1431, 2020. DOI: 10.1007/s00705-020-04623-5

23. Karakurt E, Nuhoglu H, Dağ S, Çelebi Ö, Büyük F, Beytut E, Yıldız A, Kuru M, Akça D: Immunohistochemical investigation of TNF- $\alpha$  and IFN- $\gamma$  expressions in sheep fetuses with brucellosis. *Pak Vet J*, 43 (1): 85-90, 2023. DOI: 10.29261/pakvetj/2022.088

24. Hernández JA, Talavera JM, Martínez-Gómez P, Dicenta F, Sevilla F: Response of antioxidative enzymes to plum pox virus in two apricot cultivars. *Physiol Plant*, 111 (3): 313-321, 2001. DOI: 10.1034/j.1399-3054.2001.1110308.x

25. Atmaca E, Aksoy A: Oksidatif DNA hasarı ve kromatografik yöntemlerle tespit edilmesi. *Van Vet J*, 20 (2): 79-83, 2009.

26. Özcan O, Erdal H, Çakırca G, Yönden Z: Oksidatif stres ve hücre içi lipid, protein ve DNA yapıları üzerine etkileri. *J Clin Exp Invest*, 6 (3): 331-336, 2015. DOI: 10.5799/ahinjs.01.2015.03.0545

27. Karakurt E, Kuru M, Dağ S, Beytut E, Oral H, Hilmi H, Yıldız A: Presence and importance of oxidative stress parameters in malignant

mammary gland tumors in dogs. *Kafkas Univ Vet Fak Derg*, 27 (4): 517-523, 2021. DOI: 10.9775/kvfd.2021.25919

28. Karakurt E, Beytut E, Dağ S, Nuhoglu H, Yıldız A, Kurtbaş E: Assessment of MDA and 8-OHdG expressions in ovine pulmonary adenocarcinomas by immunohistochemical and immunofluorescence methods. *Acta Vet Brno*, 91 (3): 235-241, 2022. DOI: 10.2754/avb202291030235

29. Chuma M, Hige S, Nakanishi M, Ogawa K, Natsuizaka M, Yamamoto Y, Asaka M: 8-Hydroxy-2'-deoxy-guanosine is a risk factor for development of hepatocellular carcinoma in patients with chronic hepatitis C virus infection. *J Gastroenterol Hepatol*, 23 (9): 1431-1436, 2008. DOI: 10.1111/j.1440-1746.2008.05502.x

30. Kolgiri V, Nagar V, Patil V: Association of serum total bilirubin and plasma 8-OHdG in HIV/AIDS patients. *Interv Med Appl Sci*, 10 (2): 76-82, 2018. DOI: 10.1556/1646.10.2018.02

31. Lin YT, Liu W, He Y, Wu YL, Chen WN, Lin XJ, Lin X: Hepatitis B Virus X protein increases 8-Oxo-7,8-Dihydro-2'-Deoxyguanosine (8-Oxodg) level via repressing MTH1/ MTH2 expression in hepatocytes. *Cell Physiol Biochem*, 51 (1): 80-96, 2018. DOI: 10.1159/000495166

32. Xu XM, Zhou XY, Li XY, Guo J, Wang HZ, Li Y, Yang CC, Liu TH, Cai JP: Increased oxidative damage of RNA in liver injury caused by hepatitis B virus (HBV) infection. *Free Radic Res*, 52 (4): 426-433, 2018. DOI: 10.1080/10715762.2018.1439165

33. Zhang L, Wang J, Wang Z, Li Y, Wang H, Liu H: Upregulation of nuclear factor E2-related factor 2 (Nrf2) represses the replication of herpes simplex virus type 1. *Virology*, 19 (1): 23, 2022. DOI: 10.1186/s12985-021-01733-7