



Effects of Amifostine Application on Mucin 1 Secretion in Prostate Tissue of Radiotherapy-treated Rats

Sevda ELİŞ YILDIZ,¹ Arzu GEZER,² Ebru KARADAĞ SARI³

¹Department of Midwifery, Kafkas University Faculty of Health Sciences, Kars-Türkiye

²Department of Health Care Services, Vocational School of Health Services Atatürk University, Erzurum-Türkiye

³Department of Histology, Kafkas University Faculty of Veterinary Medicine, Kars-Türkiye

OBJECTIVE

This experimental study was aimed to assess the positive or negative effects of the radioprotective agent amifostine (AMF) (WR-2721) on mucin 1 (MUC1) through immunohistochemical methods in preventing the damage that may occur in the prostate tissue after radiotherapy (RT).

METHODS

In the experimental period, 32 Sprague-Dawley male rats were divided into 4 groups: Untreated control group, AMF group; 200 mg AMF was intraperitoneally administered to the rats in the second group for 3 days. The rats in the third group (RT-saline) were experimentally administered a total of 6 Gy including 2 Gy of RT in 3 fractions. The rats in the fourth group (RT – AMF) received totally 6 Gy RT and 200 mg/kg AMF for 3 days. The rats were sacrificed for histological assessments 4 weeks after RT. Triple staining was performed to the tissues for histopathological examinations and immunohistochemical localization of MUC1 in prostate tissue was determined using streptavidin-biotin peroxidase method.

RESULTS

Histopathologically, it was observed that the parenchymal and stromal cells of the prostate tissues in all groups had a structurally normal appearance. Immunohistochemically, the MUC1 immunoreactivity was weak in the parenchymal and stromal cells of the control group, and strong MUC1 secretion was observed in the AMF group, AMF RT group, and RT group.

CONCLUSION

When considering the effects of AMF application on MUC1 secretion in the prostate tissue of rats treated with RT, it is thought that the protective effect of AMF may vary in tissues, depending on the dose applied and the number of fractions.

Keywords: Amifostine; mucin 1; prostate; radiotherapy; rat.

Copyright © 2023, Turkish Society for Radiation Oncology

INTRODUCTION

Cancer is one of the foremost health problems of today due to its frequent incidence, high morbidity and mortality and the duration of treatment, cost, and

complications.[1] Radiotherapy (RT) is also used quite frequently besides surgery and chemotherapy in the treatment of cancer. It is known that 50–60% of cancer patients need RT in the course of their disease for curative or palliative purposes.[2] Patients take advan-

Received: February 28, 2023

Accepted: April 11, 2023

Online: May 26, 2023

Accessible online at:

www.onkder.org

Dr. Arzu GEZER

Atatürk Üniversitesi Sağlık Hizmetleri Meslek Yüksekokulu,

Sağlık Hizmetleri Anabilim Dalı,

Erzurum-Türkiye

E-mail: a.gezer25@hotmail.com, arzu.gezer@atauni.edu.tr



tage of the benefits of RT such as not increasing and destroying harmful cells through ionized rays during and after cancer treatment.[3,4] While RT destroys harmful cancer cells by sending rays, it also damages healthy cells. This is the undesirable result of the treatment applied to gain favor.[5,6]

There are a number of radioprotective agents used to protect from the harmful rays of chemotherapy and RT.[7–9] It has been observed that amifostine (AMF) (WR-2721) which is a radioprotective agent reduces the harmful effects of radiation in line with the studies conducted.[5,6] As distinct from the agents used in clinic as various cell protective agents, AMF is not specific to a single organ, but AMF is an organic thiol compound that can affect all organs.[7–9]

Mucins (MUCs) are glycoprotein structures in the cell wall that has functions such as lubricating, secreting, protecting, and maintaining vitality of the cell.[10] These are divided into two including secreted and membrane-bound MUCs. The MUCs, which create secreted gel, include MUC2, MUC5AC, MUC5B, MUC6, MUC7, MUC8, and MUC19. The MUCs bounded to membrane are MUC1, MUC3A, MUC4, MUC12, MUC13, MUC15, MUC16, MUC17, and MUC2-0 which have a single trans-membrane field and a highly cytoplasmic tail.[10,11] MUC1 plays an significant role in the regulation of many cellular features such as cell proliferation, apoptosis, adhesion, and invasion.[10] It has been thought that the MUCs can be benefited from preventing the damage caused by drugs used in the cancer treatment.[12] The relationship of the AMF and MUC requires further study, especially in the treatment of prostate cancer, which is one of the important organs in reproductive development.

Nowadays, it is observed that the treatments such as chemotherapy and RT damaging healthy tissues and cells are increasing due to the increasing number of cancer diseases. In some studies, this harm reducing feature of the AMF has been examined.[13,14] However, it is required to be able to be presented fully and completely. This experimental study aims to evaluate the positive or negative effects of the AMF, which is a radioprotective agent, on MUC1 in preventing the damage that may occur in the prostate tissue after RT with immunohistochemical methods. It is thought that the positive results that will be able to be observed may contribute to the production of drugs and the course of treatment for the cancer diseases that are increasing day by day.

MATERIALS AND METHODS

Animal Material and Care Conditions

All experimental procedures in the study were approved by Kafkas University Animal Experiments local ethics committee (KAÜ-HADYK/ 2018-005).

Subject was from 12-week-old Sprague–Dawley rats reared in Ataturk University Medical Experimental Research and Application Center (ATADEM) randomly selected. A total of 32 male Sprague–Dawley rats with a body weight of 245 ± 22.89 g were used in this study. The rats were fed *ad libitum* pellets and tap water in a room with daylight (12 h of light, 12 h of darkness).

AMF Administration

The AMF substance was administered to the rat in RT - AMF and AMF groups intraperitoneally for 3 days at a dose of 200 mg/kg body weight.[15]

Experimental Design

Creation of the experimental groups:

1. Control group (n=8): The control group was injected with 0.9% saline solution intraperitoneally (i.p.) 0.5 mL/day for 3 days
2. AMF group (n=8): The rats in this group were administered only AMF intraperitoneally at a dose of 200 mg/kg for 3 days
3. RT-saline (RT-saline) group (n=8): The rats in this group were given only RT at a total dose of 6 Gy in 3 fractions for 3 days as 2 Gy in a single fraction per day
4. RT-AMF (RT-AMF) group (n=8): The rats in this group were administered 200 mg/kg of AMF intraperitoneally half an hour before each daily fraction to create prophylaxis. A daily dose of 2 Gy radiations was applied half an hour after this administration. These processes were repeated in the same amount and manner for 3 days.

The dose and application of AMF were based on the report by Gezer and Karadag-Sari.[16] Lead plates were used to shield tissues outside the irradiated area.[17]

Then, the rats in the whole group were deeply taken to anesthetize by the injection of 40 mg/kg ketamine (Ketalar; Pfizer, İstanbul Türkiye) and 10 mg/kg xylazine (Rompun; Bayer, İstanbul, Türkiye) and the prostate tissue samples was taken via cervical dislocation.

Histopathological Examination

To determine the immunoreactivity of MUC1 in prostate tissues from rats, it was detected in 10% formaldehyde solution and it was stained with Crossman's triple staining evaluate the overall structure of the tissue.

Immunohistochemical Examination

The streptavidin-biotin-peroxidase technique was used to determine the immunoreactivity of MUC1 in prostate tissues from rats. The sections in 5 µm thick were taken from the paraffin blocks on the slides coated with chrome alum gelatin. After deparaffinization and rehydration procedures, the sections were shaken in PBS (0.1 M, PH, 7.2) and incubated for 10 min in 3% H₂O₂ prepared in 0.1 M PBS to prevent endogenous peroxidase activity. After washing with PBS, heat was applied at maximum temperature in the citrate buffer solution in a microwave oven for 10 min to reveal the antigens. Blocking solution A was dripped to prevent non-specific binding. Then, the MUC1 primary antibody (ab104978, diluted 1/50) was administered on the sections for 1 h at room temperature and in a humid environment. Then, broad spectrum antibody against the strain from which the primary antibody was produced was added on the sections and kept at room temperature for ten minutes. After HRP, streptavidin was incubated at room temperature for 10 min. 3,3'-Diaminobenzidine tetrahydrochloride was used as chromogen. It was dipped in Mayer's hematoxylin for 10 sec for counter-staining, the preparations were examined under a light microscope, and their photographs were taken. For the purpose of determining whether the immunoreactivities are specific to the prostate sections taken from all groups, all procedures were kept in PBS without the addition of primary antibody (omission control) and the other procedures were applied the same.

The percentage of the stained cells in the sections and the degree of staining were scored with a semi-quantitative method in the field as criteria. The immunohistochemical evaluations were made by looking at whether the target cells were stained or not. Evaluation done by two independent observers by giving values from 0 to 3 according to non-staining (-), weak (+), moderate (++), and strong (+++) staining characteristics.[18,19]

RESULTS

Histopathological Results

There was a thick fibroelastic connective tissue capsule in the outer part of the prostate gland and this capsule continued with the connective tissue stroma. The secretory part of the prostate gland, which contains smooth muscles and blood vessels in the stroma, consisted of gland structures of various shapes. It was observed that the epithelium of some of the gland structures was cubic and low prismatic. It was observed that the parenchyma

cells and stroma cells of the prostate tissues in the whole group had a structurally normal appearance (Fig. 1a-d).

Immunohistochemical Results

The prostate tissues taken from the control, AMF, RT-saline, and RT-AMF groups were evaluated immunohistochemically. It was determined that the MUC1 immunoreactivity in parenchyma and stroma cells of the control group was weaker than AMF, RT-saline, and RT-AMF groups (Fig. 2a-d).

DISCUSSION

Although RT is a widely used treatment method in cancer treatment, it also damages healthy tissues adjacent to the tumor since it is not selective to tumoral tissue and its acute and late side effects affect quality of life. The radioprotective agents have been developed to prevent these side effects that occur in the cancer patients whose survival times are getting longer.[20] AMF is one of them. The radioprotectants such as AMF reduce the efficacy of radiation in normal cells without reducing the efficacy of radiation in tumors.[21]

The effects of radiation, which is a chromosomal mutagen, on fertility are known. For this reason, the side effects in the reproductive system in young male patients who are treated with RT and who live for a long time are of particular importance.[22] The MUCs are high molecular weight glycoproteins. The MUCs are found on the apical surface of many of the respiratory, reproductive tracts, and gastrointestinal.[23] Lubrication and moistening, protections against epithelial, and microbial attack are among the primary functions of the MUC1. [24] There is increasing interest in MUCs in many cancers, including prostate cancer and the role of their expression in prostate cancer progression is unclear.[25]

Prostate cancers is leading the course of deaths from lightning strikes in recent years. A typical feature of prostate cancer is the presence of genetic changes that alter the expression patterns of many molecules in prostate epithelial cells where the disease arises. These aberrantly expressed proteins are tumor-associated antigens.[26]

It has been asserted that the MUC1 expressed on the apical cell surface of many normal secretory epithelial cells inhibited adhesion and promotes metastatic disease development.[25] Increased MUC1 immunoreactivity has been observed in most breast, lung, stomach, pancreatic, prostate, and ovarian adenocarcinomas. [27] The MUCs are accepted as important markers for early diagnosis and treatment intended to the target because of their abnormal and unique expression pat-

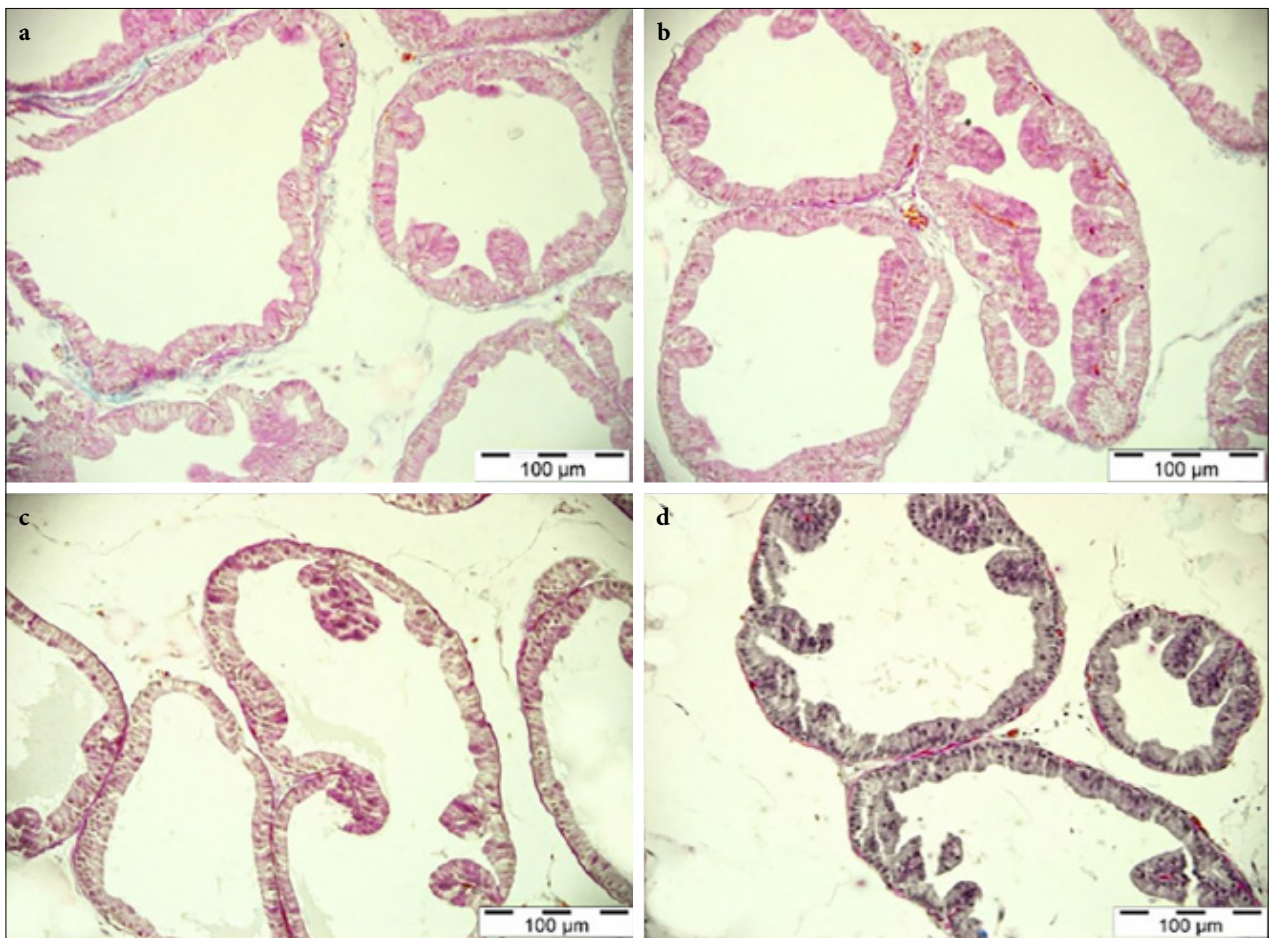


Fig. 1. Rat prostate tissue. (a) Control group, (b) Radiotherapy (RT)-saline group, (c) Amifostine group, (d) RT-amifostine group. Bar: 100 µm, Triple staining.

terns during malignant progression of carcinomas.[10] The MUC1 is one of the best characterized tumor-associated antigens. The MUC1 is important in determining prostate cancer prognosis and has been studied as a therapeutic target.[26] Studies suggest that increased MUC1 expression in prostate tissue will be related to prostate cancer progression.[25,28,29]

In a study in which DNA fragmentation was evaluated,[2] they have formed a total of 3 groups including 12 rats in the study group and 10 in the control group. Radiation was applied to the testicles at a dose of 2 Gy. The rats found in the first group have received only radiation and the rats found in the second group have received 15 min of radiation as 200 mg/kg AMF intraperitoneally, and no treatment has been applied to the rats in the control group. The rats have been sacrificed for the histological evaluation 10 weeks after the radiation. They have stated that apoptosis was low in normal seminiferous tubules in the control group and stated that this was spontane-

ous apoptosis. They have stated that the AMF did not show protection against the radiation-induced germ cell apoptosis in rats.

The study conducted by Kokawa et al.[30] was guiding in the use of 6 Gy ionizing radiations in our study. In the study conducted by Kokawa et al., it has been determined by 2 different methods that the fragmentation rate made peak after 9 Gy irradiations, and they have stated that the fragmentation decreased and necrosis increased in the subjects who received 36.9 Gy irradiations.

In the study conducted by Gezer and Karadasari,[16] a high amount of apoptotic response has been observed in the RT-saline and RT-amifostine groups after 6 Gy, although four weeks passed after the application of RT. It has been seen that there was a statistically significant difference between the apoptotic indices of these two study groups. It has been concluded that the AMF administered intraperitoneally 30 min before the RT showed a protec-

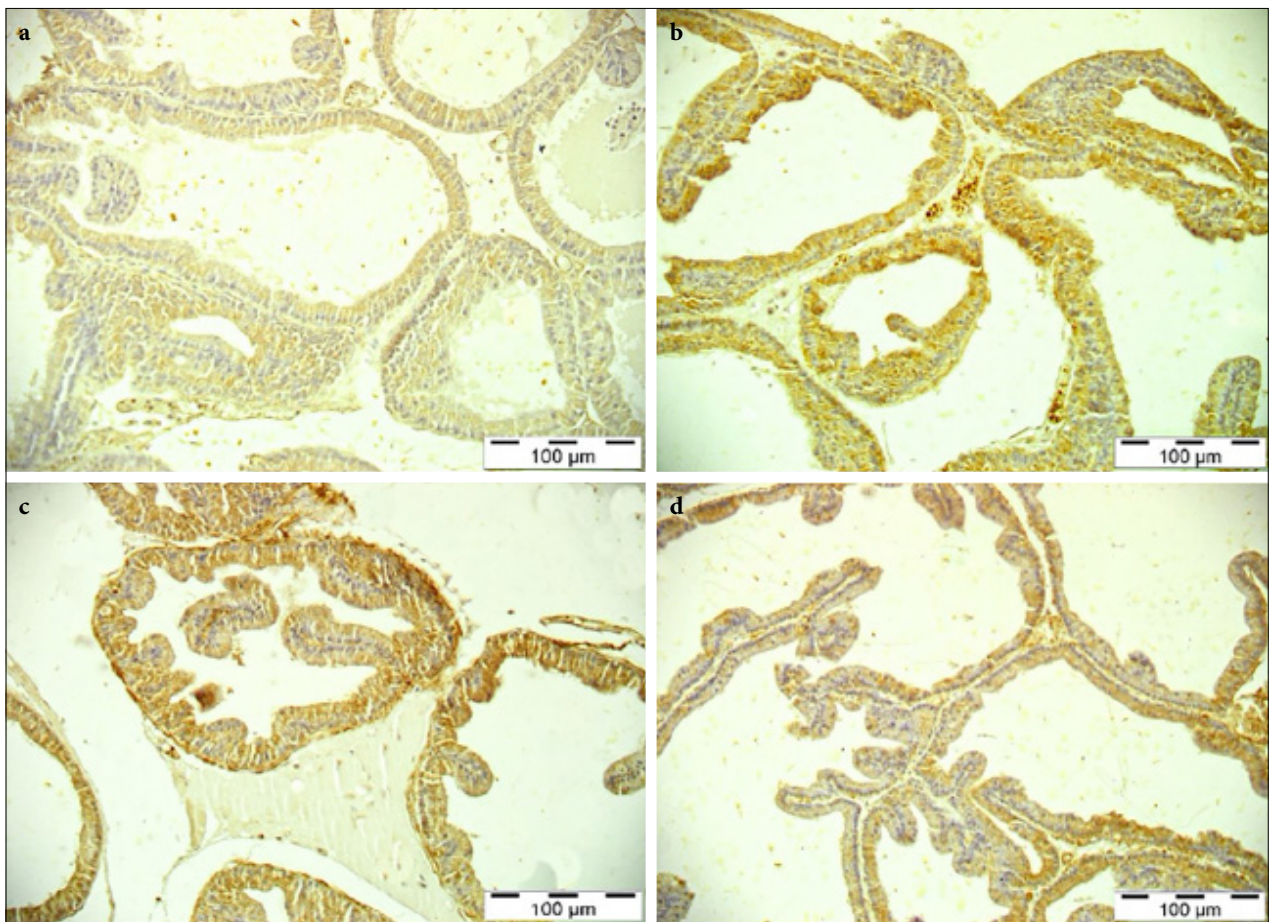


Fig. 2. Rat prostate tissue. Mucin 1 immunoreactivity. (a) Control group, (b) Radiotherapy (RT)-saline group, (c) Amifostine group, (d) RT+ amifostine group. Bar: 100 µm, IHC.
IHC: Immunohistochemistry.

tion against the apoptosis in the germ cells treated with the RT in the rats. Studies have also reported that MUC1 is more expressed in malignant tissues compared to normal tissues.[25,28,29]

CONCLUSION

Our study, the prostate tissues taken from the control, AMF, RT-saline, and RT-AMF groups were also evaluated immunohistochemically. It was seen that the MUC1 immunoreactivity was weak in the parenchyma and stroma cells of the control group, and excess MUC1 release was observed in the AMF, RT-saline, and RT-AMF groups. It has been seen that the MUC1 immunoreactivity was weak in the parenchyma and stroma cells of the control group in general, excess mucin 1 secretion was increased in the AMF and AMF RT and RT groups, and the lack of difference between the AMF, RT-saline and RT-AMF groups indicates that the protective effect

of the AMF varies from tissue to tissue, depending on the dose and the number of fractions applied.

Peer-review: Externally peer-reviewed.

Conflict of Interest: All authors declared no conflict of interest.

Ethics Committee Approval: The study was approved by the Kafkas University Animal Experiments Local Ethics Committee (no: 2018-005, date: 26/01/2017).

Financial Support: This research was supported by the Scientific Research Commission of the Kafkas University (Project No: 2019-TS-60).

Authorship contributions: Concept – S.E.Y., E.K.S., A.G.; Design – S.E.Y., E.K.S., A.G.; Supervision – E.K.S., A.G., S.E.Y.; Funding – E.K.S., A.G., S.E.Y.; Materials – S.E.Y., E.K.S., A.G.; Data collection and/or processing – E.K.S., A.G., S.E.Y.; Data analysis and/or interpretation – E.K.S., A.G., S.E.Y.; Literature search – A.G., S.E.Y.; Writing – A.G., S.E.Y.; Critical review – E.K.S., A.G., S.E.Y.

REFERENCES

1. Erdem SS, Yilmaz M, Yıldırım H, Mayda AS, Filiz Bolu, Durak AA, et al. Information level on cancer and cancer risk factors living in Duzce. *Düzce Üniversitesi Sağlık Bilimleri Enstitüsü Dergisi* 2017;7(1):1–10.
2. Karakoyun-Çelik Ö, Aras A, Tugan D, Hekimgil M, Yalman D, Esassolak M, et al. The relationship between radiation-induced apoptosis in rat germ cells and amifostine. *T Klinik Tıp Bilimleri* 2004;24:142–6.
3. Ringborg U, Bergqvist D, Brorsson B, Cavallin-Ståhl E, Ceberg J, Einhorn N, et al. The Swedish Council on Technology Assessment in Health Care (SBU) systematic overview of radiotherapy for cancer including a prospective survey of radiotherapy practice in Sweden 2001--summary and conclusions. *Acta Oncol* 2003;42(5-6):357–65.
4. Citrin D, Cotrim AP, Hyodo F, Baum BJ, Krishna MC, Mitchell JB. Radioprotectors and mitigators of radiation-induced normal tissue injury. *Oncologist* 2010;15(4):360–71.
5. Rainaldi G, Ferrante A, Indovina PL, Santini MT. Induction of apoptosis or necrosis by ionizing radiation is dose-dependent in MG-63 osteosarcoma multicellular spheroids. *Anticancer Res* 2003;23(3B):2505–18.
6. Barnett GC, Kerns SL, Noble DJ, Dunning AM, West CM, Burnet NG. Incorporating genetic 682 biomarkers into predictive models of normal tissue toxicity. *Clin Oncol (R Coll Radiol)* 2015;683;27(10):579–87.
7. Wang J, Biju MP, Wang MH, Haase VH, Dong Z. Cytoprotective effects of hypoxia against cisplatin-induced tubular cell apoptosis: involvement of mitochondrial inhibition and p53 suppression. *J Am Soc Nephrol* 2006;17(7):1875–85.
8. Kaur P, Bansal MP. Influence of selenium induced oxidative stress on spermatogenesis and lactate dehydrogenase-X in mice testis. *Asian J Androl* 2004;6(3):227–32.
9. Rao M, Narayana K, Benjamin S, Bairy KL. L-ascorbic acid ameliorates postnatal endosulfan induced testicular damage in rats. *Indian J Physiol Pharmacol* 2005;49(3):331–6.
10. Singh AP, Chauhan SC, Bafna S, Johansson SL, Smith LM, Moniaux N, Batra SK. Aberrant expression of transmembrane mucins, MUC1 and MUC4, in human prostate carcinomas. *Prostate* 2006;66(4):421–9.
11. Shyu MK, Lin MC, Liu CH, Fu YR, Shih JC, Lee CN, et al. MUC1 expression is increased during human placental development and suppresses trophoblast-like cell invasion *in vitro*. *Biol Reprod* 2008;79(2):233–9.
12. Genitsch V, Zlobec I, Thalmann GN, Fleischmann A. MUC1 is upregulated in advanced prostate cancer and is an independent prognostic factor. *Prostate Cancer Prostatic Dis* 2016;19(3):242–7.
13. Uğuzalp Kaldır M, Yürüt Çaloğlu V, Coşar Alas R, Çermik TF, Altaner Ş, Eskiocak S, et al. Prevention of radiation-induced liver and kidney toxicity: a role for amifostine. *Türk Onkoloji Dergisi* 2007;22(3):105–17.
14. King M, Joseph S, Albert A, Thomas TV, Nittala MR, Woods WC, et al. Use of amifostine for cytoprotection during radiation therapy: a review. *Oncology* 2020;98(2):61–80.
15. Andrieu MN, Kurtman C, Hicsonmez A, Ozbilgin K, Eser E, Erdemli E. *In vivo* study to evaluate the protective effects of amifostine on radiation-induced damage of testis tissue. *Oncology* 2005;69 (1):44–51.
16. Gezer A, Karadag-Sari E. The role of amifostine in preventing radiotherapy induced testicular tissue damage in rats. *Biotech Histochem*. 2022;97(3):215–21.
17. Akbörü MH, Dincer ST, Gursel OK. Intraoperative radiotherapy. *Ok Meydani Med J* 2013;29:25–34.
18. Seidal T, Balaton AJ, Battifora H. Interpretation and quantification of immunostains. *Am J Surg Pathol* 2001;25(9):1204–7.
19. Sahin B, Karabulut S, Filiz AK, Özkaraca M, Gezer A, Akpulat HA, Ataseven H. Galium aparine L. protects against acetaminophen-induced hepatotoxicity in rats. *Chem Biol Interact* 2022;366:110119.
20. Cox JD, Ang KK. Radiation oncology: Rationale, technique, results. 10th ed. Missouri: Mosby; 2010.
21. Curran WJ. Radiation-induced toxicities: the role of radioprotectants. *Semin Radiat Oncol* 1998;8(4 Suppl1):2–4.
22. Carrell DT, Wilcox AL, Lowy L, Peterson CM, Jones KP, Erickson L, et al. Elevated sperm chromosome aneuploidy and apoptosis in patients with unexplained recurrent pregnancy loss. *Obstet Gynecol* 2003;101(6):1229–35.
23. Gendler SJ. MUC1, the renaissance molecule. *J Mammary Gland Biol Neoplasia* 2001;6(3):339–53.
24. Yamamoto M, Bharti A, Li Y, Kufe D. Interaction of the DF3/MUC1 breast carcinoma-associated antigen and betacatenin in cell adhesion. *J Biol Chem* 1997;272(19):12492–4.
25. Rabiau N, Dechelotte P, Guy L, Satih S, Bosviel R, Fontana L, et al. Immunohistochemical staining of mucin 1 in prostate tissues. *In Vivo* 2009;23(2):203–7.
26. Kapoor A, Gu Y, Lin X, Peng J, Major P, Tang D. MUCIN 1 in Prostate Cancer. Brisbane: Exon Publications; 2021. p. 125–38.
27. Ho SB, Niehans GA, Lyftogt C, Yan PS, Cherwitz DL, Gum ET, et al. Heterogeneity of mucin gene expression in normal and neoplastic tissues. *Cancer Res* 1993;53(3):641–51.
28. Eminaga O, Wei W, Hawley SJ, Auman H, Newcomb LF, Simko J, et al. MUC1 Expression by immunohis-

- tochemistry is associated with adverse pathologic features in prostate cancer: a multi-institutional study. *PLoS One* 2016;11(11):e0165236.
29. Andren O, Guz K, Andersson, Rubin MA, Bismar TA, Karlsson M, et al. MUC-1 gene is associated with prostate cancer death: a 20-year follow-up of a population-based study in Sweden. *Br J Cancer* 2007;97(6):730–4.
30. Kokawa K, Shikone T, Otani T, Nakano R. Transient increases of apoptosis and Bax expression occurring during radiotherapy in patients with invasive cervical carcinoma. *Cancer* 1999;86(1):79–87.