

RESEARCH ARTICLE

Anterior and Posterior Segment Parameters of the Eye in Eagle Owls (*Bubo bubo*)^[1]

Celal Şahin ERMUTLU^{1(*)}  Lokman BALYEN²  İsa ÖZAYDIN¹  Engin KILIÇ¹ 
Özgür AKSOY¹  Hatice Gizem BÜYÜKBAKI³  Burak BÜYÜKBAKI⁴  Uğur AYDIN¹ 
Uğur YILDIZ¹  Dilem Gülece ERMUTLU⁵ 

[1] Presented as an oral presentation at the "1st International Livestock Congress, 20-21 October 2023, Lenkeran, Azerbaijan

¹ Kafkas University, Faculty of Veterinary Medicine, Department of Surgery, TR-36100 TR-36100 Kars - TÜRKİYE

² Harran University, Faculty of Medicine, Department of Eye Diseases, TR-63050 Şanlıurfa - TÜRKİYE

³ Kafkas University, Faculty of Veterinary Medicine, Animal Nutrition and Nutritional Diseases, TR-36100 Kars - TÜRKİYE

⁴ Kafkas University, Faculty of Veterinary Medicine, Department of Wildlife and Ecology, TR-36100 Kars - TÜRKİYE

⁵ Kafkas University, Faculty of Veterinary Medicine, Department of Histology-Embryology, TR-36100 Kars - TÜRKİYE



(*) Corresponding author: Celal Şahin ERMUTLU

Tel: +90 474 242 6836/5219

Fax: +90 474 242 6853

Email: sahinermutlu@hotmail.com

How to cite this article?

Ermutlu CŞ, Balyen L, Özaydın İ, Kılıç E, Aksoy Ö, Büyükbaki HG, Büyükbaki B, Aydın U, Yıldız U, Ermutlu DG: Anterior and posterior segment parameters of the eye in eagle owls (*Bubo bubo*). *Kafkas Univ Vet Fak Derg*, 30 (1): 81-86, 2024.
DOI: 10.9775/kvfd.2023.30500

Article ID: KVFD-2023-30500

Received: 26.08.2023

Accepted: 15.11.2023

Published Online: 09.12.2023

Abstract

Ocular anatomy may differ between species. In study design, it was aimed to create reference values by evaluating the anatomical formations of adult eagle owls with healthy eyes. The study materials consisted of 12 healthy eyes of 6 owl eagle birds brought to our hospital for non-ocular problems. The anterior and posterior eye segments were evaluated with the biomicroscopic examination, Schirmer tear test, color fundus photography, orbital ultrasonography, optical biometry, and keratometry without anesthesia. Anterior chamber deep (ACD), horizontal visible iris diameter (HVID), pupil diameter (PD), and base curve were topographically measured. Axial globe length (AGL), central corneal thickness (CCT), and lens power (LP) were measured. The optic disc, tapetal, non-tapetal region, retina, and choroid were evaluated with fundoscopic examination. Intraocular pressure (IOP) values were also recorded as average values and standard error. ACD 3.21±0.01 mm, HVID 9.02±0.004 mm, PD 7.97±0.10 mm, AGL 31.108±0.1773 mm, CCT 207.83± 0.50 µm, LP 16.5 Dioptri, IOP 13.817±0.2 mmHg, horizontal corneal diameter (HCD) 13.57±0.09 mm, a vertical corneal diameter (VCD) 13.20± 0.14 mm and the mean of basic curve (BC) was found as 10.93±0.10 mm. In conclusion, it is thought that it will be possible to detect more easily pathological conditions of eagle owl birds brought to veterinary clinics with eye or vision problems with reference values presented in this study, and the data obtained from the study will contribute to clinical practice.

Keywords: Eagle owl, Eye anatomy, Ocular examination, *Bubo bubo*

INTRODUCTION

All wild animals, especially the endangered ones, should be protected to preserve and maintain the natural balance. Predatory birds are at the top of the food pyramid. Therefore, their numbers are less than other living beings. These birds have to hunt for survival^[1,2]. The eye is the most important weapon for both hunting and survival. A predator that has lost its sight or with impaired vision can not find food and eventually die. Many predator birds are presented to veterinary clinics due to gunshot

injuries, electrical accidents, and trauma^[3]. The treatment protocols do not differ much from other domestic mammals, especially to treat ophthalmic diseases as long as anatomo-physiological characteristics of individual bird species are well known. Ocular anatomy may differ between species^[2-4]. This variation is required to be known well for a definitive diagnosis and an effective treatment.

Eagle owls (*Bubo bubo*) belong to the owl family of the Raptors family, live in woodlands, steep slopes, cliffs, and mountains, and hunt at night. It is among the endangered species in our as well as some other countries^(5,6).



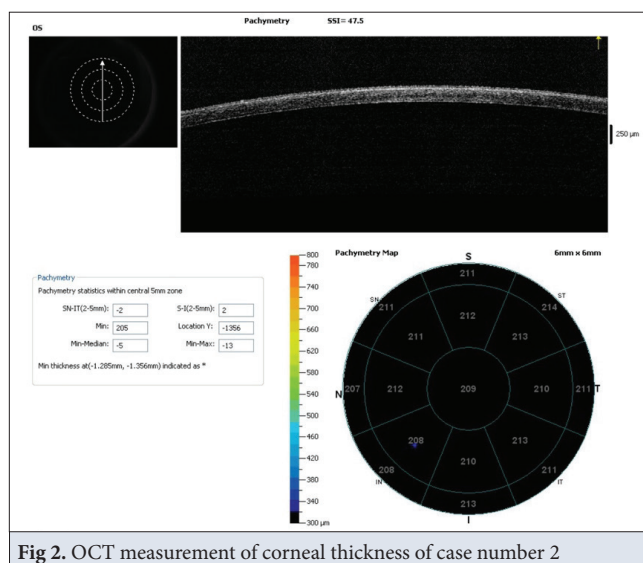


Fig 2. OCT measurement of corneal thickness of case number 2

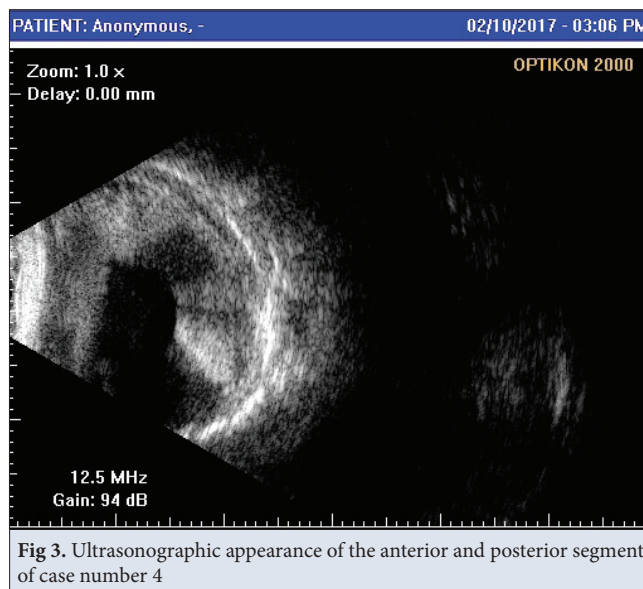


Fig 3. Ultrasonographic appearance of the anterior and posterior segment of case number 4

fluorescein dye in the slit lamp by opening the eyelids, in seconds, keratometric values (K); flattest meridian (K1), and steepest meridian (K2) values in diopter units with manual keratometry, axial lengths in mm with an optical biometric device, lens power in terms of biometrics and diopter units based on manual keratometric values, horizontal and vertical diameters of the corneas were

measured with a goniometer in mm, and the results were recorded (Fig. 1). Sirius 3 dimension rotational Scheimpflug camera topography system (Costruzione Strumenti Oftalmici, Florence, Italy) was used for corneal topography. This technique permits measurement of the cornea in a normal physiologic state (nonanesthetized). Anterior chamber deep (ACD), horizontal visible iris diameter (HVID), pupil diameter (PD), and basic curve (BC) were measured with topography.

The optic disc, tapetal, non-tapetal region, and retina were evaluated with fundoscopic examination and color fundus photographs. The corneal thickness of the eyes was measured with optical coherence tomography (OCT) (RTVue™) (Fig. 2), and intraocular pressure values were measured with an applanation tonometry mounted on a biomicroscope (Topcon CT-800A™). Anterior and posterior segments were evaluated by orbital ultrasonography (Opticon 2000, 15 MHz, 94 dB gain probe) (Fig. 3).

Statistical Analysis

Statistical analyses were performed in the SPSS 18.0 program. First of all, a normality test was performed on the data. Independent Sample T-test was performed for data showing normal distribution, while Mann Whitney U test was used for data not showing normal distribution.

RESULTS

Autorefractometers of all eagle owls were measured as normal. Intraocular pressure values, horizontal corneal diameters, vertical corneal diameters, and central corneal thickness values are given in Table 1. The total means of results were found to be 13.81 mmHg, 13.57 mm, 13.20 mm, and 207.83 μ m respectively. When comparing the values of IOP, HCD, VCD, and CCT There was no statistically significant difference between the right and left eyes ($P>0.05$).

Schirmer II test results, TBUT, lens powers, Keratometric K1 and K2 values, and axial lengths in the right and left eyes are given in Table 2. Total means of results were found 16.25 mm, 22.08 sec, 25.16 dpt, 25.16 dpt, and 31.10 dpt

Table 1. Mean \pm SEM values of IOP, HCD, VCD and CCT					
Case	Number of Cases	IOP (mmHg)	HCD (mm)	VCD (mm)	CCT (μ m)
Right eye	6	14.06 \pm 0.38	13.54 \pm 0.13	13.13 \pm 0.23	208 \pm 0.85
Left eye	6	13.56 \pm 0.15	13.60 \pm 0.13	13.26 \pm 0.18	207.67 \pm 0.61
Total mean	12	13.81 \pm 0.21	13.57 \pm 0.09	13.20 \pm 0.14	207.83 \pm 0.50
P value	-	0.374	0.567	0.744	0.053
SEM: Standard error of mean; IOP: Intraocular pressure; HCD: Horizontal corneal diameter; VCD: Vertical corneal diameter; CCT: Central Corneal Thickness					

Table 2. Mean \pm SEM values of Schirmer II test, TBUT, dioptri, and AL

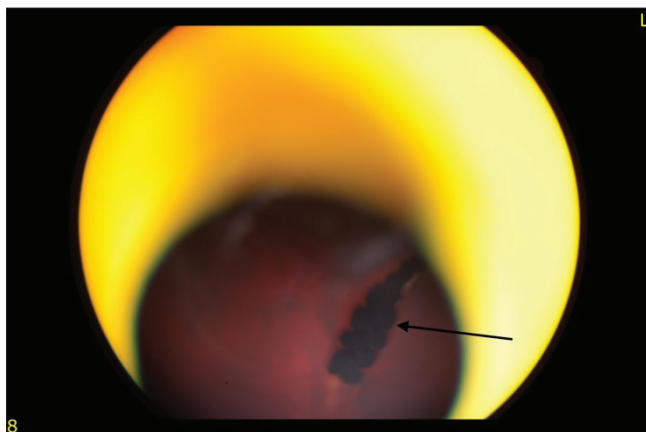
Case	Number of Cases	Schirmer II Test (mm/5 min)	TBUT (Second)	Autorefractometer (Dioptri)	K1 (Dioptri)	K2 (Dioptri)	AL (mm)
Right eye	6	14.67 \pm 0.84	23.67 \pm 2.04	-0.25x170 ⁰	25.00 \pm 0.18	25.08 \pm 0.15	31.20 \pm 0.24
Left eye	6	17.83 \pm 1.01	20.50 \pm 0.88	-0.25x160 ⁰	25.33 \pm 0.10	25.25 \pm 0.17	31.01 \pm 0.27
Total mean	12	16.25 \pm 0.78	22.08 \pm 1.16	-	25.16 \pm 0.11	25.16 \pm 0.11	31.10 \pm 0.17
P value	-	0.334	0.162	-	0.382	0.687	0.020

SEM: Standard error of mean; TBUT: Tear break up time; AL: Axial length

Table 3. Mean \pm SEM values of ACD, HVID, PD and BC

Case	Number of Cases	ACD (mm)	HVID (mm)	PD (mm)	BC (mm)
Right eye	6	3.24 \pm 0.00	9.02 \pm 0.00	8.31 \pm 0.00	10.98 \pm 0.00
Left eye	6	3.18 \pm 0.01	9.03 \pm 0.00	7.63 \pm 0.06	10.88 \pm 0.01
Total mean	12	3.21 \pm 0.01	9.02 \pm 0.00	7.97 \pm 0.10	10.93 \pm 0.10
P value	-	0.141	0.004	0.004	0.748

SEM: Standard error of mean; ACD: Anterior chamber deep; HVID: Horizontal visible iris diameter; PD: Pupil Diameter; BC: Basic curve

**Fig 4.** Retinal Imaging: Due to the pecten (black arrow), a clear image cannot be obtained in the eyes of the eagle owls (case number 1) during fundoscopic examination

respectively. When comparing the values of the Schirmer II test, TBUT, lens powers, Keratometric K1 and K2 values, there were no statistically significant differences between the right and left eyes ($P>0.05$) but statistically significant difference were found in axial lengths values ($P<0.05$).

Anterior chamber depth (ACD), horizontal visible iris diameter (HVID), pupillary diameters, and basic curve values in corneal topography are given in Table 3. The total means of results were found 3.21 mm, 9.02 mm, 7.97 mm, and 10.93 mm, respectively. There was no statistically significant difference between ACD and BC values ($P>0.05$) but HVID and PD values were found to be statistically significantly different ($P<0.05$).

Lens, vitreous, and pecten were evaluated in anterior and

posterior segments in ultrasonography. All structures including retina and choroid were found intact.

In the fundoscopic examination, the retinas of all eagle owls were observed in orange color. Although vascular structures were observed in the deep, very clear images could not be obtained due to the pecten structure (Fig 4).

DISCUSSION

In this study, in which anterior and posterior segments of 12 eyes of 6 eagles brought to our hospital for different reasons were evaluated, to determine the reference values.

For the study, eagle owls that roam free in nature were not used, only those that were brought to our hospital except for eye or vision problems were used, so the number of cases was limited. Although the number of cases is sufficient to determine the statistical average values, it should be assumed that the reference intervals may change with the evaluations to be made on a larger number of eagle owls.

The mean intraocular pressure has been reported as 13-15 mmHg in humans [17], and 12.3 \pm 4 mmHg in cats [18], 10-25 mmHg in dogs, and intraocular pressure values below 20-21 mmHg are also considered normal. In a study by Reuter et al. [19] investigating the intraocular pressure of different species, pressure values was reported as (mmHg \pm SD) white-tailed sea eagle (*Haliaeetus albicilla*), 26.9 \pm 5.8; red kite (*Milvus milvus*), 13.0 \pm 5.5; northern goshawk (*Accipiter gentilis*), 18.3 \pm 3.8; Eurasian sparrowhawk (*Accipiter nisus*), 15.5 \pm 2.5; common

buzzard (*Buteo buteo*), 26.9 ± 7.0 ; common kestrel (*Falco tinnunculus*), 9.8 ± 2.5 ; peregrine falcon, (*Falco peregrinus*), 12.7 ± 5.8 ; tawny owl (*Strix aluco*), 9.4 ± 4.1 ; long-eared owl (*Asio otus*), 7.8 ± 3.2 ; and barn owl (*Tyto alba*), 10.8 ± 3.8 (*Anne reuter*). IOP values obtained from the study are also similar when compared to IOP in humans, cats, Eurasian sparrowhawks, peregrine falcon, and barn owls but it has been reported that IOP values vary according to age, breed, and certain times of the day [17-19].

Eye shape has been defined as the ratio of corneal diameter (CD) to axial length (AL), and vertebrate eyes have adapted to their environment [3]. Therefore, eye shapes differ in terrestrial vertebrates, reptiles, and birds. Because eagle owls are nocturnal hunters, they have a high CD:AL ratio, meaning they have larger CD and shorter AL [3]. In a study [3] in which the eye axial lengths of different owl species (9 species) were measured, it was reported that the axial lengths ranged from 16.8 ± 07 (*Northern saw-whet owl*) mm to 36.5 mm (*Snowy owl*) according to the species. Eye axial lengths of eagle owls, were measured between 30.9 mm and 31.35 mm. In this respect, the eye axial lengths of eagle owls are similar to the Snowy owl species.

It has been reported that the AL of the eye in humans grows rapidly in the postnatal 18 months and reaches adult size in the next 10 years [20]. Therefore, it has been reported that this distance between the cornea and the retina may vary depending on age. Each of the eagle owls included in our study was in the adult period, and the fact that the AL of the eyes were close to each other supported that each of them was an adult. Since the eagle owls used in this study are adults, data on the AL of the eyes of the young and developmental eagles could not be obtained. In humans, it has been reported that the AL is shorter in anisohypermetropic eyes than in normal eyes, and longer in anisohypermetropic eyes [21]. Determining the mean values of eye axial lengths of healthy eagle owls serves as a reference for the diagnosis of anisohypermetropic and anisomyopic eyes. In this study, it is certain that the diagnosis of the diseases of patients with amblyopia, anisometropia, many eye and vision problems, especially amblyopia, anisometropia, can be made by revealing the reference values.

Recently, anterior segment optical coherence tomography (AS-OCT) has emerged as a new non-invasive and non-contact imaging technique for the anterior segment. AS-OCT provides fast and easy quantitative analysis of various structures by generating high-resolution images using long wavelength (1.310 nm) light [19-23]. A limitation of AS-OCT is that it has incomplete penetration through the pigmented epithelium of the iris, thus making it difficult to obtain accurate images of the ciliary body, lens, and zonules behind the pigmented iris. In this study, anterior chamber depth and angle widths were

determined in normal eyes using AS-OCT. Quantitative data were obtained from normal eyes measured by AS-OCT and standardized parameters of anterior chamber configuration were determined. Since OCT is a non-invasive and non-contact method, stress that may occur during examination in eagles is also prevented.

Owl species have a pecten structure in the choroid part of the eye, where blood vessels provide a comb-like appearance. The pecten lies just above the optic nerve head and extends from the retina to the vitreous body. Pecten, also called pecten oculi, has a pigmented structure. In birds, the retinal blood vessels, which supply blood to the eye, have more than undertaken this task. Pecten also helps in the formation of the blood-retina barrier in the eye. There are three different types of pecten in birds. These; according to their morphology, are conical, vaned, and pleated types. The conical type is only reported in the brown kiwi (*Apteryx mantelli*); the vaned type is present in ostriches (*Struthio camelus*) and rheas (*Rhea americana*); and the pleated form is widely reported in most birds (neognathae) such as quail, black kite, and galah.

The size of pecten in birds varies with the bird's visual needs. Day-active bird species have relatively large and highly complex pecten oculi with many folds, while nocturnal-active bird species have relatively small and simple pecten oculi. The most common type seen in birds is the pleated type [16]. Due to its pecten-pigmented structure, it prevents obtaining a clear image in fundoscopic examination. In our study, a clear image could not be obtained in the fundoscopic examination due to the pecten structure.

In this study, 12 healthy eyes of 6 eagle owls were included, which is the minimum number required for statistical analyses. Before starting the study measurements, a direct eye examination was performed for each eye. In addition, the eye was examined by fluorescein staining to determine if there was a lesion in the cornea. Birds with lacrimation, burrs, generalized infection, prolonged non-feeding, and suffering were excluded from the study. No sedation or anesthesia was used to measure the anterior and posterior segment parameters of the eye.

As a result, it was thought that the results obtained from this study, which was planned to determine the anterior and posterior segment parameters of healthy eagle eyes without vision problems, would be a guide in the differentiation of healthy and pathological eyes and would be a reference for future scientific studies.

Availability of Data and Materials

The datasets analyzed during the current study are available from the corresponding author (C. Ş. Ermutlu) upon reasonable request.

Funding Support

There is no funding source.

Conflict of Interest

The authors report no conflicts of interest. The authors alone are responsible for the content and writing of the paper.

Author Contributions

CŞE, LB, and İÖ conceived and supervised the study. EK, ÖA, BB, HGB, UA, UY, and DGE collected and analyzed data. CŞE, LB, and BB, UY performed the examinations. All authors contributed to the critical revision of the manuscript and have read and approved the final version.

REFERENCES

- Martinez JA, Serrano D, Zuberogoitia I: Predictive models of habitat preferences for the Eurasian eagle owl *Bubo bubo*: A multiscale approach. *Ecography*, 26 (1): 21-28, 2003. DOI: 10.1034/j.1600-0587.2003.03368.x
- Aslan I, Adizel Ö, Karasu A, Gençcelep M, Durmuş A, Akgül Y: Treatment of fracture and wound of wild birds in Lake Van valley between 2006 and 2008. *Van Vet J*, 20 (2): 7-12, 2009.
- Lisney TJ, Iwaniuk AN, Bandet MV, Wylie DR: Eye shape and retinal topography in owls (Aves: Strigiformes). *Brain Behav Evol*, 79 (4): 218-236, 2012. DOI: 10.1159/000337760
- Gutiérrez-Ibañez C, Iwaniuk AN, Lisney TJ, Wylie DR: Comparative study of visual pathways in owls (Aves: Strigiformes). *Brain Behav Evol*, 81 (1): 27-39, 2013. DOI: 10.1159/000343810
- Milchev B, Georgiev V, Kovachev A: Breeding failures of the eagle owl *Bubo bubo*: Pros and cons of nesting in natural and human-made structures in SE Bulgaria. *NWJZ*, 15 (1): 75-83, 2019.
- Andreska J, Andreska D: Changes in the Eurasian eagle-owl (*Bubo bubo*) population in Czechia and their association with legal protection. *Raptor J*, 14 (1): 29-44, 2020. DOI:10.2478/srj-2020-0003
- Taha AM, Hamid HH: Comparative anatomical study of the eye in three different birds. *Int J Sci Res Biol Sci*, 7 (1): 62-65, 2020. DOI: 10.3389/fvets.2021.744080
- İşler CT: Ultrasonographic examination of sea turtle eyes (*Caretta caretta* and *Chelonia mydas*). *Kafkas Univ Vet Fak Derg*, 26 (4): 521-524, 2020. DOI: 10.9775/kvfd.2019.23805
- Klećkowska-Nawrot JE, Goździewska-Harłajczuk K, Darska M, Barszcz K, Janeczek M: Microstructure of the eye tunics, eyelids and ocular glands of the Sulawesi bear cuscus (*Ailurops ursinus* Temminck, 1824) (Phalangeridae: Marsupiala) based on anatomical, histological and histochemical studies. *Acta Zool*, 100, 182-210, 2019. DOI: 10.1111/azo.12251
- Demircioğlu İ, Yılmaz, B: Morphometric investigation of bulbus oculi of Awassi Sheep (*Ovis aries*). *Dicle Üniv Vet Fak Derg*, 12 (2): 108-111, 2019.
- Doğan GK, Taşçı SK, Dalga S, Aksu SI: Anatomical and histological studies on the eyes of brown bear (*Ursus arctos horribilis*). *Turk J Vet Anim Sci*, 44 (4): 871-878, 2020. DOI: 10.3906/vet-2002-22
- Dalga S, Aksu SI, Aslan K, Deprem T, Uğran R: Anatomical and histological structures of eye and lacrimal gland in Norduz and Morkaraman sheep. *Turk J Vet Anim Sci*, 46 (2): 336-346, 2022. DOI: 10.55730/1300-0128.4181
- Hussain RS, Al-Tae AA: Comparative study between eye retina of falcon (*Falco columbarius*) and owl (*Bubo bubo*). *Pak J Med Health Sci*, 16 (06): 739-739, 2022. DOI: 10.53350/pjmhs22166739
- Knollinger AM, La Croix NC, Barrett PM, Miller PE: Evaluation of a rebound tonometer for measuring intraocular pressure in dogs and horses. *J Am Vet Med Assoc*, 227 (2): 244-248, 2005. DOI: 10.2460/javma.2005.227.244
- Harmening WM, Vobig MA, Walter P, Wagner H: Ocular aberrations in barn owl eyes. *Vis Res*, 47 (23): 2934-2942, 2007. DOI: 10.1016/j.visres.2007.08.001
- Dayan MO, Ozaydin TA: Comparative morphometrical study of the pecten oculi in different avian species. *Sci World J*, 2013:1-5, 2013. DOI: 10.1155/2013/968652
- Takmaz T, Kosekahya P, Kurkcuoglu PZ: Anterior segment morphometry and intraocular pressure change after uneventful phacoemulsification. *Turk J Med Sci*, 43 (2): 289-293, 2013. DOI: 10.3906/sag-1203-92
- McLellan GJ, Miller PE: Feline glaucoma - A comprehensive review. *Vet Ophthalmol*, 14 (1): 15-29, 2011. DOI: 10.1111/j.1463-5224.2011.00912.x
- Reuter A, Müller K, Arndt G, Eule JC: Reference intervals for intraocular pressure measured by rebound tonometry in ten raptor species and factors affecting the intraocular pressure. *J Avian Med Surg*, 25 (3): 165-172, 2011. DOI: 10.1647/2009-056.1
- Duman ŞB: Ambliyop hastalarda göz aksiyel uzunluğu ve bazı ön kamara parametrelerinin değerlendirilmesi. İnönü Üniversitesi Tıp Fakültesi Uzmanlık Tezi, 2013.
- Patel VS, Simon JW, Schultze RL: Anisometropic amblyopia: Axial length versus corneal curvature in children with severe refractive imbalance. *JAAPOS*, 14 (5): 396-398, 2010. DOI: 10.1016/j.jaapos.2010.07.008
- Jorge J, Rosado JL, Díaz-Rey JA, González-Meijome JM: Central corneal thickness and anterior chamber depth measurement by Sirius Scheimpflug tomography and ultrasound. *Clin Ophthalmol*, 7, 417-422, 2013. DOI: 10.2147/OPTH.S35121
- Kim M, Park KH, Kim TW, Kim DM: Changes in anterior chamber configuration after cataract surgery as measured by anterior segment optical coherence tomography. *Korean J Ophthalmol*, 25 (2): 77-83, 2011. DOI: 10.3341/kjo.2011.25.2.77