

## RESEARCH ARTICLE

# The Effect of Dragon Fruit Extract on Experimental Mesentery Arterial Ischemia-Reperfusion in Rats

Levent SAHİN <sup>1,a (\*)</sup> Erdem TOKTAY <sup>2,b</sup> Muhammed YAYLA <sup>3,c</sup> Pinar AKSU KILICLE <sup>4,d</sup>  
Ahmet HARMANKAYA <sup>5,e</sup> Cem OZIC <sup>6,f</sup> Serdar YIGIT <sup>7,g</sup> Nevra AYDEMİR CELEP <sup>8,h</sup>

<sup>1</sup> Kafkas University, Faculty of Medicine, Emergency Medicine Department, TR-36100 Kars - TURKEY

<sup>2</sup> Kafkas University, Faculty of Medicine, Histology and Embryology Department, TR-36100 Kars - TURKEY

<sup>3</sup> Kafkas University, Faculty of Medicine, Pharmacology Department, TR-36100 Kars - TURKEY

<sup>4</sup> Kafkas University, Faculty of Art and Science, Biology Department, TR-36100 Kars - TURKEY

<sup>5</sup> Kafkas University, Faculty of Art and Science, Chemistry Department, TR-36100 Kars - TURKEY

<sup>6</sup> Kafkas University, Faculty of Medicine, Medical Biology Department, TR-36100 Kars - TURKEY

<sup>7</sup> Kafkas University, Faculty of Medicine, Histology and Embryology Department, TR-36100 Kars - TURKEY

<sup>8</sup> Atatürk University, Faculty of Veterinary Medicine, Histology and Embryology Department, TR-25100 Erzurum - TURKEY

ORCID's: <sup>a</sup> 0000-0003-0193-4393; <sup>b</sup> 0000-0002-7447-6023; <sup>c</sup> 0000-0002-0659-3084; <sup>d</sup> 0000-0002-3567-5775; <sup>e</sup> 0000-0001-9923-6723

<sup>f</sup> 0000-0001-5415-9277; <sup>g</sup> 0000-0001-5631-2335; <sup>h</sup> 0000-0003-1608-5881

Article ID: KVFD-2021-25880 Received: 09.04.2021 Accepted: 02.08.2021 Published Online: 06.08.2021

## Abstract

We hypothesized that dragon fruit extract (DFE) might be a protective agent in oxidative stress damage that develops against ischemia and reperfusion injury in the rat intestine. The rats used in the study were randomly divided into 8 groups, with 6 animals in each group. The HEALTHY group was not induced by ischemia and not given DFE (Group 1). The DFE1000 group was not induced by ischemia; however, DFE was given 1000 mg/kg (Group 2). Ischemia was induced for 1 h in groups 3, 4, 5, 6, 7 and 8. The clamps were then removed to allow reperfusion for 45 min (Groups 6, 7 and 8). DFE was given to rats at doses of 500mg/kg and 1000 mg/kg 30 min before Ischemia (I) and Ischemia/Reperfusion (I/R) administration. At the end of the experiment, histopathological, biochemical and molecular analyses were performed on the intestinal tissues. While glutathione peroxidase, superoxide dismutase, glutathione levels increased significantly in the I+DFE500, I+DFE1000, I/R+DFE500 and I/R+DFE1000 groups compared to the I and I/R groups, there was a significant decrease in tumor necrosis factor- $\alpha$ , Caspase 3 and malondialdehyde (P<0.05). In addition, the loss of tissue integrity, and the increase of inflammatory cells were decreased in the treatment groups. As a result, it was determined that DFE has a strong protective role against oxidative damage in the treatment of intestinal ischemia-reperfusion injury.

**Keywords:** Dragon fruit extract, Intestine, Ischemia/reperfusion, Oxidative stress, Rat

## Ejder Meyvesi Ekstraktının Sıçanlarda Deneysel Mezenter Arteriyel İskemi-Reperfüzyon Üzerine Etkisi

### Öz

Ejder meyvesi ekstraktının (EME), sıçan bağırsağında iskemi ve reperfüzyon hasarına karşı gelişen oksidatif stres hasarında koruyucu bir ajan olabileceğini varsaydık. Çalışmada kullanılan sıçanlar her grupta 6 hayvan olacak şekilde rastgele 8 gruba ayrıldı. SAĞLIKLI grubu, iskemiyle indüklenmedi ve EME verilmedi (Grup 1). EME1000 grubu, iskemiyle indüklenmedi; ancak EME 1000 mg/kg verildi (Grup 2). Grup 3, 4, 5, 6, 7 ve 8'de iskemi 1 saat süreyle indüklendi. Daha sonra 45 dakika reperfüzyona izin vermek için klempler çıkarıldı (Grup 6, 7 ve 8). Sıçanlara İskemi (I) ve İskemi/Reperfüzyon (I/R) uygulamasından 30 dakika önce 500 mg/kg ve 1000 mg/kg dozlarında EME verildi. Deney sonunda bağırsak dokularında histopatolojik, biyokimyasal ve moleküler analizler yapıldı. Glutasyon peroksidaz, süperoksit dismutaz, glutasyon seviyeleri I + EME500, I + EME1000, I/R + EME500 ve I/R + EME1000 gruplarında I ve I/R gruplarına göre önemli ölçüde artarken, tümör nekroz faktörü- $\alpha$ , Kaspaz 3 ve malondialdehit seviyelerinde anlamlı azalma oldu (P<0.05). Ayrıca tedavi gruplarında doku bütünlüğü kaybı ve inflamatuvar hücre yoğunluğu azaldı. Sonuç olarak, bağırsak iskemi-reperfüzyon hasarının tedavisinde DFE'nin oksidatif hasara karşı güçlü bir koruyucu rolü olduğu belirlendi.

**Anahtar sözcükler:** Ejder meyvesi ekstraktı, Bağırsak, İskemi/reperfüzyon, Oksidatif stres, Sıçan

### How to cite this article?

**Sahin L, Toktay E, Yayla M, Kilicle P, Harmankaya A, Ozic C, Yigit S, Aydemir Celep N:** The effect of dragon fruit extract on experimental mesentery arterial ischemia-reperfusion in rats. *Kafkas Univ Vet Fak Derg*, 27 (5): 575-581, 2021.  
DOI: 10.9775/kvfd.2021.25880

### (\*) Corresponding Author

**Tel:** +90 474 225 1150 Cellular phone: +90 553 183 8665

**E-mail:** levsahin44@gmail.com, leventsahin@kafkas.edu.tr (L. Sahin)



This article is licensed under a Creative Commons Attribution-NonCommercial 4.0 International License (CC BY-NC 4.0)

## INTRODUCTION

Ischemia (I) is the reduced or interrupted blood flow to a tissue and reperfusion is the state of restoring blood flow and oxygen to ischemic tissue [1]. Damage caused by ischemia can be exacerbated by reperfusion [2] and the gastrointestinal tract tissues are highly susceptible to Ischemia/Reperfusion (I/R) damage in the body [3]; intestines are the mostly affected organs [4]. I/R may also cause damage following abdominal aortic aneurysm, small bowel transplant, strangulated hernia, hypovolemic and septic shock [5]. Acute mesenteric ischemia (AMI) occurs with the sudden interruption of the blood supply of the small intestines and as a result, cellular damage and necrosis have been observed. Diarrhea, malabsorption, short bowel syndrome, and death may occur as a result of intestinal I/R damage [6]. The severity of ischemia in the intestine depends on the duration of the ischemia, the level of mesenteric artery occlusion, and the rate of collateral flow [5].

Intestinal ischemia damage can lead to the rapid progression of tissue necrosis, accelerating the production of reactive oxygen, as well as the rapid translocation of intestinal bacteria to the mucosa. In addition, the release of cytokines, such as inflammation precursor interleukin 1 $\beta$  and tumor necrosis factor- $\alpha$ , may lead to cell damage, severe metabolic disorders, and multi-organ failure due to inflammation [1]. AMI, is a serious life-threatening surgical problem [7]. The mortality rate in patients that are misdiagnosed, or late diagnosis is 60 to 80% [5] and irreversible damage occurs after the first 6 h. Although blood flow can be restored with urgent surgical intervention, it should be managed in light of the high oxidative damage that occurs. From this point of view, foods containing high antioxidants can attenuate oxidative damage by collecting superoxide radicals emitted. Natural products such as astragalus membranaceus, ostiole, green tea, and *Nigella sativa* with high antioxidant content, have been shown to cause antioxidative effects on the intestinal mucosa [8-10].

The red dragon fruit (*Hylocereus polyrhizus*) has anti-inflammatory, antiradical and high antioxidant capacities. In recent studies, red dragon fruit extract is preferred due to its antimicrobial, antioxidant, anticancer, hypocholesterolemic, and prebiotic effects [11-13]. The fruit has also scavenging property against alkyl and hydroxyl radicals. Because of this feature, it contributes to the balancing of oxidative stress [14]. Moreover, this fruit is rich in organic acids, protein and other minerals such as potassium, magnesium, calcium, and vitamins [15,16].

The experimental intestinal I/R model is one of the important models used to reduce oxidative stress caused by reactive oxygen species, especially during reperfusion in the small intestine.

Our study suggests that dragon fruit extract (DFE) may have a protective role in the treatment of acute mesenteric artery ischemia and reperfusion. Our aim in this study was to investigate if the dragon fruit can be used in the treatment of damage resulting from small intestine mesenteric artery ischemia. Accordingly, we analyzed the capacity of the extract to eliminate reactive oxygen species (ROS) in the experimental mesenteric artery I/ R model.

## MATERIALS AND METHODS

### Ethics Statement

The Local Ethics Committee of Animal Experiments of Kafkas University approved this study (Approval No: KAÜ-HADYK: 2020/046).

### Extraction

Dragon fruits were obtained from the Mersin/Erdemli, Dragon Fruit Greenhouse. The peel of the fruit was removed and the parts eaten as fruit were sliced. They were dried sparsely on blotter paper in an environment free from direct sunlight and provided with dry airflow. The dried fruit slices were ground in a grinder. The ground fruits were weighed with 0.1 mg sensitivity and approximately 50 g were taken into the cartridge washed with extraction solvent. The cartridge was placed in 500 mL Soxhlet extractor and 650 mL of solvent was added to the boiling flask. The solvent was extracted (9-12 siphons) until it was clear. 96% ethanol was used as the extraction solvent and after the obtained extract was filtered through the blue band filter paper and its particles were removed, the solvents were evaporated at 40-50°C with a rotary evaporator in the balloons brought to constant weight.

### Animals

Forty-eight Sprague-Dawley female rats with an average weight of 200-250 g and 10-12 weeks old were obtained from the Kafkas University Experimental Research and Application Center. The rats were given enough (*ad libitum*) water and pellet feed during the experiment. The animals were housed at optimal room temperature and humidity levels.

Rats were randomly divided into 8 groups with 6 animals in each group (Table 1).

### Study Design

The animals were anesthetized through the intraperitoneal (i.p.) administration of a combination of 15 mg/kg xylazine HCl (Rompun®-Bayer-Turkey) and 100 mg/kg ketamine (Ketalar®-Pfizer-Turkey). A 4 cm incision was made in the ventral midline approach at the level of the umbilicus of the rats. Then the jejunum part of the small intestine was taken out. The bloodstream from the superior mesenteric artery was stopped for 45 min, with the help of vascular

**Table 1.** Experimental model and groups

Groups	Animal Numbers	Groups Abbreviation	Group Descriptions
Group 1	n:6	HEALTHY	Only laparotomy was performed in the Healthy group
Group 2	n:6	DFE1000	Only laparotomy was performed and DFE 1000 mg/kg was given
Group 3	n:6	I	45 min of ischemia period was applied with laparotomy
Group 4	n:6	I+DFE500	Rats were given DFE 500 mg/kg orally by gavage 30 min before ischemia, followed by a 45 min ischemia period
Group 5	n:6	I+DFE1000	The rats were given DFE 1000 mg/kg orally by gavage 30 min before ischemia, followed by a 45 min ischemia period
Group 6	n:6	I/R	45 min of ischemia followed by a 1 h reperfusion period were applied to the rats by laparotomy
Group 7	n:6	I/R+DFE500	After 45 min of ischemia, 1 h reperfusion period was applied. DFE 500 mg/kg was given orally by gavage to rats before 30 min of reperfusion
Group 8	n:6	I/R+DFE1000	After 45 min of ischemia, 1 h reperfusion period was applied. DFE 1000 mg/kg was given orally by gavage to rats before 30 min of reperfusion

clamps. After initiation of ischemia, the intestines were reinserted into the abdomen and the incision area was closed with sutures. The ischemia-only group (Group 3) was euthanized after 45 min of ischemia. In the ischemia and reperfusion groups, the abdominal incision was reopened and the clamps were removed at the end of 45 min of ischemia. They were exposed to reperfusion injury by providing bloodstream again. These groups (Group 6, 7, and 8) were euthanized 1 h after the start of reperfusion (The intestines were then reinserted into the abdomen and sutured closed) [17,18].

At the end of the study, animals were euthanized by high dose thiopental sodium (i.p.) under anesthesia in compliance with ethical principles. The jejunum segment of the intestine was observed and the intestinal organs were grasped with pens. Collected tissues were stored at 3.7% formaldehyde for histopathological and at -80°C for biochemical examination.

### Extract Application Procedure

While DFE was given orally by gavage 30 minutes before ischemia to I+DFE500 (Group 4) and I+DFE1000 (Group 5) groups; I/R+DFE500 (Group 7) and I/R+DFE1000 (Group 8) groups were given 30 min before reperfusion. Experimental groups and applied procedures are given in [Table 1](#).

### Histologic Analyses

Intestine tissues were rapidly fixed in 3.7% solution formaldehyde for 48 h. After fixation, all samples for histological tissue processing were routinely performed. According to histological tissue processing, all tissues were passed through increasing alcohol (50, 60, 70, 80, 96, 99-1 h) series. Subsequently, 3 series of xylene were kept in solution (3x15 min). Finally, it was kept in molten soft and hard liquid paraffin. At the end of the follow-up procedure, tissues were individually blocked in paraffin. After tissue processing, 5 µm thick sections were taken from each

paraffin block for histopathological examination. Intestine tissue slides were stained with Mallory's trichrome stain.

### Biochemical Analyses

For the determination of oxidant/antioxidant parameters [Malondialdehyde (MDA), Glutathione (GSH)], 100 mg of tissue was weighed for each animal. All tissues were homogenized in a homogenizer device. For biochemical studies, while MDA levels in supernatants were measured colorimetrically according to the methods reported by Yoshioko et al.<sup>[19]</sup> at 535 nm, GSH levels are measured colorimetrically as regards Beutler et al.<sup>[20]</sup> at 412 nm by invitrogen elisa reader.

### Molecular Analysis

#### - RNA isolation and cDNA synthesis

In the study, Ribonucleic acid (RNA) isolation was first made from tissues. This isolation was performed with TRIzol (Sigma).

#### - Total RNA isolation with TRI solution (Tri Reagent)

Tissues were dissected using the freeze-thawing method and centrifuged at 7000 rpm for 15 min, then turned into tissue pellets. The supernatant was removed, 750 µL TRI was added onto the pellet, and homogenate was obtained. The homogenate was left at room temperature for 10 min and 200 µL chloroform was later added to the homogenate for each 1 mL of TRI. The samples were tightly capped and shaken vigorously for 20 sec, then the shaken mixture was left at room temperature for 10 min. It was centrifuged at 12,000 g for 15 min at 4°C. The supernatant was then carefully removed and transferred to a new tube. 0.5 mL of isopropanol was added to the upper phase separated for each mL of TRI used in the 4<sup>th</sup> step. The samples obtained were kept at room temperature for 15 min and samples were then centrifuged at 4°C, 8 min, and 12,000 g. The supernatant was removed, and the RNA pellet was



washed by adding at least 1 mL of 75% ethanol per ml of TRI used in step 4<sup>th</sup> and vortexing. The washed sample was centrifuged at 4°C for 5 min at 7500 g. Ethanol was removed and the pellet was dried in a fume hood for 15-20 min. RNA was resolved with 80 µL ddH<sub>2</sub>O (Sterile ultra-pure water) and the RNAs thus obtained were measured using the spectrophotometric method.

#### - cDNA Synthesis

cDNA was obtained using the Fermentas Revert Aid First Strand cDNA Synthesis Kit (#1622), each sample containing 5 µg of RNA. All steps are done according to the kit procedure. First, the RNA sample obtained from RNA isolation was taken into ice in 0.5 mm PCR tubes so that it would react with 5 g, and 1 µL of oligo dT18 was added and the final volume was completed to 12 µL with sterile distilled water. The reaction tube was kept at 70°C for 5 min and then left on the ice. To the reaction tube in ice, respectively were added 4 µL 5x Reaction buffer, 1 µL Ribolock Ribonuclease inhibitor, and 2 µL 10 mM dNTP mix, then incubated at 37°C for 5 min. At the end of the incubation, 1 µL of M-MuLV reverse transcriptase enzyme was added. The tube containing the prepared mixture was first kept at 42°C for 60 min. At the end of the incubation, the reaction tube was incubated at 70°C for 10 min to inhibit the enzyme. At the end of this time, the reaction tube was placed on ice and subsequently kept at 20°C for use in studies.

#### - Expression Analysis by Reverse Transcription Polymerase Chain Reaction

Rat primer sequences of RT-PCR are detailed in Table 2. It was aimed to determine the expression levels of Glutathione Peroxidase (GPX), Superoxide Dismutase (SOD), Tumor Necrosis Factor- alpha (TNF-α) and Caspase-3 (Cas-3).

#### - Generation of cDNA Copy

PCR reaction 2.5 µL 10X buffer, 2.5 µL 25 mM MgCl<sub>2</sub>, 2 µL

2.5 µM dNTP mix, 2.5 µL F, 2.5 µL R, 0.5 µL cDNA template (1:10 dilution), 0.2 µL Taq DNA Polymerase enzyme (5 U/µL) 12.3 µL ddH<sub>2</sub>O was added, so that the final volume was 25 µL. The PCR program used: 5 min at 94°C, 50 sec at 94°C, 1 min at 50-60°C, 50 sec at 72°C, 5 min at 72°C. The material was stored in the device at 4°C until it was taken.

#### Statistical and Semi-quantitative Analysis

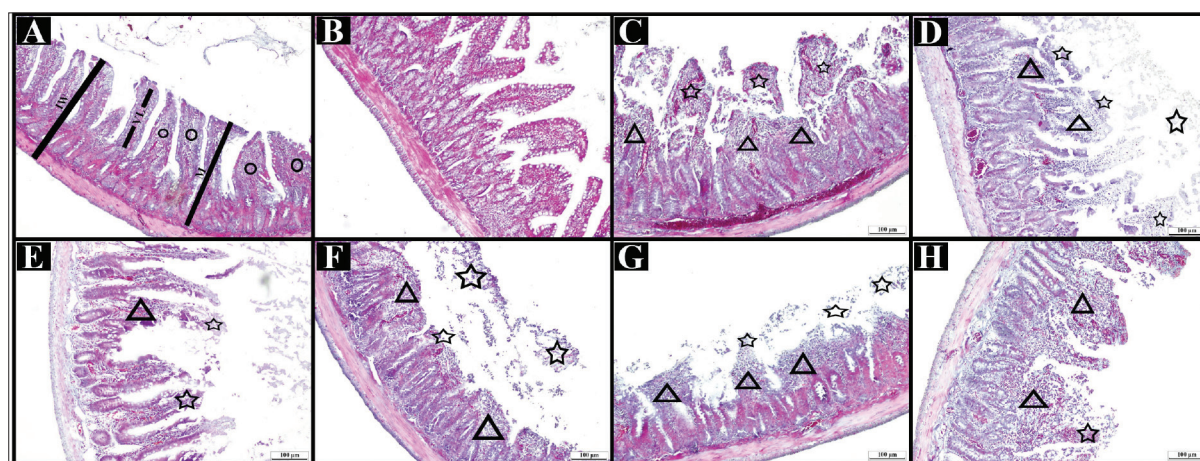
The data of our study were statistically evaluated with the IBM 20.00 SPSS software program. The groups were compared to Tukey's post-hoc tests from the one- way ANOVA multiple comparison test with a value of P<0.05 considered statistically significant.

## RESULTS

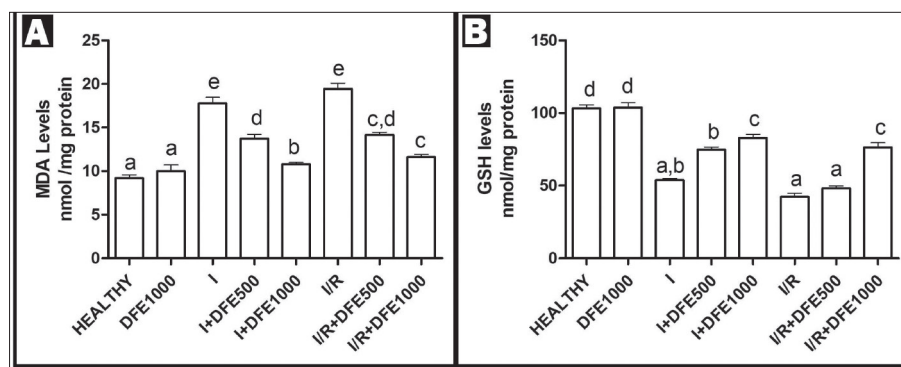
#### Histopathological Findings

In the Healthy group (Fig. 1-A) and the DFE1000 group (Fig. 1-B), healthy-looking villus structures were observed in the small intestine mucosa. No pathological condition was found in the epithelium and lamina propria. In the I group, loss of tissue integrity of the villi structures in the small intestine mucosa and inflammatory cells and edema in the lamina propria were observed. However, areas of hemorrhage were seen in the submucosa and locally in the mucosa (Fig. 1-C). In the I +DFE500 (Fig.

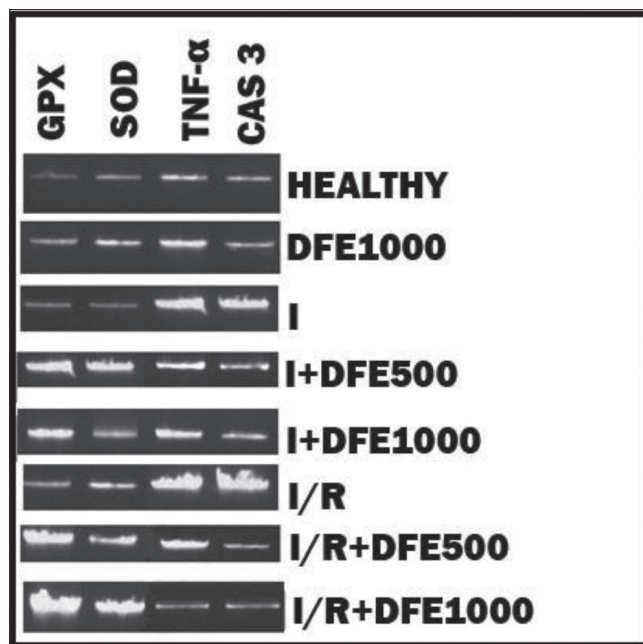
Table 2. Rat Primer sequences of RT-PCR		
Gene	Primer	Annealing
GPX	F: CAGTTCGGACATCAGGAGAAT	60
	R: AGAGCGGGTGAGCCTTCT	
SOD	F: ATGTGTCCATTGAAGATCGTGTGA	60
	R: GCTCCAGCATTCCAGTCTTTGTA	
TNF-α	F: ACTGAACCTCGGGGTGATTG	60
	R: GCTTGGTGGTTTGCTACGAC	
Cas-3	F: CATTTCTTTAGTGATAAAA	60
	R: ATCATGGGATCTGTTTCTTT	



**Fig 1.** Triple staining findings in intestinal tissue. IW: Intestinal wall, VL: Villus, M: Mucosa, Round: Lamina propria, Triangle: Inflammatory area, Star: Loss integrity of tissue. Magnification: x20



**Fig 2.** Comparison of biochemical MDA and GSH between groups (I: Ischemia, I/R: Ischemia and reperfusion, DFE: Dragon Fruit Extract)



**Fig 3.** Comparison of molecular GPX, SOD, TNF-α and Caspase-3 between groups (I: Ischemia, I/R: Ischemia and reperfusion, DFE: Dragon fruit extract)

1-D) and in the I +DFE1000 (Fig. 1-E) groups, we observed that loss of tissue integrity of the villi structures in the small intestine mucosa occurred mostly in the superficial region. However, inflammatory cells and edema were observed in the superficial mucosa. In these groups, areas of hemorrhage were decreased compared to the ischemia group.

As seen in the I group, the villi with loss of tissue integrity in the I/R group were completely detached from their basal parts and a naked mucosa image was observed. Inflammatory cells and edema were seen (Fig. 1-F). In the I/R+DFE500 group, the villi were relatively protected compared to I/R group, but a naked mucosa image was also present in this group. Similarly, inflammatory cells and edema were seen (Fig. 1-G). In the I/R+DFE1000 group, compared to the I/R group, the villi were clearly preserved for epithelial losses, but a bare mucosa image was also present. Inflammatory cells and edema were decreased compared to the I/R and the I groups (Fig. 1-H).

### Biochemical Findings

MDA levels in the I and I/R groups were higher than those in the healthy group. These levels were significantly reduced in a dose-dependent manner in the ischemia and I/R+DFE treatment groups (Fig. 2-A) ( $P < 0.05$ ). We determined that the GSH level reduced after ischemia. However, it increased in the treatment groups. GSH levels were especially low in the I/R groups and increased in a dose-dependent manner in the DFE treatment groups (Fig. 2-B) ( $P < 0.05$ ).

### Molecular Findings

In the healthy and DFE1000 groups, the expression levels of GPX, SOD, TNF-α, and Cas-3 were determined to be at the same level as Glyceraldehyde 3-phosphate dehydrogenase used as the control gene. In the ischemia and I/R groups, GPX, SOD expression levels decreased, while TNF-α and Cas-3 levels increased compared to the healthy group. While the levels of GPX, SOD increased in the I and I/R treatment groups compared to the I and I/R groups, TNF-α and Cas-3 expression levels decreased (Fig. 3) ( $P < 0.05$ ).

## DISCUSSION

Acute mesenteric ischemia (AMI) are cases that require emergency intervention. AMI injuries are serious and often result in death in late diagnosis. A reperfusion injury that develops following intestinal ischemia causes systemic multi-organ damage, although blood is re-flowed to the intestines with urgent interventions [21]. Therefore, the aim should be the prevention of reperfusion injuries as well as ending ischemia, in the treatment of AMI.

Tissue oxygenation decreases in intestinal ischemia, leading to the initiation of a series of pathological events. During these events, Adenosine Triphosphate (ATP) production stops and cellular respiration begins to be provided by anaerobic respiration. However, by-products of anaerobic respiration accumulate in the cell and cause increased intracellular acidosis. The resulting low pH initiates ischemic damage by causing protein denaturation, loss of enzyme function, glial edema and increased free radicals in the cell [22]. With the re-flow of blood to the tissue, toxic metabolites that occur during ischemia create more aggressive super-

oxide radicals, thus leading to aggravation of tissue damage [23]. On the other hand, intracellular antioxidant systems such as SOD, and GSH are insufficient during ischemia and reperfusion. The cell remains vulnerable to oxidative damage, resulting in increased capillary permeability. Thus, intestinal edema, fluid accumulation in the intestinal lumen, mucosal barrier disruption and bacterial translocation occur [24].

The important indicator of oxidative stress in the tissue is MDA, which is the end product of lipid peroxidation [25]. Oxidative damage has been associated with the measurement of this product in many ischemia and reperfusion studies. In our study, elevated MDA levels in the I and I/R groups support these results. In addition, the low levels of GSH, an intracellular antioxidant, in the I and I/R groups also support our findings. This relationship also appears at the gene level in our molecular analysis findings of GPX and SOD. Another consequence of increased intracellular oxidative damage is the initiation of the intracellular apoptotic caspase cascade. The increased caspase activation can inform us about the severity of oxidative damage. For this purpose, the expression levels of Cas-3 that have an important function in the caspase cascade, prove to us the severity of the oxidative damage in the I and I/R groups at the gene level. We observed the loss of tissue integrity in villus structures in these groups in our histopathological analysis. These results support our findings of high MDA, Cas-3, and low GSH, SOD.

A disrupted mucosal barrier during intestinal ischemia and reperfusion leads to the onset of systemic inflammation and TNF- $\alpha$  is an important signal protein this onset. TNF- $\alpha$  triggers inflammation and increases the release of other inflammation-related cytokines, which lead to excessive migration of neutrophils into ischemic tissue. Neutrophil infiltration leading to increased tissue damage accelerates the destruction of damaged cells in the tissue. Indeed, high levels of TNF- $\alpha$  in the I and I/R groups in molecular analysis findings support this relationship. In addition, increased inflammation and edema findings in our histopathological findings in the I and I/R groups reveal the presence of inflammation. This explains the increase in TNF- $\alpha$  levels.

When looking at the studies on this subject in the literature, high MDA, Cas-3, and TNF- $\alpha$  in the intestinal ischemia/reperfusion study conducted by Kamel et al. were found to be similar to our findings [26]. In another study, low GSH, SOD and GPX findings in ischemia and reperfusion groups also support our study [27].

Red dragon fruit has medicinal therapeutic potential due to its flavonoid, thiamine, niacin, pyridoxine, cobalamin, betalain, phytoalbumin, carotene, polyphenol, and phenolic content [28]. In another study, they investigated the content of Red dragon fruit, showed that it contains a significant amount of antioxidants, and suggested that this fruit may scavenge against free radicals [10]. In our study, we observed

significant decreases in MDA levels depending on the dose in the I and I/R treatment groups and significant increases in GSH and GPX levels. In addition to this, we observed significant decrease in Cas-3 levels in the I and I/R treatment groups; these results were also reflected in our histopathological images. Especially, loss of tissue integrity improved significantly in the treatment groups. Another important detail is a decrease of inflammatory cells in the tissue. This result is consistent with the significant decrease in TNF- $\alpha$  gene expression. It has been reported DFE increases MDA levels and GPX levels against oxidative damage [29]. These results support our findings in our study.

Acute mesenteric ischemia followed by reperfusion injury causes severe oxidative stress in the tissue. Reperfusion application alone is insufficient to eliminate oxidative damage but dragon fruit extract can be used as a supportive and protective measure in minimizing this damage to tissue. These results suggest that the content of the dragon fruit needs to be studied in greater detail and that perhaps DFE will be accepted as a preservative supplement food in the near future.

## ACKNOWLEDGEMENTS

Thanks to Oguzhan Kilic for sending fresh fruits we used in the study.

## FINANCIAL SUPPORT

This research did not receive any specific grant from funding agencies in the public, commercial, or not-for-profit sectors.

## CONFLICT OF INTEREST

We declare that there is no conflict of interest between the authors in this article.

## AUTHOR CONTRIBUTIONS

LS contributed to literature searches, study design. ET contributed to critical revision. MY, NAC and SY contributed to methodology. PAK, AH and CO contributed to data acquisition.

## REFERENCES

1. Soares ROS, Losada DM, Jordani MC, Évora P, Castro-e-Silva O: Ischemia/reperfusion injury revisited: An overview of the latest pharmacological strategies. *Int J Mol Sci*, 20 (20): 5034, 2019. DOI: 10.3390/ijms20205034
2. Zhang Z, Pan C, Wang HZ, Li YX: Protective effects of osthole on intestinal ischemia-reperfusion injury in mice. *Exp Clin Transplant*, 12 (3): 246-252, 2014. DOI: 10.6002/ect.2013.0207
3. Tassopoulos A, Chalkias A, Papalois A, Iacovidou N, Xanthos T: The effect of antioxidant supplementation on bacterial translocation after intestinal ischemia and reperfusion. *Redox Rep*, 22 (1): 1-9, 2017. DOI: 10.1080/13510002.2016.1229893



4. Xing D, Zhang R, Li S, Huang P, Luo C, Hei Z, Xia Z, Gan X: Pivotal role of mast cell carboxypeptidase A in mediating protection against small intestinal ischemia-reperfusion injury in rats after ischemic preconditioning. *J Surg Res*, 192 (1): 177-186, 2014. DOI: 10.1016/j.jss.2014.05.050
5. Oldenburg WA, Lau LL, Rodenberg TJ, Edmonds HJ, Burger CD: Acute mesenteric ischemia: A clinical review. *Arch Intern Med*, 164 (10): 1054-1062, 2004. DOI: 10.1001/archinte.164.10.1054
6. Wang Z, Ji Y, Wang S, Wang R, Li Z, Kang A, Xu H, Shi M, Zhao M: Protective effect of intestinal ischemic preconditioning on ischemia reperfusion-caused lung injury in rats. *Inflammation*, 38 (1): 424-432, 2015. DOI: 10.1007/s10753-014-0047-3
7. Aydin F, Aslan B: Early markers of mesenteric artery ischemia in rats. *Kafkas Univ Vet Fak Derg*, 26 (6): 787-793, 2020. DOI: 10.9775/kvfd.2020.24393
8. Chen R, Shao H, Lin S, Zhang JJ, Xu KQ: Treatment with *Astragalus membranaceus* produces antioxidative effects and attenuates intestinal mucosa injury induced by intestinal ischemia-reperfusion in rats. *Am J Chin Med*, 39 (5): 879-887, 2011. DOI: 10.1142/S0192415X11009275
9. Abdeen SM, Mathew TC, Dashti HM, Asfar S: Protective effects of green tea on intestinal ischemia-reperfusion injury. *Nutrition*, 27 (5): 598-603, 2011. DOI: 10.1016/j.nut.2010.05.014
10. Terzi A, Coban S, Yildiz Fahrettin Y, Ates M, Bitiren M, Taskin A, Aksoy N: Protective effects of *Nigella sativa* on intestinal ischemia-reperfusion injury in rats. *J Invest Surg*, 23 (1): 21-27, 2010. DOI: 10.3109/08941930903469375
11. Rebecca OPS, Boyce AN, Chandran S: Pigment identification and antioxidant properties of red dragon fruit (*Hylocereus polyrhizus*). *Afr J Biotechnol*, 9 (10): 1450-1454, 2010. DOI: 10.5897/AJB09.1603
12. Castro-Enriquez DD, Montaña-Leyva B, Del Toro-Sánchez CL, Juárez-Onofre JE, Carvajal-Millán E, López-Ahumada GA, Barreras-Urbina CG, Tapia-Hernández JA, Rodríguez-Félix F: Effect of ultra-filtration of pitaya extract (*Stenocereus thurberi*) on its phytochemical content, antioxidant capacity, and UPLC-DAD-MS profile. *Molecules*, 25 (2): 281, 2020. DOI: 10.3390/molecules25020281
13. Hartono MR, Suardita K, Yuliati A: Proliferation and osteogenic differentiation of bone marrow-derived mesenchymal stem cell after exposure to red flesh dragon fruit extract. *Dent Res J (Isfahan)*, 17 (2): 107, 2020. DOI: 10.4103/1735-3327.280885
14. Kim, H, Choi HK, Moon JY, Kim YS, Mosaddik A, Cho SK: Comparative antioxidant and antiproliferative activities of red and white pitayas and their correlation with flavonoid and polyphenol content. *J Food Sci*, 76 (1): C38-C45, 2011. DOI: 10.1111/j.1750-3841.2010.01908.x
15. Le Bellec F, Vaillant F, Imbert E: Pitahaya (*Hylocereus* spp.): A new fruit crop, a market with a future. *Fruits*, 61 (4): 237-250, 2006. DOI: 10.1051/FRUITS:2006021
16. Stintzing FC, Schieber A, Carle R: Betacyanins in fruits from redpurple pitaya, *Hylocereus polyrhizus* (Weber) Britton and Rose. *Food Chem*, 77 (1): 101-106, 2002. DOI: 10.1016/S0308-8146(01)00374-0
17. Akyildiz HY, Karabacak A, Akyüz M, Sözüer E, Akcan A: Effects of piperine in experimental intestinal ischemia reperfusion model in rats. *Ulus Travma Acil Cerrahi Derg*, 19 (5): 387-391, 2013. DOI: 10.5505/tjtes.2013.48457
18. Hei ZQ, Gan XL, Luo GJ, Li SR, Cai J: Pretreatment of cromolyn sodium prior to reperfusion attenuates early reperfusion injury after the small intestine ischemia in rats. *World J Gastroenterol*, 13 (38): 5139-5146, 2007. DOI: 10.3748/wjg.v13.i38.5139
19. Yoshioka T, Kawada K, Shimada T, Mori M: Lipid peroxidation in maternal and cord blood and protective mechanism against activated-oxygen toxicity in the blood. *Am J Obstet Gynecol*, 135 (3): 972-979, 1979. DOI: 10.1016/0002-9378(79)90708-7
20. Beutler E, Duron O, Kelly BM: Improved method for the determination of blood glutathione. *J Lab Clin Med*, 61, 882-888, 1963.
21. Luther B, Mamopoulos A, Lehmann C, Klar E: The ongoing challenge of acute mesenteric ischemia. *Visc Med*, 34 (3): 215-221, 2018. DOI: 10.1159/000490318
22. Siemionow M, Arslan E: Ischemia/reperfusion injury: A review in relation to free tissue transfers. *Microsurgery*, 24 (6): 468-475, 2004. DOI: 10.1002/micr.20060
23. Parks DA, Granger DN: Contributions of ischemia and reperfusion to mucosal lesion formation. *Am J Physiol*, 250 (6): G749-G753, 1986. DOI: 10.1152/ajpgi.1986.250.6.G749
24. Gennaro M, Ascer E, Matano R, Jacobowitz IJ, Cunningham JN, Uceda P: Acute mesenteric ischemia after cardiopulmonary bypass. *Am J Surg*, 166 (2): 231-236, 1993. DOI: 10.1016/S0002-9610(05)81062-1
25. Tsikas D: Assessment of lipid peroxidation by measuring malondialdehyde (MDA) and relatives in biological samples: Analytical and biological challenges. *Ana Biochem* 524, 13-30, 2017. DOI: 10.1016/j.ab.2016.10.021
26. Kamel M, Ahmed SM, Abdelzaher W: The potential protective effect of modafinil in intestinal ischemic reperfusion-induced in rats. *Int Immunopharmacol*, 88, 106983, 2020. DOI: 10.1016/j.intimp.2020.106983
27. Arda-Pirincci P, Bolkent S: The role of epidermal growth factor in prevention of oxidative injury and apoptosis induced by intestinal ischemia/reperfusion in rats. *Acta Histochem*, 116 (1): 167-175, 2014. DOI: 10.1016/j.acthis.2013.07.005
28. Woo KK, Ngou FH, Ngo LS, Soong WK, Tang PY: Stability of betalain pigment from red dragon fruit (*Hylocereus polyrhizus*). *Am J Food Technol*, 6 (2): 140-148, 2011. DOI: 10.3923/ajft.2011.140.148
29. Harahap NS, Sinaga FA, Nailuvar R, Amelia R: Effect of red-fleshed pitaya (*Hylocereus polyrhizus*) to increase glutathione peroxidase levels in male rats (*Rattus norvegicus*): The Induced Oxidative Stress. In, *Proceedings of The 5<sup>th</sup> Annual International Seminar on Trends in Science and Science Education, AISTSE 2018*, 18-19 October 2018, Medan, Indonesia 2018. DOI: 10.4108/eai.18-10-2018.2287360