

## The Effect of Kefir on the Healing of Colonic Anastomosis in Rabbits

Yusuf GUNERHAN \*   
Celal Sahin ERMUTLU\*\*\*\*

Barlas SULU\*  
Aksem AKSOY\*\*\*\*\*

Baris OZTURK\*\*  
Fatih BUYUK\*\*\*\*\*

Sevil ATALAY VURAL\*\*\*

\* Department of Surgery, Faculty of Medicine, University of Kafkas, Kars - TURKEY

\*\* Faculty of Medicine, University of Kafkas, Kars - TURKEY

\*\*\* Department of Pathology, Faculty of Veterinary Medicine, Ankara University, Dışkapı, Ankara - TURKEY

\*\*\*\* Department of Surgery, Faculty of Veterinary Medicine, University of Kafkas, Kars - TURKEY

\*\*\*\*\* Kars Vocational School, University of Kafkas, Kars - TURKEY

\*\*\*\*\* Department of Microbiology, Faculty of Veterinary Medicine, University of Kafkas, Kars - TURKEY

Yayın Kodu (Article Code): 2008/99-A

### Summary

The present study was investigated the effect of kefir on anastomosis healing and bacterial translocation in rabbits with colonic anastomosis following colon preparation with laxative and antibiotic (AB) use. For this aim, 16 rabbits were divided into two groups each having 8 rabbits. All rabbits had prepared for surgery and received preoperative antibiotics. Control group received standard rabbit diet and water. The experimental group received 30 ml/kg kefir per day in addition to standard feeding, for 5 days before and after the operation. Right colonic resection and end-to-end anastomosis were done in both groups. Anastomosis bursting pressure and bacterial translocation were investigated on the fifth day after the operation. Also, histopathological evaluation was done. No bacterial growth was observed in blood cultures. However, mesenteric lymph node samples showed bacterial growth in two rabbits (one from each group). Mean anastomosis bursting pressure was  $85.0 \pm 17.5$  mmHg and  $133.75 \pm 25.03$  mmHg in the control and experimental group, respectively, with a statistically significant difference ( $P < 0.01$ ). Histopathological examination of the sections from the anastomosis sites revealed similar findings in both groups such as increased connective tissue proliferation and vascularisation. The increased bursting pressure in the experimental group particularly suggests that kefir may contribute to the healing of colonic anastomosis.

**Keywords:** Rabbit, Colonic anastomosis, Kefir, Bursting pressure, Bacterial translocation, Healing

## Kolon Anastomozu Yapılan Tavşanlarda Kefirin İyileşme Üzerine Etkisi

### Özet

Bu çalışmada, deneysel olarak kolon anastomozu yapılan tavşanlarda kefirin iyileşme üzerine etkisi araştırıldı. Bu amaçla gerekli ön hazırlıkları yapılan ve ameliyat öncesi antibiyotik (AB) verilen toplam 16 tavşan, 8'erli iki gruba ayrıldı. Kontrol grubuna standart tavşan yemi ve su verilirken deney grubuna ameliyat öncesi ve sonrası beşer gün 30 ml/kg kefir standart yeme eklendi. Her iki grupta da ascendens kolon rezeksiyonu ve uç uca anastomoz yapıldı. Ameliyat sonrası 5. gün anastomoz patlama basıncı ve bakteri translokasyonuna bakıldı. Ayrıca, histopatolojik olarak değerlendirildi. Araştırma gruplarından alınan kan örneklerinde bakteri üremesi görülmezken hem deney hem kontrol grubunda birer tavşanda mezenter lenf bezinde bakteri üremesi tespit edildi. Deney grubunda anastomoz patlama basıncı ortalaması  $133.75 \pm 25.03$  mmHg, kontrol grubunda ise  $85.0 \pm 17.5$  mmHg olarak belirlenmiş ve gruplar arasındaki fark istatistiki olarak önemli bulundu ( $P < 0.01$ ). Anastomoz bölgesi bağırsak kesitlerinin histopatolojik incelemelerinde her iki grupta, bağ dokusu proliferasyonu ve damarlaşmada artış gibi benzer bulgular gözlemlendi. Deney grubunda özellikle patlama basıncı ortalamasının daha yüksek düzeyde saptanması, kefirin kolon anastomozu iyileşmesine katkı sağladığını düşündürülebilir.

**Anahtar sözcükler:** Tavşan, Kolon anastomozu, Kefir, Patlama basıncı, Bakteri translokasyonu, İyileşme



İletişim (Correspondence)



+90 474 212 25 66



ygunerhan@gmail.com

## INTRODUCTION

Among the surgical procedures of the gastrointestinal system, colon anastomoses are more challenging than the anastomoses of stomach and small intestine <sup>1-3</sup>. Up to 30% leakage rates have been reported for colon anastomoses <sup>4</sup>. Several measures are important for the prevention of anastomosis leakage, mainly avoidance of tension and provision of adequate blood supply. Changes in colon flora also affect the healing of anastomosis. Early postoperative enteral nutrition, supplementation with glutamine, and use of tyrosylol, misoprostol, zinc or non-steroid anti-inflammatory drugs have already been investigated for their role in supporting the healing process of the anastomosis and reducing postoperative risks <sup>5-9</sup>.

Beneficial effects of prebiotics on intestines, the largest organ involved in immune processes, are already known <sup>10</sup>. Prebiotics decreases the tendency for infection by reducing bacterial translocation. In addition, they promote nutrition and healing of colon mucosa through an increased production of short chain fatty acids. Kefir is a fermented dairy product rich in probiotics. It results from the fermentation of milk lactose by lactic acid bacteria and yeast <sup>11</sup>.

Colon preparation is frequently done before elective colon resections <sup>2</sup>. In colon preparation, in addition to emptying the colon content by laxatives and enema, antibiotics are also used. Mechanical preparation, antibiotic use and low fiber diet impair short chain fatty acid production by decreasing bacterial content of the colon, which unfavorably effects mucosal healing. Antibiotic use is known to increase the tendency for infections and delay wound healing due to the suppression of immunity <sup>12</sup>.

The present study was investigated the effect of kefir on anastomosis healing and bacterial translocation in rabbits with right colonic anastomosis following colon preparation with laxative and antibiotic use.

## MATERIAL and METHODS

**Animals:** The present study was done at Laboratory of Experimental Animals, Veterinary Faculty of Kafkas University, using 16 male New

Zealand rabbits (average weight: 3 kg, range: 2.7 to 3.2). Study was approved by Ethical Commity of Kafkas University (Code: 2008/06).

**Pre-operative procedure:** Adequate intake of standard rabbit food and water was provided in all animals for 10 days. Then, rabbits were divided into the experimental and control groups each having 8 animals. For the next five days, kefir was added to the diet of the experimental group (30 ml/kg per day), whereas the control group continued to receive the same standard food. In both groups, colon preparation was done by inducing diarrhea using 1 ml/kg of anthraquinone one day before the operation.

**Surgical procedure:** All rabbits received anesthesia with xylazine HCl (Rompun 2% - Bayer) 5 mg/kg and ketamine HCl (Pfizer, Turkey) 30 mg/kg, and all received a single dose of antibiotic (40 mg/kg, ceftriaxone disodium IM, FAKO, Turkey). Abdominal hair was removed and surgical site was cleansed using povidone iodine. Under aseptic conditions, the abdomen was opened through a midline incision and 2 cm of the ascending colon was resected. The ends of the colon was anastomosed using two layers of sutures (single stitches of 3/0 Vicryl® and 3/0 silk). Peritoneum and fascia was closed with continuous sutures using 3/0 Vicryl® and abdominal skin was sutured continuously with 3/0 silk.

**Post-operative procedure:** After the operation, animals continued to receive their diets (standard diet in controls versus standard diet plus daily 30 ml/kg of kefir in the control group). All rabbits were re-operated on the fifth postoperative day. Blood samples were obtained from the portal vein for the determination of bacterial translocation. In addition, mesenteric lymph nodes were sampled at the site of anastomosis. Ex vivo measurements were done for the determination of bursting pressure <sup>12</sup>.

**Bursting pressure measurements:** The removed part of right colon was tied 3 cm distal to the anastomosis. Air pump and pressure meter connections were made through a tube placed 3 cm proximal to the anastomosis. The part of colon was slowly filled with air under water. The highest intraluminal pressure reached before bursting of the anastomosis was recorded in mmHg.

**Histopathological examinations:** Samples of

the anastomosed intestines were fixed in 10% formaldehyde and embedded in paraffin blocks. Cross-sections of 5 µm thickness were obtained from each paraffin blocks and stained with Hematoxylin&Eosin (HE) for histopathological examination <sup>13</sup>, and the sections were examined under light microscope. For histomorphological examination, 10 area were rated as mild (+), moderate (++) and severe (+++) <sup>14</sup>.

**Microbiological examinations:** Appropriately obtained blood and lymph node samples were inoculated on 7% sheep blood agar (Blood Agar Base Opsoïd) and incubated for 24 to 48 hours at 37°C under aerobic conditions. Bacterial growth was defined using routine criteria.

**Statistical analysis:** SPSS was used for the statistical analysis of data (SPSS, 10.0 Inc. Chicago, IL, USA). Due to the small sample size, Mann-Whitney U test was used for the comparison of bursting pressure measurements among groups <sup>15</sup>. A p value <0.05 was considered significant.

## RESULTS

One rabbit from the control group died at the third postoperative day, therefore it was excluded from the study.

**Microbiological findings:** None of the blood cultures showed bacterial growth. Microbiological examination of the mesenteric lymph nodes from anastomosis sites revealed the presence of bacterial growth in one sample from each group. In the control group, gram positive diplococci and gram negative rods were found, where the experimental group had gram negative coccoids and rare gram positive rods.

**Bursting pressure measurements:** The mean bursting pressure values were 133.75±25.03 mmHg and 85.0±17.5 mmHg in the experimental group and the control group, respectively. The difference was significant (P<0.01) (Table 1).

**Histopathological findings:** Pathological changes of varying degrees were observed in both groups and they are summarized in Table 2 by their severity. Moderate degree of mononuclear cell (MNC - mainly lymphocytes) and polymorphonuclear cell (PMNC - mainly eosinophile

**Table 1.** Mean and median anastomosis bursting pressure values of the groups

**Tabo 1.** Gruplardaki anastomoz patlama basıncı ortalama ve median değerleri

Groups	n	X	S	Median	P<0.01
Experimental group	8	133.7500	25.03569	120.00	P<0.01
Control group	7	85.0000	17.55942	80.00	

**Table 2.** Histopathological findings observed in the groups by severity

**Tablo 2.** Lezyonların şiddetine göre çalışma gruplarındaki histopatolojik bulgular

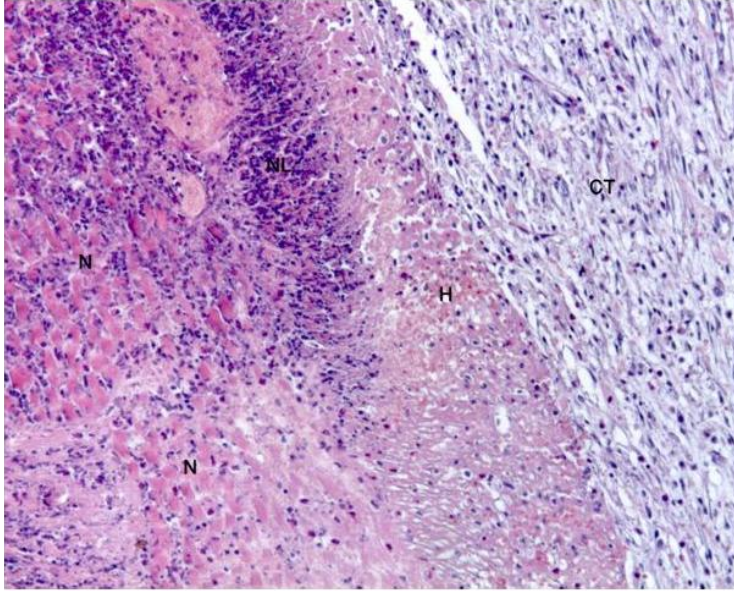
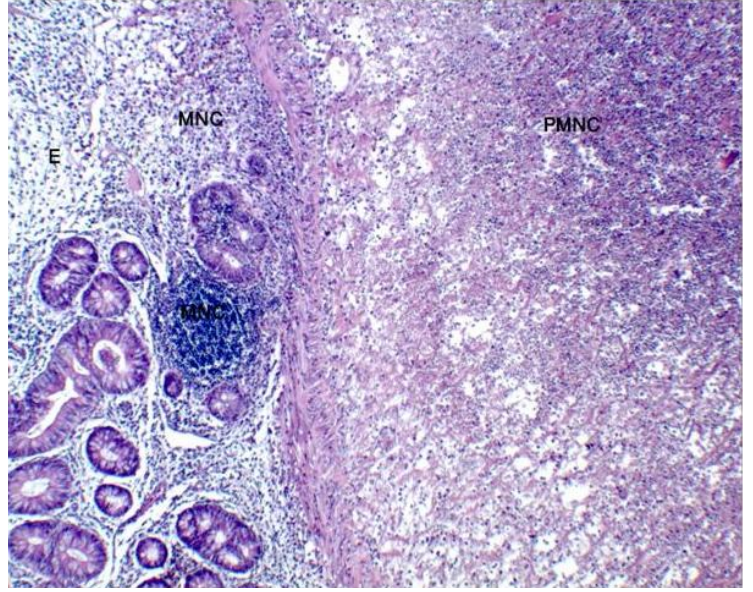
Histopathological findings	Experimental group	Control group
<b>Lamina propria</b>		
Lamina propria	+	++/+++
PMNH infiltration (mainly eosinophile leucocytes)	+/+++	+
Edema	+	+
Hemorrhage	+/++	+
<b>Submucosa</b>		
MNC infiltration	-	+++
PMNC infiltration (mainly eosinophile leucocytes)	++/+++	+/+++
Edema	++/+++	+
Hemorrhage	+/++/+++	+
Connective tissue proliferation	++/+++	+/++
Increased vascularization	++/+++	++/+++
Enlargement of lymphatics	+/++	-
<b>Tunica muscularis</b>		
PMNC infiltration	+++	+++
Necrose	+++	+++
Hyalinization	+	+
Microbial aggregation	+	+
Hemorrhage	+++	+
Degenerative changes in the vessel walls	++	-

leukocytes) cell infiltrations with areas of edema and hemorrhage were observed at lamina propria (Figure 1). Similar changes were also present in the submucosa with a mild to moderate severity. In addition to the changes, the experimental group exhibited a moderate degree of connective tissue proliferation (Figure 2), increased vascularization (Figure 3) and mild to moderate enlargement of the lymphatics. In all animals, severe neutrophile infiltrations in tunica muscularis with necrosis (Figure 2) and hyaline degeneration of muscle fibers was observed.



**Fig 1.** Edema (E) and MNC infiltrations in lamina propria, and PMNC infiltrations in submucosa. Experimental group, HEx100

**Şekil 1.** Lamina propriada ödem (E), MNH infiltrasyonları, ve submukozada PMNH infiltrasyonları, I. Grup, HEx100

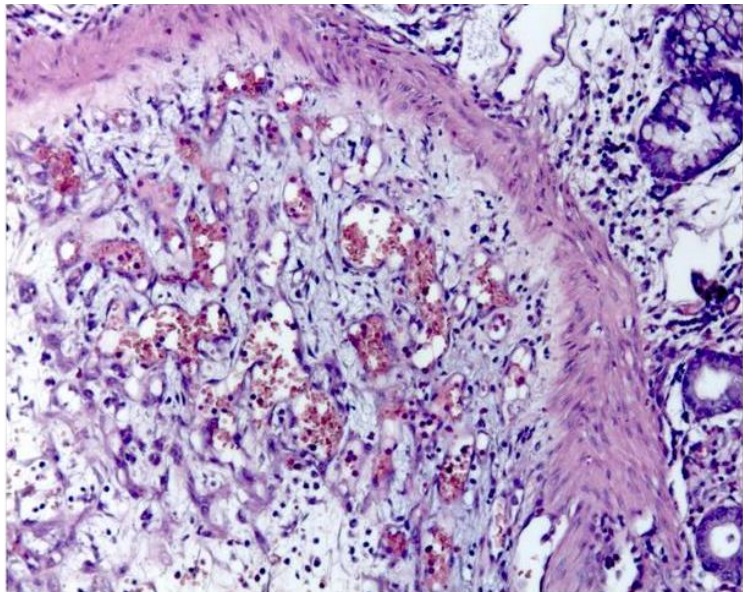


**Fig 2.** Connective tissue proliferation (CT) and hemorrhage (H) in submucosa; neutrophil leukocyte infiltration (NL) in tunica muscularis and necrosis in muscle fibers (N) Experimental group, HE x 40

**Şekil 2.** Submukozada bağdoku proliferasyonu (CT) ve kanama (H), tunika muskulariste nötrofil lökosit infiltrasyonları (NL) ve kas demetlerinde nekroz (N), I. Grup, HE x40

**Fig 3.** Increased vascularization in submucosa. Experimental group, HE x100

**Şekil 3.** Submukozada damarlaşma, I. Grup, HE x100



## DISCUSSION

The increasing side effects of antibiotics and resistance of microorganisms to antibiotics prompted a recent interest in probiotics and prebiotics. Intestinal flora needs modulation when its content or activity is impaired. When pathogenic bacteria are prominent, antibiotics used against them unfavorably affect intestinal flora. In these conditions, substances capable of regulating intestinal flora such as prebiotics and probiotics are required <sup>16</sup>. Kefir is an important source of probiotics with antibacterial and antifungal effects, in addition to its immunostimulant properties. Kefir microflora consists of lactic acid bacteria, acetic acid bacteria and yeast <sup>17</sup>.

Intestines constitute the largest organ of the immune system and several beneficial effects of probiotics on intestines have been identified <sup>10</sup>. Probiotics have also a role in the prevention of bacterial translocation. The role of changes at three distinct sites has been emphasized in the development of translocation: (1) bacterial growth at intestinal lumen due to impaired intestinal motility, (2) injury of intestinal epithelium and (3) suppression of the immune system. Many studies were demonstrated the benefits of probiotics through their effects on the mechanisms <sup>10,11,16,18</sup>. They have a favorable contribution to the prevention of translocation through inhibition of pathogenic bacteria in the intestinal lumen <sup>19,20</sup>, prevention of bacterial attachment to the epithelium, regulation of epithelial permeability and by inhibition of local pro-inflammatory reaction in enterocytes <sup>21,22</sup>. They also have a favorable effect on the immune system by decreasing proinflammatory interleukin 6 production and increasing anti-inflammatory interleukin 10 production <sup>23,24</sup>.

Seehofer et al.<sup>25</sup> found a high rate of bacterial translocation in mesenteric lymph nodes of rats after colonic anastomosis. In another study, bacterial growth was demonstrated in the cultures from mesenteric lymph nodes of rats with induced colitis <sup>26</sup>. In the present study, the blood cultures had no bacterial growth; however one of mesenteric lymph node samples from each group had growth. Strict aseptic practices exercised during the operation and preoperative antibiotic use may account for the low bacteria translocation rate observed in the present study.

In the study of Seehofer et al.<sup>25</sup>, no increase was found in anastomosis bursting pressure, however in several experimental studies using prebiotics and probiotics, significant increases in anastomosis bursting pressure was demonstrated <sup>27</sup>. In the present study, anastomosis bursting pressure was significantly increased in the experimental group, compared to controls (P=0.01).

Probiotics have been reported to promote healing by increasing collagen accumulation and revascularisation <sup>17,25,27</sup>. In the present study, similar pathological changes were seen in the two groups. This may be attributed to the low sample size and too many parameters used. In addition, various degrees of inflammatory changes and microbial aggregations observed in the groups were attributed to possible postoperative complications. However, presence of eosinophile leucocytes both in the experimental and control group was interesting and may be due to an allergic reaction (e.g. against suture material).

The effects of different methods, nutritional patterns and medications on the prevention of leakage from colonic anastomosis have been evaluated. The present study suggests that kefir may have a role in the reduction of anastomosis leakages as evidenced by the significantly increased bursting pressure values observed in the experimental group. However, further studies with a lot sample are warranted to draw firm conclusions.

## REFERENCES

1. Hesp FL, Hendriks T, Lubbers EJ, de Boer HH: Wound healing in the intestinal wall. A comparison between experimental ileal and colonic anastomoses. *Dis Colon Rectum*, 27, 99-104, 1984.
2. Thornton FJ, Barbul A: Healing in the gastrointestinal tract. *Surg Clin North Am*, 77, 549-575, 1997.
3. Matthiessen P, Hallböök O, Andersson M, Rutegård J, Sjö Dahl R: Risk factors for anastomotic leakage after anterior resection of the rectum. *Colorectal Dis*, 6, 462-469, 2004.
4. Fielding LP, Stewart-Brown S, Blesovsky L, Kearney G: Anastomotic integrity after operations for large-bowel cancer: A multicentre study. *Br Med J*, 281 (6237): 411-414, 1980.
5. Tümer AR, Kama NA, Tümer L, Reis E, Müftüoğlu S: Effects of 5-fluorouracil and zinc on healing of colonic anastomoses in rabbits. *Eur J Surg*, 165, 369-377, 1999.
6. Gökpinar I, Gürleyik E, Pehlivan M, Özcan O, Ozaydin I, Aslaner A, Demiraran Y, Gültepe M: Early enteral and glutamine enriched enteral feeding ameliorates healing of colonic anastomosis: Experimental study. *Ulus Travma*



- Acil Cerrahi Derg*, 12, 17-21, 2006.
7. **Young HL, Wheeleer MH:** Collagenase inhibition in the healing colon. *J R Soc Med*, 76, 32-36, 1983.
  8. **de Olivera PG, Soares EG, Aprilli F:** Influence of misoprostol, a synthetic prostaglandin E1 analog, on the healing of colonic anastomoses in rats. *Dis Colon Rectum*, 37, 660-663, 1994.
  9. **Brennan SS, Foster ME, Morgan A, Leaper DJ:** Prostaglandins in colonic anastomotic healing. *Dis Colon Rectum*, 27 (11): 723-725, 1984.
  10. **Vinderola G, Matar C, Perdigon G:** Milk fermentation of *L. helveticus* R389 activate calcineurin as a signal to promote gut mucosal immunity. *BMC Immunol*, 7, 8-19, 2007.
  11. **Yüksekdağ ZN, Beyatlı Y:** Kefir mikroflorası ile laktik asit bakterilerinin metabolik, antimikrobiyal ve genetik özellikleri. *Orlab On-Line Mikrobiyol Derg*, 1, 49-69, 2003.
  12. **Kologlu M, Sayek I, Kologlu LB, Onat D:** Effects of persistently elevated intraabdominal pressure on healing of colonic anastomoses. *Am J Surg*, 178, 293-297, 1999.
  13. **Luna, LG:** Manual of Histologic Staining Methods. McGraw Hill Book Company, 1968.
  14. **Gunerhan Y, Koksall N, Gul O, Uzun MA, Gunes P, Adaleti R:** The effect of unfractionated heparin and low molecular weight heparin on colonic anastomosis in the presence of experimental peritonitis. *Eur Sur Res*, 38 (3): 353-357, 2006.
  15. **Sümbüloğlu K, Sümbüloğlu V:** Biyoistatistik. Hatiboğlu Basım ve Yayımlar San., Ankara, 1998.
  16. **Pham M, Lemberg DA, Day AS:** Probiotics: Sorting the evidence from the myths. *Med J Aust*, 188 (5): 304-308, 2008.
  17. **Atalan G, Demirkan I, Yaman H, Cihan M, Onder F, Sözmen M:** Effect of topical kefir application on open wound healing: An in vivo study. *Kafkas Univ Vet Fak Derg*, 9, 43-47, 2003.
  18. **van Santvoort HC, Besselink MG, Timmerman HM, van Minnen LP, Akkermans LM, Gooszen HG:** Probiotics in surgery. *Surgery*, 143, 1-7, 2008.
  19. **Servin AL:** Antagonistic activities of lactobacilli and bifidobacteria against microbial pathogens. *FEMS Microbiol Rev*, 28, 405-440, 2004.
  20. **van Minnen LP, Timmerman HM, Lutgendorff F, Verheem A, Harmsen W, Konstantinov SR, Smidt H, Visser MR, Rijkers GT, Gooszen HG, Akkermans LM:** Modification of intestinal flora with multispecies probiotics reduces bacterial translocation and improves clinical course in a rat model of acute pancreatitis. *Surgery*, 141 (4): 470-480, 2007.
  21. **Marco ML, Pavan S, Kleerebezem M:** Towards understanding molecular modes of probiotic action. *Curr Opin Biotechnol*, 17, 204-210, 2006.
  22. **Otte JM, Podolsky DK:** Functional modulation of enterocytes by gram-positive and gram-negative microorganisms. *Am J Physiol Gastrointest Liver Physiol*, 286, G613-626, 2004.
  23. **Niers LE, Timmerman HM, Rijkers GT, van Bleek GM, van Uden NO, Knol EF, Kapsenberg ML, Kimpfen JL, Hoekstra MO:** Identification of strong interleukin-10 inducing lactic acid bacteria which down-regulate T helper type 2 cytokines. *Clin Exp Allergy*, 35, 1481-1489, 2005.
  24. **Sugawara G, Nagino M, Nishio H, Ebata T, Takagi K, Asahara T, Nomoto K, Nimura Y:** Perioperative synbiotic treatment to prevent postoperative infectious complications in biliary cancer surgery: A randomized controlled trial. *Ann Surg*, 244 (5): 706-714, 2006.
  25. **Seehofer D, Rayes N, Schiller R, Stockmann M, Müller AR, Schirmeier A, Schaeper F, Tullius SG, Bengmark S, Neuhaus P:** Probiotics partly reverse increased bacterial translocation after simultaneous liver resection and colonic anastomosis in rats. *J Surg Res*, 117, 262-271, 2004.
  26. **Gardiner KR, Erwin PJ, Anderson NH, Barr JG, Halliday MI, Rowlands BJ:** Colonic bacteria and bacterial translocation in experimental colitis. *Br J Surg*, 80, 512-516, 1993.
  27. **Mangiante G, Colucci GL, Gottin L, Casaril A, Ciola M, Facci E, Nicoli N:** Effect of probiotic administration on colic anastomosis healing. *Chir Ital*, 53 (1): 39-44, 2001.