


Erythropoietin Hormone and ACE Inhibitor Protect the Sperm Parameters of Adult Male Rats Against Doxorubicin Toxicity ^[1]

Orhan AKMAN ¹  Yunusemre ÖZKANLAR ² Seçkin ÖZKANLAR ³
Ertan ORUÇ ⁴ Nergis ULAŞ ² Tevfik ZİYPAK ⁵
Necdet Cankat LEHİMCİOĞLU ⁶ Mehmet TÜRKELİ ⁷ Ömer UÇAR ¹

^[1] The abstract of this study was presented at the 7th National Congress on Animal Reproduction and Artificial Insemination (Kars, Turkey, 1-4 July 2013)

¹ Ataturk University, Faculty of Veterinary Medicine, Department of Reproduction and Artificial Insemination, TR-25240 Erzurum - TURKEY; ² Ataturk University, Faculty of Veterinary Medicine, Department of Internal Medicine, TR-25240 Erzurum - TURKEY; ³ Ataturk University, Faculty of Veterinary Medicine, Department of Biochemistry, TR-25240 Erzurum - TURKEY; ⁴ Ataturk University, Faculty of Veterinary Medicine, Department of Pathology, TR-25240 Erzurum - TURKEY; ⁵ Ataturk University, Faculty of Medicine, Department of Urology, TR-25240 Erzurum - TURKEY; ⁶ Kafkas University, Faculty of Veterinary Medicine, Department of Reproduction and Artificial Insemination, TR-36300 Kars - TURKEY; ⁷ Ataturk University, Faculty of Medicine, Department of Medical Oncology, TR-25240 Erzurum - TURKEY

KVFD-2015-13412 Received: 22.03.2015 Accepted: 22.04.2015 Published Online: 24.04.2015

Abstract

Doxorubicin (DXR) is used against the cancer but it has some adverse effects (gonadotoxicity, cardiotoxicity and nephrotoxicity). We aimed to determine the effect of DXR toxicity on reproduction and whether Darbepoetin (DP) and Ramipril (RAM) treatments play a protective role against this toxicity in male rats. Herein, adult male Sprague-Dawley rats (n=34) were divided randomly into five groups, as control (Group I; n=7, no medication) and four treatment groups (II to V). DXR was administered to all treatment groups (DXR, 2.5 mg/kg/w i.v. for 3 weeks) and they were Group II (DXR, n=6), Group III (n=7, DP 10 µg/kg/w i.p. for three weeks), Group IV (n=7, RAM 1 mg/kg/d p.o. for four weeks), and Group V (n=7, DP+RAM). Rats in all groups were sacrificed after four weeks of treatment. Spermatological parameters along with histopathological images and malondialdehyde levels of testicular tissue were evaluated. Weights of body, testicles, cauda epididymis and male accessory glands in DXR-treated groups were significantly different (P<0.05) from the control group. DXR toxicity adversely altered all the sperm parameters. But, DP plus RAM treatment in Group V improved the DXR-depressed motility and viable sperm rate. Sperm concentrations significantly decreased (P<0.05) in DXR-treated groups as compared to control group. In Group III and V, the increase in total abnormal sperm rate caused by the DXR injections was prevented. In conclusion, this study indicated that weekly DXR injections in adult rats depressed all the epididymal sperm parameters. Co-treatment by DP and RAM protected the sperm cells against the toxicity due to the DXR administration while single usages of the DP or RAM provided partial improvements.

Keywords: Doxorubicin toxication, Erythropoietin, ACE inhibitor, Rat sperm

Eritropoietin Hormonu ve ACE İnhibitörü, Erişkin Erkek Sıçanların Sperm Parametrelerini Doxorubicin Toksisitesine Karşı Korur

Özet

Kanser tedavisinde kullanılan Doxorubicin'in (DXR), kardiyotoksik ve nefrotoksik yan etkileri ile birlikte gonadotoksik özelliği de bulunmaktadır. Bu çalışmada, yetişkin erkek Sprague-Dawley sıçanlardaki sperm parametreleri üzerine DXR'nin toksik etkisi ile Darbepoetin (DP) ve Ramipril (RAM) tedavisinin bu toksikasyonu önleyici bir rolünün olup olmadığı araştırıldı. Yetişkin 34 adet erkek Sprague-Dawley sıçanlar rastgele 5 gruba ayrıldı. Kontrol grubunda bulunan sıçanlarda (Grup I; n=7) hiçbir ilaç kullanılmadı. Tüm tedavi gruplarında bulunan sıçanlara DXR uygulaması (DXR, 2.5 mg/kg/hafta i.v. 3 hafta, n=27) yapıldı ve bu gruplar Grup II (DXR, n=6), Grup III (DP 10 µg/kg/hafta i.p. 3 hafta, n=7), Grup IV (RAM 1 mg/kg/gün p.o. 4 hafta, n=7) ve Grup V'ten (DP+RAM, n=7) oluştu. Dört haftalık deneysel çalışma sonrasında tüm sıçanlara ötenazi uygulandı. Spermatolojik parametrelerle birlikte histopatolojik muayene ve testiküler dokulardaki malondialdehit (MDA) düzeyleri incelendi. DXR uygulanan gruplardaki ölçülen vücut, testis, cauda epididimis ve erkek eklenti bezlerinin ağırlıkları ile kontrol grubu parametreleri arasında önemli fark gözlemlendi (P<0.05). DXR toksisitesi tüm sperm parametrelerini olumsuz yönde etkiledi. Grup V'teki DP+RAM tedavisi, DXR'nin motilite ve canlı sperm oranı üzerine yaptığı toksik etkiyi önledi. Kontrol grubuna kıyasla, DXR uygulanan gruplardaki sperm yoğunluğu önemli derecede (P<0.05) düşüktü. Grup III ve V'te, DXR enjeksiyonuna bağlı total anormal sperm oranındaki artış önlemlendi. Sonuç olarak; bu çalışmada haftalık DXR enjeksiyonlarının yetişkin sıçanlarda tüm epididimal sperm parametrelerini olumsuz yönde etkilediği belirlendi. Birlikte kullanılan DP ve RAM tedavisi sperm hücrelerini DXR uygulamasına bağlı oluşan toksisiteye karşı korurken, DP ve RAM'in tek başına kısmi iyileşme sağladı.

Anahtar sözcükler: Doxorubicin toksisitesi, Eritropoietin hormonu, ACE inhibitörü, Sıçan spermi



İletişim (Correspondence)



+90 442 2315547; Fax: +90 442 2315563



orhanakman@hotmail.com

INTRODUCTION

Doxorubicin (DXR), obtained from *Streptomyces peucetius* in 1970s, is an anthracycline antibiotic and used in cancer chemotherapy [1,2]. It inhibits the cancer cells and undesirably induces apoptosis in healthy cells, causing organ failures in heart, kidney, intestine, hair follicle, ovarium and testes [3,4]. Gonadotoxic effects of DXR disturb the spermatogenesis in testes leading to changes adversely affecting the male fertility [5,6]. Lipid peroxidation and oxidative stress result in malondialdehyde (MDA) production [7,8].

Erythropoietin (EPO) is a hormone required for proliferation, survival and differentiation of erythroid stem cells [9]. The EPO receptors (EPO-R) are found in many organs of both genders [10]. It has potential roles other than haematopoiesis and treatment of anaemia since the EPO and EPO-R are located in the tissues of brain, spinal cord, heart, gastrointestinal tract, lung, testes and leydig cells [11-13]. A new long-acting EPO analogue darbepoetin alpha (DP), stimulating erythropoiesis by the EPO-R, was used in the present study [14].

Angiotensin converting enzyme (ACE) converts the angiotensin I (A-I) to angiotensin II (A-II) and plays a role in the renin-angiotensin system (RAS) to regulate body fluids and electrolytes for maintaining blood pressure via the inactivation of bradykinin [15-17]. The ACE genes are encoded isoforms of both somatic (sACE) and testis-specific (tACE) genes [17,18]. The sACE, rather than the tACE, is responsible for male fertility. The ACE is involved in the regulation of fluid and electrolyte transport within the epididymis during the A-II activation and it is thus involved locally in the RAS of the epididymis [19,20]. The therapeutic effects of DP and RAM against the DXR-induced toxicity have been demonstrated recently [21].

Therefore, the aim of this study was to determine the protective effects of DP as an erythropoietin hormone and RAM as an ACE inhibitor treatment against the DXR toxicity on testicular and sperm parameters in adult male rats.

MATERIAL and METHODS

Thirty-four adult male Sprague-Dawley rats were supplied from Atatürk University Medical Experimental and Research Centre (Erzurum, Turkey). Rats were accommodated under 12 h light and 12 h darkness regime and provided standard pellet food and drinking water *ad libitum*.

Rats were divided into 5 groups as control and four treatment groups. Group I (Control) (n=7) had no medication and was given placebo (physiologic saline solution) into tail veins. Group II (DXR, n=6) received a dose of 2.5 mg/kg/w DXR (Doxorubicin hydrochloride, Adriblastina 50 mg, Deva, Pfizer Inc., USA) via tail veins weekly for three weeks. Group III (DP, n=7) had DXR plus 10 µg/kg/w i.p. DP (Darbepoetin alfa, Aranesp 10 µg, Eczacibasi, Amgen Inc., USA) weekly for three weeks. DXR and DP were administered weekly on days zero, 7, 14 and 21 relative to the initiation of the study. Group IV (RAM, n=7) received DXR plus 1 mg/kg/d p.o. RAM (Ramipril, Delix 5 mg, Sanofi, Pharma Vision, Turkey) daily for four weeks. Finally, Group V had DXR, DP and RAM at the same dose and duration, as above (groups II-IV). Following the animals being sacrificed under deep anaesthesia performed routinely (5 mg/kg Xylazine [Rompun, Bayer Inc., Germany] and 50 mg/kg Ketamine [Ketalar, Pfizer Inc., USA]), sampling was obtained at the 4th weeks of treatments. Treatment protocols for the groups are presented in *Table 1*.

The weights of body, testes, cauda epididymis and total male accessory gland (prostate, vesicular gland and coagulating gland) were measured in the groups. One testicle was kept at -20°C for biochemical analysis, while the other was placed into Bouin's solution for histopathological evaluation. The collections of cauda epididymal sperm and assessment of sperm parameters (namely motility, live-dead sperm and abnormal sperm rates) were performed [under the phase contrast microscope (Carl Zeiss Axio Scope.A1) on a warmed stage at 35.5±0.5°C] by modification of the method described by Akman and

Table 1. Experimental protocols and drug administrations

Tablo 1. Çalışma protokolü ve ilaç uygulamaları

Groups	n	Treatments			
		1. Week	2. Week	3. Week	4. Week
Group I (Control)	7	Physiologic saline i.v.	Physiologic saline i.v.	Physiologic saline i.v.	
Group II (DXR)	6	DXR 2.5 mg/kg/w i.v.	DXR 2.5 mg/kg/w i.v.	DXR 2.5 mg/kg/w i.v.	
Group III (DXR+DP)	7	DXR 2.5 mg/kg/w i.v. DP 10 µg/kg/w i.p.	DXR 2.5 mg/kg/w i.v. DP 10 µg/kg/w i.p.	DXR 2.5 mg/kg/w i.v. DP 10 µg/kg/w i.p.	
Group IV (DXR+RAM)	7	DXR 2.5 mg/kg/w i.v. RAM 1 mg/kg/d p.o.	DXR 2.5 mg/kg/w i.v. RAM 1 mg/kg/d p.o.	DXR 2.5 mg/kg/w i.v. RAM 1 mg/kg/d p.o.	RAM 1 mg/kg/d p.o.
Group V (DXR+DP+RAM)	7	DXR 2.5 mg/kg/w i.v. DP 10 µg/kg/w i.p. RAM 1 mg/kg/d p.o.	DXR 2.5 mg/kg/w i.v. DP 10 µg/kg/w i.p. RAM 1 mg/kg/d p.o.	DXR 2.5 mg/kg/w i.v. DP 10 µg/kg/w i.p. RAM 1 mg/kg/d p.o.	RAM 1 mg/kg/d p.o.

Note: DXR and DP were administered via tail vein weekly on days zero, 7, 14 and 21. RAM was administered by oral route daily on days zero to 28. DXR: doxorubicin, DP: darbepoetin, RAM: ramipril

Aksoy [22]. The sperm concentration was determined with a Neubauer counting chamber, by using modified method of Türk et al. [23]. The MDA level was determined according to the method of Ohkawa et al. [24].

In histopathological examination of testicular tissue, the samples taken for histopathological preparations were fixed in Bouin's solution. After the routine follow-up procedures of alcohol-xylene, the sections of 5 µ paraffin blocks were stained with hematoxylin-eosin (HE) and examined under a light microscope (Olympus BX51 with DP72 camera, Japan) routinely. For statistical analyses, the number of normal spermatogenic cells (non-degenerative or non-necrotic) within a given tubulus seminiferus contortus was counted, as follows: For each slide selected from each group, the normal cell numbers were driven by considering randomly chosen cells observed in five different areas of 500±10 mm² found on each unit of the tubulus seminiferus contortus.

Atatürk University Local Board of Ethics Committee for Animal Experiments has approved the study protocol of this research (HADYEK decision no: 2013/61).

Statistical Analysis

All statistical analyses were carried out using SPSS statistical software programme (SPSS for MAC, version 20.0). Biochemical, histopathological and spermatological results were presented as means ± S.E.M. One-way analysis of variance (ANOVA) and post hoc Tukey test were used to determine differences in all the parameters between the groups. The values were considered significant when P<0.05.

RESULTS

The weights of body (P<0.05), total testicles (P<0.000), total cauda epididymis (P<0.01) and total male accessory gland (P<0.001) were significantly higher in the control group than those in all other (treatment) groups (Table 2).

The MDA levels of testicular tissue were presented in Table 3. DXR administration increased the MDA level in Group II in comparison with that of control group (P<0.000).

The DP administration prevented this increase in Group III. The MDA levels in Group IV and Group V increased as compared with that of control group. However, the RAM and DP plus RAM administrations only slightly decreased this level as compared with that of Group II.

In histopathological examinations, seminiferous tubule area, seminiferous tubule lumen area, germinative epithelial area, as well as vascular and necrotic changes were evaluated. The comparisons of histopathological changes were presented in Fig. 1 and Table 4. Vascular changes such as oedema and hyperaemia were observed in Groups II-IV. The oedema and hyperaemia decreased in Group V. The area of tubulus seminiferus in the testes of Group II receiving the DXR was significantly lower than in the control group (P<0.005). Only the DP or RAM administrations did not prevent the damage induced by the DXR injection (P>0.05). However, the combined administration of DP+RAM prevented the DXR-induced damage (P<0.05) as comparable to that of the control group (P>0.05). The total area of tubulus seminiferus lumen in the testes of Group IV was significantly smaller than in the control group (P<0.05). Severe necrosis was seen in spermatogenic cells in Group II. The administration of DXR in Group II significantly decreased the area of the germinal epithelial cells as compared to that of the control group (P<0.01). Only the DP or RAM administrations could not prevent the damage caused by the DXR (P>0.05). However, the DP plus RAM administrations together

Table 3. MDA levels in testicular tissue of DXR and treatment groups (Mean ± SEM)

Tablo 3. DXR ve tedavi gruplarının testiküler dokudaki MDA seviyeleri (Ortalama ± SEM)

Groups	n	MDA Level (nmol/mg tissue)
Group I	7	13.33±1.15 ^a
Group II	6	26.14±3.93 ^c
Group III	7	15.16±1.17 ^{ab}
Group IV	7	19.29±1.42 ^{bc}
Group V	7	18.71±1.40 ^{bc}

^{a-c} Means having different superscripts within a row are significantly different from each other (at least P<0.05)

Table 2. The weights of body, testicles, cauda epididymis and male accessory glands (Mean ± SEM)

Tablo 2. Vücut, testis, cauda epididimis ve erkek eklenti bezlerinin ağırlıkları (Ortalama ± SEM)

Group	n	Body Weight (g)	Total Testis Weight (mg)	Total Cauda Epididymal Weight (mg)	Male Accessory Glands Weight (mg)
Group I	7	314.00±12.33 ^a	3046.86±69.24 ^a	453.71±24.89 ^a	2564.43±172.69 ^a
Group II	6	259.33±12.64 ^b	2020.17±117.00 ^b	368.33±24.17 ^b	1585.67±153.13 ^b
Group III	7	238.29±10.16 ^b	1941.14±103.45 ^b	341.71±13.74 ^b	1358.71±179.35 ^b
Group IV	7	256.86±13.37 ^b	1963.14±52.14 ^b	363.57±21.05 ^b	1588.43±179.92 ^b
Group V	7	259.71±9.65 ^b	2028.43±74.10 ^b	362.14±24.72 ^b	1676.57±202.63 ^b

^{a-b} Means having different superscripts within a row are significantly different from each other (at least P<0.05)

Table 4. Histopathological evaluations of the effects of DXR and treatment groups on testicular tissue (Mean \pm SEM)**Tablo 4.** DXR ve tedavi gruplarının testiküler doku üzerine etkilerinin histopatolojik değerlendirmeleri (Ortalama \pm SEM)

Group	n	Histopathological Parameters			
		Seminiferous Tubule Area (μm^2)	Seminiferous Tubule Lumen Area (μm^2)	Germinative Epithelial Area (μm^2)	Nucleated Cell Number (502.63 \pm 1.58 μm^2)
Group I	7	21326.23 \pm 816.65 ^a	9889.12 \pm 536.14 ^a	11437.11 \pm 1259.89 ^a	71.00 \pm 4.98 ^a
Group II	6	12568.13 \pm 1819.78 ^c	7718.71 \pm 1035.36 ^{ab}	4849.42 \pm 1191.30 ^b	31.80 \pm 9.51 ^b
Group III	7	14327.42 \pm 2007.27 ^{bc}	8551.97 \pm 987.29 ^{ab}	5702.20 \pm 556.44 ^b	39.60 \pm 5.11 ^b
Group IV	7	11665.80 \pm 485.11 ^c	5963.60 \pm 278.36 ^b	5775.45 \pm 1084.84 ^b	48.75 \pm 4.77 ^{ab}
Group V	7	18593.06 \pm 941.14 ^{ab}	7410.76 \pm 263.85 ^{ab}	11182.30 \pm 1118.10 ^a	54.80 \pm 4.91 ^{ab}

^{a-c} Means having different superscripts within a row are significantly different from each other (at least $P < 0.05$)

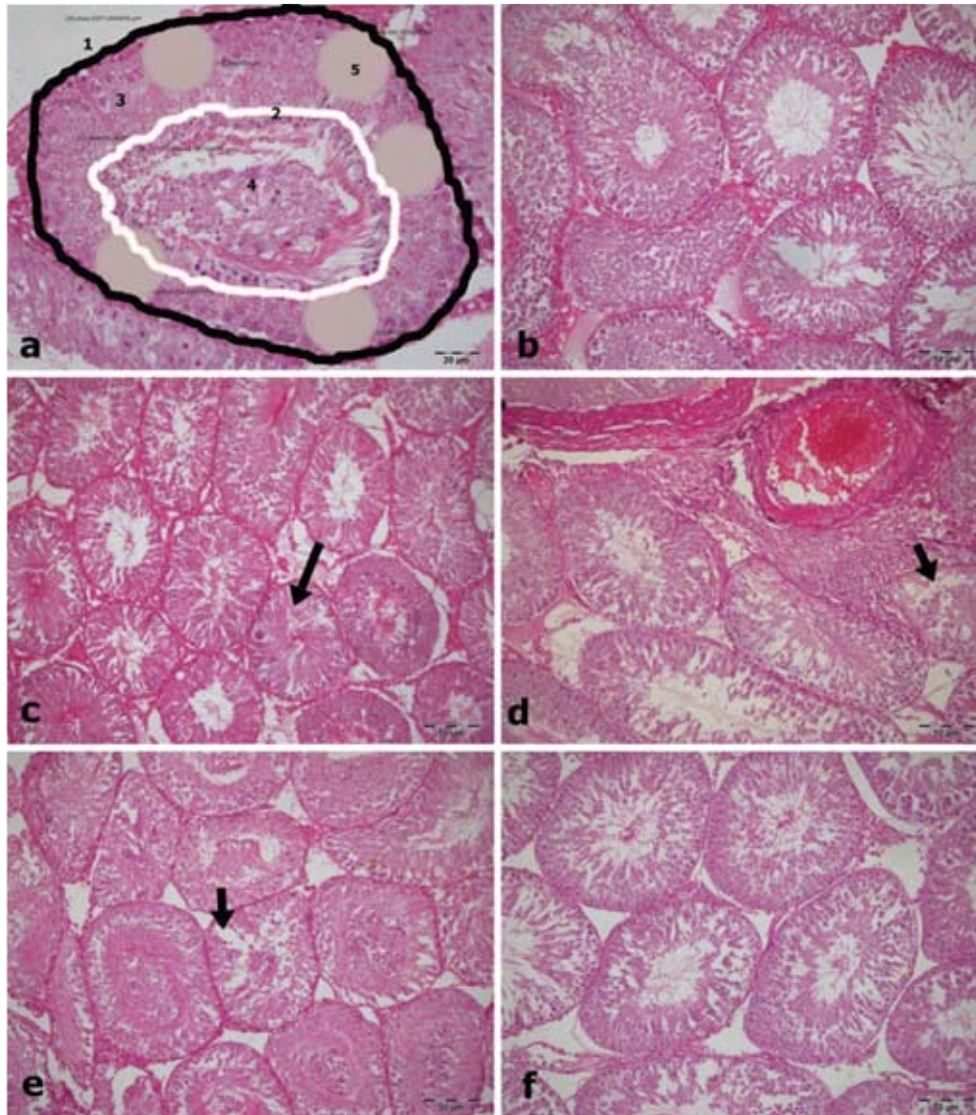


Fig 1. a: Measuring and counting methods of tubulus seminiferus contortus (1- seminiferous tubule area, 2- luminal space line of tubulus seminiferus contortus, 3- germinative epithelial area, 4- seminiferous tubule lumen area, 5- selected areas for spermatik cell counting), **b-f:** histopathologic comparison of tubulus seminiferus contortus and spermatik cell (b: Control group, c: Group II (DXR), d: Group III (DXR+DP), e: Group IV (DXR+RAM), f: Group V (DXR+DP+RAM), arrows: necrotic tubuli), (HE)

Şekil 1. a: Tubulus seminiferus kontortusun ölçüm ve sayım yöntemleri. (1- Seminifer tubul toplam alanı, 2- Seminifer tubul lumeninin sınırı, 3- Germinatif epitel alanı, 4- Seminifer tubulün lumen alanı, 5- spermatik hücre sayımı için rastgele seçilen alanlar), **b-f:** Tubulus seminiferus kontortus ve spermatik hücrelerin histopatolojik karşılaştırması (b: Kontrol grubu, c: Grup II (DXR), d: Grup III (DXR+DP), e: Grup IV (DXR+RAM), f: Grup V (DXR+DP+RAM), oklar: nekrotik tubuluslar ve spermatik hücreler), (HE)

ameliorated the DXR-induced damage as compared to that of the control group ($P > 0.05$). The DXR administration significantly decreased the number of normal cells of the germinal epithelium in Group II as compared to that of the control group ($P < 0.01$). Only numerical improvements were obtained by the administrations of RAM and DP plus RAM ($P > 0.05$).

Epididymal sperm parameters obtained in this study were presented in *Table 5*. The DXR toxicity adversely affected all the percentages of epididymal sperm motility rate, live-dead sperm ratio, sperm density, head abnormality rate and total sperm abnormality rate ($P < 0.05$). The DP plus RAM treatment prevented the depressive effects of DXR on the motility and live-dead sperm rate ($P < 0.05$). However,

Table 5. Effects of DXR and treatment groups on sperm parameters in adult male rats (Mean \pm SEM)**Tablo 5.** DXR ve tedavi gruplarının erişkin erkek sıçan sperm parametreleri üzerine etkileri (Ortalama \pm SEM)

Group	n	Sperm Parameters				
		Motility (%)	Dead Sperm (%)	Concentration ($\times 10^6$ sperm/ml)	Head Abnormality (%)	Total Abnormality (%)
Group I	7	49.59 \pm 1.56 ^a	38.26 \pm 1.62 ^a	60.27 \pm 6.49 ^a	9.44 \pm 1.16 ^a	13.99 \pm 1.22 ^a
Group II	6	23.23 \pm 1.64 ^c	62.43 \pm 3.17 ^c	29.95 \pm 3.40 ^b	14.07 \pm 1.22 ^b	21.53 \pm 1.13 ^c
Group III	7	30.23 \pm 4.56 ^{bc}	58.34 \pm 4.54 ^{bc}	33.93 \pm 3.88 ^b	12.51 \pm 0.98 ^{ab}	17.21 \pm 0.86 ^{ab}
Group IV	7	31.00 \pm 2.51 ^{bc}	59.16 \pm 2.7 ^{bc}	39.17 \pm 6.33 ^b	14.37 \pm 1.45 ^b	19.74 \pm 2.04 ^{bc}
Group V	7	42.51 \pm 1.17 ^{ab}	46.94 \pm 1.28 ^{ab}	29.58 \pm 3.66 ^b	11.73 \pm 0.72 ^{ab}	17.10 \pm 1.39 ^{ab}

^{a-c} Means having different superscripts within a row are significantly different from each other (at least $P < 0.05$)

the RAM or DP administrations as both given alone had no such protective effect on these parameters. Additionally, the DP and DP plus RAM administrations prevented the total sperm abnormalities induced by the DXR ($P < 0.01$).

DISCUSSION

The effects of DXR on cancer cells are; i) the inhibition of topoisomerase-II that regulates the progress of DNA to interference with the DNA strand separation and helicase activity within the nucleus [2], ii) the generation of free radicals in cancer cells and cell membranes resulting in a damage to the DNA and protein structures [2,25], and iii) the respiratory disruption leading to the release of cytochrome-C initiating apoptosis within the mitochondria [26]. Thus, the DXR inhibits the synthesis of DNA, RNA and protein by triggering the apoptotic pathway of cell death and thus inducing the DNA damage [2,26,27]. The mechanism of this effect is not only for cancer cells, but it also occurs as a result of a general toxicity on normal cells [28]. The main reason for the limitation of the use of DXR is its cardiotoxic properties [3]. In addition to the cardiotoxicity and nephrotoxicity of DXR, its toxic effects on testes tissues, as also observed herein, have been shown previously in an experimental design in male rats [21]. Although the effects of DP and RAM are mainly related with the cardiovascular and circulatory system, therapeutic advantages of these drugs over various organs including testes warrant further investigation in patients under chemotherapy.

The EPO has anti-apoptotic, anti-inflammatory and anti-oxidant effects against the injuries by ischemia-reperfusion (IR) in various tissues [29]. It has been known that the EPO-R, being widespread area of the body, has a regulative role for the survival and proliferation of testes cells [12,14]. The EPO is produced within the layer of germ cells in humans and involved in reproductive function of the testis [10]. Sperm cell is under the influence of EPO through the fertilisation with regard to the EPO-R on sperm membrane before and after the ejaculation [10,30]. Lipid peroxidation (LPO) occurred in cell membrane changes the permeability or

the integrity of the membrane resulting in DNA damage. Mammalian testes are very sensitive to this free radical damage [31,32]. The DXR produces the ROS in tissue that leads to increase in the LPO, oxidative stress and damages to the membrane and DNA. Thus, the DXR triggers the apoptotic pathway of cell death [27]. In the present study, the DXR administration (Group II) markedly increased the MDA levels in rat testicular tissue in comparison with those of other groups. This result was similar to the findings of Çeribaşı et al. [33], indicating the occurrence of LPO in the cellular membranes within the testes [31,32]. Researchers reported that the DP administration reduces the high MDA levels of testes subjected to the IR in rats [14]. Both the DP and DP+RAM treatments prevented the increase in the MDA level caused by the DXR injection herein. Furthermore, in our preliminary studies, the DP treatment increased the haematocrit (HCT) level in rats given DXR (data not shown herein).

Generally, the results of DXR administration in testes are; i) thickening of the basal lamina of seminiferous tubules [33], ii) vacuolisation and/or damages in the Sertoli cells [28,33,34], iii) degeneration of spermatogonia formed around the nuclei by nuclear condensation of spermatogonia with cytoplasmic content characterised by apoptosis [4], iv) prominent germ cell loss [28,35], v) reduction of seminiferous tubule size [35], vi) a mild inhibition of sperm release due to atrophy of the tubulus seminiferus [6,28,33], vii) necrosis, degeneration, desquamation, disorganisation, spermatogonial loss due to direct effect of interstitial oedema and congestion in the germ cells [33], and viii) eventually testicular atrophy allowing Sertoli cells survival only [28]. The findings in testicular tissue revealed that the DXR causes apoptosis due to testicular toxicity as accompanied by the enlargement and severe vacuolisation of interstitial tissue in the interstitial space and a severe vacuolisation and fibrinoid debris in the tubulus seminiferus [4,35].

In the present study, similar changes such as necrosis, degeneration, desquamation, spermatogenic cell loss, interstitial oedema and congestion in the interstitial tissue of testes were observed in a previous report [33].

Reduction of the area in the seminiferous tubules by the DXR was due to the reduction of the area in germinal epithelium. Furthermore, the DXR causes gonadotoxic necrosis resulting in a lower number of germ cells because of the reduction in the germinal epithelial area. The adverse interactions between the MDA level and the above-mentioned measurements explain the damage observed in the male reproductive organs. Also, researchers reported that the use of green tea as an antioxidant prevented some forms of testicular toxicity caused by the DXR in mice [35]. The EPO has marked anti-apoptotic and mitotic functions of various cells including in the endothelial cells, myoblasts, vascular smooth muscle cells, leydig cells, cortical neurons and both renal and non-erythroid cells [36]. In young cryptorchidic rats, the reason of how the EPO treatment before and after the IR protected the testicular morphology and maintained this protective mechanism has not been fully clarified [37,38]. Possible mechanism to explain the testicular damage could be the reduction of nourishments within the tissue caused by vascular changes, and therein, it might have been involved in the ischemia due to Sertoli cell dysfunction [39]. In spontaneously hypertensive rats (SHR), testicular histology reveals the reduction of germ cell, irregular shapes, and decrease in the diameter of the seminiferous tubules, as all due to the lack of expression of tACE in the germinal cells [17]. In stroke-prone spontaneously hypertensive rats (SP-SHR), the changes in different vascular beds and the structural hypertensive alterations within the inter-testicular structures in arterioles led to damages to spermatogenesis resulting in the reduced number of mature and/or immature gamete cells [40]. Not only serious and long-term hypertension but also mild and short-term hypertension may be a risk factor for male reproductive health [17].

Herein, neither the DP nor RAM alone did prevent the reduction in the area of seminiferous tubules and germinal epithelial layer caused by the DXR challenge. Single administration each of them provided only a partial recovery. However, when used together, the combination of DP plus RAM provided more effective protection against the gonadotoxicity by the single use of these drugs. When used alone, the RAM caused a marked reduction in the area of seminiferous tubule lumen as compared to that of the control rats. These results might be related with the effects of RAM on the vascular system. The DXR has been defined as the male reproductive toxicant leading to the reduction of sperm concentration in 4 weeks [28]. Herein, three times administrations of DXR, affecting the whole body up to 4 weeks, decreased the sperm density within the cauda epididymis.

In some researches, the DXR has reduced both the sperm concentration and motility [33,41]. In contrast to the findings of Plassman and Urwyler [28] and Imahie et al. [6], three times administrations decreased the rate of epididymal sperm motility. Any change in the function of ion channels

on the sperm plasma membrane or the mitochondrial milieu may affect the sperm motility [42]. Sperm plasma membrane is quite sensitive in an environment containing excessive amounts of ROS, because the membrane has large amounts of long-chain unsaturated fatty acids and low concentration of scavenging enzymes [43]. In this study, considering the increased MDA levels in the testicular area, it has been considered that the DXR-induced production of free radicals may reduce the motility via an increase in the LPO by the side of the unsaturated fatty acids causing a damage to the tail as a propelling organ of the spermatozoa [33]. Furthermore, the DXR may impair the genes in the DNA responsible for the motility. The reduction in motility rate implies that the DXR has direct effects on the cauda epididymal sperm.

The DXR administration for 8 weeks has caused proportional increases in the head, tail and total abnormal sperm rate [33]. Herein, its administration for 4 weeks increased the dead sperm rate of cauda epididymis as well as the abnormal head ratio and total abnormal sperm rate. This increase in abnormal sperm rate may have occurred as a result of the disruption of epididymal function [44]. The EPO has been detected in human seminal plasma, without any correlation between the EPO levels in seminal plasma and the parameters studied such as sperm density, morphology, cytoplasmic droplets and the number of leukocytes [37]. On the contrary, the sperm cell carries the EPO-R, but its function has not been fully explored yet [30]. However, the EPO molecules to bind EPO-R on the plasma membrane allows a compatible modification that triggers the activation of an event resulting in the protection of cells from the ischemia, apoptosis and ROS [42]. Sperm cells require relatively hypoxic conditions for survival in *in vivo* and *in vitro* milieu. The presence of EPO activity within the epididymis indicates that it supports the sperm cell to remain viable in an hypoxic milieu [42]. Green tea administration improves the sperm motility, whereas melatonin prevents both the reduction of motility and density in the DXR-induced damages [35,41]. On the other hand, the administration of ellagic acid had no protective effect on the motility, concentration and abnormal sperm rate [33].

The enzymes having ACE activity in mammals are widely distributed among different tissues including those in the testis and epididymis where high levels of enzyme activity take place [45]. In stallions, the activity is greater in sperm membrane than in the seminal plasma [16]. All forms of the ACE respond similarly to variable substances, and are equally vulnerable to the specific inhibitors [46]. Captopril, an ACE inhibitor, is an example to reduce the ACE activity in the sperm plasma membrane [16]. However, there has been no effect on the sperm motility in long-term Captopril-treated humans [18]. On the other hand, the influence of ACE on the receptors localised on the sperm neck and tail to bind A-II may affect the sperm

thrusting movement [47], while the underlying mechanism of its effect on the sperm motility remains unclear. Herein, although some beneficial effects were observed with the DP treatment, its usage alone against the DXR-toxicity could not prevent the deterioration in sperm motility, live-dead sperm rate, density and head abnormalities, but it markedly prevented the increase in the total abnormal sperm rate. This fact may suggest the idea that the DP supports the sperm cells via its anti-oxidant properties due to an increase in the HCT level in the region via the removal of DXR-induced free radicals and to the prevention of the damage on the epididymal function [42].

The highest tACE concentration has been reported in spermatozoa with normal morphological features and motility [47]. The RAM, used as an ACE inhibitor herein, provided a partial beneficial contribution without preventing the depression of sperm parameters caused by the DXR. However, the administration of DP plus RAM together prevented depressions of motility, dead sperm and abnormal sperm rate caused by DXR.

In our study, the DXR administration for three times caused a general toxicity reducing the body weight, while the DP plus RAM could not prevent this decline, as indicated earlier [28]. The decrease in the body weight may indicate that the ACE activity has an effect on the body weight, since it has been shown earlier that the SHR animals has low body weights [17]. The reason for the ineffectiveness of the therapy to recover the body weight would be related with the dose and duration of DXR administration. In this respect, one can propose that the recovery from the DXR-induced gonadotoxicity may likely to be accelerated by the therapy after the cessation of DXR given. Therefore, it is important to note that the prevention be more vital than the recovery with regard to the general anthracycline toxicity during the chemotherapy.

The DXR reduces the testis weight as well as all male reproductive organ weights [33,35]. It has been proposed that this weight-decreasing effect is due to the parenchymal atrophy in the seminiferous tubules, the spermatogenic damage within the testicular tissue and the decrease in sperm density [33]. Being as a cytotoxic drug, the DXR inhibits the topoisomerase II activity by influencing the cell DNA resulting in apoptosis at the meiotic division of type A spermatogonia, the intermediate spermatogonia and spermatocytes in the rat testis [4]. Herein, the DP and RAM administrations could not prevent the weight depression of testicles, cauda epididymis, and male accessory glands in the treatment groups (receiving the DXR) because of short-term duration (4 vs. 8 weeks) of exposure of rats to the DP and RAM during the experimental period studied.

In conclusion, single usages of the DP or RAM could not prevent the entire depressive changes, although they achieved partial improvements, in epididymal sperm parameters due to the DXR administration in adult rats.

However, the DP plus RAM treatments provided remarkable protective effects for motility, live-dead sperm rate and total abnormal sperm rate thereby. These favourable effects may involve both the oxygenation of the tissues via an erythropoietin hormone and vascular regulation and cardiovascular compensation with the help of an ACE inhibitor. Therefore, the disruption of male genital organs has been protected from DXR-induced gonadotoxicity by the combination therapy using these drugs. The anti-oxidant effects of the DP and RAM largely prevented the free radical formation, as the actual reason for the increase in the MDA level observed in all the DXR-treated animals. It was considered that these drugs might reduce the damages on Sertoli and germ cells in the testicles and plasma membrane of epididymal sperm.

REFERENCES

- Arcamone F, Cassinelli G, Fantini G, Grein A, Orezzi P, Pol C, Spalla C:** Adriamycin, 14-hydroxydaunomycin, a new antitumor antibiotic from *S. Peucetius* var. *caesius*. *Biotechnol Bioeng*, 11, 1101-1110, 1969. DOI: 10.1002/bit.260110607
- Gewirtz DA:** A critical evaluation of the mechanisms of action proposed for the antitumor effects of the anthracycline antibiotics adriamycin and daunorubicin. *Biochem Pharmacol*, 57, 727-741, 1999. DOI: 10.1016/S0006-2952(98)00307-4
- Swain SM, Whaley FS, Ewer MS:** Congestive heart failure in patients treated with doxorubicin. *Cancer*, 97, 2869-2879, 2003.
- Shinoda K, Mitsumori K, Yasuhara K, Uneyama C, Onodera H, Hirose M, Uehara M:** Doxorubicin induces male germ cell apoptosis in rats. *Arch Toxicol*, 73, 274-281, 1999.
- Howell SJ, Shalet SM:** Spermatogenesis after cancer treatment: Damage and recovery. *J Natl Cancer Inst Monogr*, 12-17, 2005. DOI: 10.1093/jncimonographs/lgi003
- Imahie H, Adachi T, Nakagawa Y, Nagasaki T, Yamamura T, Hori M:** Effects of adriamycin, an anticancer drug showing testicular toxicity, on fertility in male rats. *J Toxicol Sci*, 20, 183-183, 1995. DOI: 10.2131/jts.20.183
- Ozkanlar S, Akcay F:** Antioxidant vitamins in atherosclerosis—animal experiments and clinical studies. *Adv Clin Exp Med*, 21, 115-123, 2012.
- Karapehlivan M, Uzlu E, Atakişi O, Erdoğan HM, Uzun M, Çitil M:** Dokсорubisin uygulanan tavşanlarda plazma sialik asit, malondialdehit ve redükte glutatyon düzeylerine L-karnitinin etkileri. *Kafkas Univ Vet Fak Derg*, 13, 155-160, 2007. DOI: 10.9775/kvfd.2007.29-A
- Yousoufian H, Longmore G, Neumann D, Yoshimura A, Lodish H:** Structure, function, and activation of the erythropoietin receptor. *Blood*, 81, 2223-2236, 1993.
- Kobayashi T, Yanase H, Iwanaga T, Sasaki R, Nagao M:** Epididymis is a novel site of erythropoietin production in mouse reproductive organs. *Biochem Biophys Res Commun*, 296, 145-151, 2002. DOI: 10.1016/S0006-291X(02)00832-X
- Chikuma M, Masuda S, Kobayashi T, Nagao M, Sasaki R:** Tissue-specific regulation of erythropoietin production in the murine kidney, brain, and uterus. *Am J Physiol Endocrinol Metab*, 279, E1242-E1248, 2000.
- Magnanti M, Gandini O, Giuliani L, Gazzaniga P, Marti HH, Gradihone A, Frati L, Aglianò AM, Gassmann M:** Erythropoietin expression in primary rat sertoli and peritubular myoid cells. *Blood*, 98, 2872-2874, 2001. DOI: 10.1182/blood.V98.9.2872
- Lappin T:** The cellular biology of erythropoietin receptors. *Oncologist*, 8, 15-18, 2003. DOI: 10.1634/theoncologist.8-suppl_1-15
- Akcora B, Altug ME, Kontas T, Atik E:** The protective effect of darbepoetin alfa on experimental testicular torsion and detorsion injury. *Int J Urol*, 14, 846-850, 2007. DOI: 10.1111/j.1442-2042.2007.01844.x

- 15. Corvol P, Eyries M, Soubrier F:** Handbook of Proteolytic Enzymes. In, Barret A, Rawlings N, Woessner J (Eds): 332-349, Elsevier Academic Press, New York, 2004.
- 16. Ball B, Gravance C, Wessel M, Sabeur K:** Activity of angiotensin-converting enzyme (ACE) in reproductive tissues of the stallion and effects of angiotensin II on sperm motility. *Theriogenology*, 59, 901-914, 2003. DOI: 10.1016/S0093-691X(02)01127-5
- 17. Atanassova N, Lakova E, Bratchkova Y, Krasteva G, Donchev M:** Expression of testicular angiotensin-converting enzyme in adult spontaneously hypertensive rats. *Folia Histochem Cytobiol*, 47, 117-122, 2009. DOI: 10.2478/v10042-009-0002-6
- 18. Sabeur K, Vo A, Ball B:** Effects of angiotensin II on the acrosome reaction in equine spermatozoa. *J Reprod Fertil*, 120, 135-142, 2000. DOI: 10.1530/jrf.0.1200135
- 19. Inoue N, Kasahara T, Ikawa M, Okabe M:** Identification and disruption of sperm-specific angiotensin converting enzyme-3 (ACE3) in mouse. *PLoS One*, 5, e10301, 2010. DOI: 10.1371/journal.pone.0010301
- 20. Wong P, Uchendu C:** The role of angiotensin-converting enzyme in the rat epididymis. *J Endocrinol*, 125, 457-465, 1990. DOI: 10.1677/joe.0.1250457
- 21. Ozkanlar Y, Aktas MS, Turkeli M, Erturk N, Oruc E, Ozkanlar S, Kirbas A, Erdemci B, Aksakal E:** Effects of ramipril and darbepoetin on electromechanical activity of the heart in doxorubicin-induced cardiotoxicity. *Int J Cardiol*, 173, 519-521, 2014. DOI: 10.1016/j.ijcard.2014.03.044
- 22. Akman O, Aksoy M:** Assessment of sperm quality by hypo-osmotic swelling test (HOST) combined by supravital staining in mice. *J Anim Res*, 18, 1-6, 2008.
- 23. Türk G, Ateşşahin A, Sönmez M, Yüce A, Çeribaşı AO:** Lycopene protects against cyclosporine A-induced testicular toxicity in rats. *Theriogenology*, 67, 778-785, 2007. DOI: 10.1016/j.theriogenology.2006.10.013
- 24. Ohkawa H, Ohishi N, Yagi K:** Assay for lipid peroxides in animal-tissues by thiobarbituric acid reaction. *Anal Biochem*, 95, 351-358, 1979. DOI: 10.1016/0003-2697(79)90738-3
- 25. Quiles JL, Huertas JR, Battino M, Mataix J, Ramírez-Tortosa MC:** Antioxidant nutrients and adriamycin toxicity. *Toxicology*, 180, 79-95, 2002. DOI: 10.1016/S0300-483X(02)00383-9
- 26. Thorn CF, Oshiro C, Marsh S, Hernandez-Boussard T, McLeod H, Klein TE, Altman RB:** Doxorubicin pathways: Pharmacodynamics and adverse effects. *Pharmacogenet Genomics*, 21, 440, 2011. DOI: 10.1097/FPC.0b013e32833ffb56
- 27. Doroshow JH:** Role of hydrogen peroxide and hydroxyl radical formation in the killing of Ehrlich tumor cells by anticancer quinones. *Proc Natl Acad Sci U S A*, 83, 4514-4518, 1986.
- 28. Plassmann S, Urwyler H:** Improved risk assessment by screening sperm parameters. *Toxicol Lett*, 119, 157-171, 2001. DOI: 10.1016/S0378-4274(00)00314-3
- 29. Liu X, Shen J, Jin Y, Duan M, Xu J:** Recombinant human erythropoietin (rhEPO) preconditioning on nuclear factor-kappa B (NF-kB) activation & proinflammatory cytokines induced by myocardial ischaemia-reperfusion. *Indian J Med Res*, 124, 343-354, 2006.
- 30. Tug N, Altunkaynak ME, Aktas RG, Kilic U, Yilmaz B, Cam C, Karateke A:** Does erythropoietin affect motility of spermatozoa? *Arch Gynecol Obstet*, 281, 933-938, 2010. DOI: 10.1007/s00404-009-1289-4
- 31. Turner T, Brown K:** Spermatic cord torsion: loss of spermatogenesis despite return of blood flow. *Biol Reprod*, 49, 401-407, 1993.
- 32. Wilhelm Filho D, Torres MA, Bordin AL, Crezcynski-Pasa TB, Boveris A:** Spermatic cord torsion, reactive oxygen and nitrogen species and ischemia-reperfusion injury. *Mol Aspects Med*, 25, 199-210, 2004. DOI: 10.1016/j.mam.2004.02.020
- 33. Çeribaşı AO, Sakin F, Türk G, Sönmez M, Ateşşahin A:** Impact of ellagic acid on adriamycin-induced testicular histopathological lesions, apoptosis, lipid peroxidation and sperm damages. *Exp Toxicol Pathol*, 64, 717-724, 2012. DOI: 10.1016/j.etp.2011.01.006
- 34. Hou M, Chrysis D, Nurmio M, Parvinen M, Eksborg S, Söder O, Jahnukainen K:** Doxorubicin induces apoptosis in germ line stem cells in the immature rat testis and amifostine cannot protect against this cytotoxicity. *Cancer Res*, 65, 9999-10005, 2005. DOI: 10.1158/0008-5472.CAN-05-2004
- 35. Sato K, Sueoka K, Tanigaki R, Tajima H, Nakabayashi A, Yoshimura Y, Hosoi Y:** Green tea extracts attenuate doxorubicin-induced spermatogenic disorders in conjunction with higher telomerase activity in mice. *J Assist Reprod Genet*, 27, 501-508, 2010. DOI: 10.1007/s10815-010-9438-z
- 36. Avlan D, Erdouğan K, Cimen B, Apa DD, Cinel I, Aksöyek S:** The protective effect of selenium on ipsilateral and contralateral testes in testicular reperfusion injury. *Pediatr Surg Int*, 21, 274-278, 2005.
- 37. Temma K, Shimoya K, Hashimoto K, Zhang Q, Koyama M, Murata Y:** Detection of erythropoietin in human seminal plasma. *Fertil Steril*, 81, 798-801, 2004. DOI: 10.1016/j.fertnstert.2003.07.039
- 38. Ergur BU, Kiray M, Pekcetin C, Bagriyanik HA, Erbil G:** Protective effect of erythropoietin pretreatment in testicular ischemia-reperfusion injury in rats. *J Pediatr Surg*, 43, 722-728, 2008. DOI: 10.1016/j.jpedsurg.2007.11.028
- 39. Akagashi E, Kumamoto Y, Itoh N, Tsukamoto T, Suzuki T, Ohta Y:** Manidipine improves spermatogenesis in the stroke-prone spontaneously hypertensive rat. *J Androl*, 18, 210-216, 1997. DOI: 10.1002/j.1939-4640.1997.tb01902.x
- 40. Akagashi K, Itoh N, Kumamoto Y, Tsukamoto T, Suzuki T, Ohta Y:** Hypertensive changes in intratesticular arteries impair spermatogenesis of the stroke-prone spontaneously hypertensive rat. *J Androl*, 17, 367-374, 1996. DOI: 10.1002/j.1939-4640.1996.tb01802.x
- 41. Lee K, Lee I, Kim S, Moon C, Park S, Shin D, Park S, Kim H, Kim J:** Melatonin attenuates doxorubicin-induced testicular toxicity in rats. *Andrologia*, 44, 796-803, 2012. DOI: 10.1111/j.1439-0272.2011.01269.x
- 42. Tug N, Kilic U, Karateke A, Yilmaz B, Ugur M, Kilic E:** Erythropoietin receptor-like immunostaining on human spermatozoa. *Reprod Biomed Online*, 21, 718-720, 2010. DOI: 10.1016/j.rbmo.2010.05.022
- 43. Aitken R, McLaughlin E:** Molecular mechanisms of sperm capacitation: progesterone-induced secondary calcium oscillations reflect the attainment of a capacitated state. *Soc Reprod Fertil Suppl*, 63, 273-293, 2007.
- 44. Cooper T, Yeung C:** Sperm Maturation in Human Epididymes. In, Christopher JDJ, Barratt CL (Eds): Sperm Cell: Production, Maturation, Fertilization, Regeneration. 72-107, Cambridge University Press, New York, USA, 2006.
- 45. Hohlbrugger G, Schweisfurth H, Dahlheim H:** Angiotensin I converting enzyme in rat testis, epididymis and vas deferens under different conditions. *J Reprod Fertil*, 65, 97-103, 1982. DOI: 10.1530/jrf.0.0650097
- 46. Vanha-Perttula T, Mather J, Bardin C, Moss S, Bellve A:** Localization of the angiotensin-converting enzyme activity in testis and epididymis. *Biol Reprod*, 33, 870-877, 1985. DOI: 10.1095/biolreprod33.4.870
- 47. Aleksinskaya M, Nikolaeva M, Danilov S, Kuz'michyov L, Levchuk T, Yelistratova O, Sukhikh G:** Relationship between spermatozoon movement velocity and expression of testicular isoform of angiotensin-converting enzyme on their surface. *Bull Exp Biol Med*, 141, 236-239, 2006.