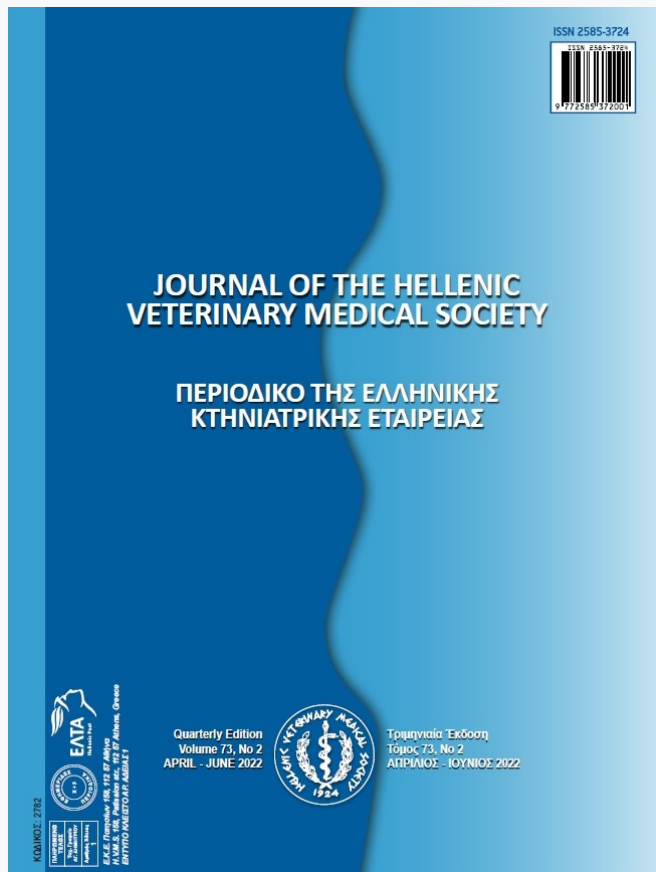

Journal of the Hellenic Veterinary Medical Society

Vol 73, No 2 (2022)



Effect of herbal extract mixture on growth performance and antioxidant parameters in broilers

Mükremin Ölmez, Tarkan Şahin, Özlem Karadağoğlu, Mehmet Akif Yörük, Ebru Karadağ Sari, Şükran Yediel Aras, Metin Öğün, Mustafa Makav

doi: [10.12681/jhvms.26425](https://doi.org/10.12681/jhvms.26425)

Copyright © 2022, Mükremin ÖLMEZ, Tarkan ŞAHİN, Özlem KARADAĞOĞLU, Mehmet Akif YÖRÜK, Ebru KARADAĞ SARI, Şükran YEDIEL ARAS, Metin ÖĞÜN, Mustafa MAKAV



This work is licensed under a [Creative Commons Attribution-NonCommercial 4.0](https://creativecommons.org/licenses/by-nc/4.0/).

To cite this article:

Ölmez, M., Şahin, T., Karadağoğlu, Özlem, Yörük, M. A., Karadağ Sari, E., Yediel Aras, Şükran, Öğün, M., & Makav, M. (2022). Effect of herbal extract mixture on growth performance and antioxidant parameters in broilers. *Journal of the Hellenic Veterinary Medical Society*, 73(2), 4069–4076. <https://doi.org/10.12681/jhvms.26425>

Effect of herbal extract mixture on growth performance and antioxidant parameters in broilers

M. Ölmez^{a*}, T. Şahin^a, Ö. Karadağoğlu^a, M. A. Yörük^b, E. Karadağ Sarı^c,
Ş. Yediel Aras^d, M. Ögün^e, M. Makav^f

^a *Kafkas University, Faculty of Veterinary Medicine Department of Animal Nutrition and Nutritional Diseases, Kars, Turkey*

^b *Atatürk University, Faculty of Veterinary Medicine, Department of Animal Nutrition and Nutritional Diseases, Erzurum, Turkey*

^c *Kafkas University, Faculty of Veterinary Medicine, Department of Histology and Embryology, Kars, Turkey*

^d *Kafkas University, Faculty of Health Sciences, Department of Midwifery, Kars, Turkey*

^e *Kafkas University, Faculty of Medicine, Department of Biochemistry, Kars, Turkey*

^f *Kafkas University, Faculty of Veterinary Medicine, Department of Physiology, Kars, Turkey*

ABSTRACT: This study was conducted to determine the effects on the growth performance and antioxidant capacity of broiler chickens, which were fed an herbal extract mixture (HEM), including Honokiol-Magnolol and Sanguinarine as natural feed additives in broiler diets. A total of 300 one-day-old male Ross 308 broilers were used in this study and randomly divided into four groups with five replicates of 15 broiler chicks each. For the experimental groups, herbal extract mixture was supplemented in their diet at the levels of 0.00% (C), 1.00% (HEM1), 1.50% (HEM2) and 2.00% (HEM3), respectively. At the end of the experiment, it was concluded that HEM influenced final body weight (FBW), body weight gain (BWG), feed Consumption (FC), feed conversion ratio (FCR), slaughter weight, carcass weight and carcass yield ($P<0.05$). Also, HEM decreased malondialdehyde level ($P<0.05$) and increased glutathione of the breast and liver tissues ($P<0.05$). Herbal extract mixture showed strong cytoplasmic manganese superoxide dismutase immunoreactivity in duodenal crypts. It is concluded that HEM supplementation to broiler diets may improve the growth performance and antioxidant activity. Thus, HEM may use natural feed additives to improve broiler health and performance.

Keywords: Antioxidant; broiler; honokiol-magnolol; performance; sanguinarine

Corresponding Author:

M. Ölmez, Department of Animal Nutrition and Nutritional Diseases, Faculty of Veterinary Medicine, Kafkas University, Kars, 36100, Turkey
E-mail address: mukremin.olmez@hotmail.com

Date of initial submission: 18-03-2021
Date of acceptance: 11-07-2021

INTRODUCTION

Antibiotics have been used for many years to support growth in the production of poultry meat, which constitutes an essential part of animal food sources. As a result of antibiotic residue in tissues, consuming these products may have many pathological effects, such as carcinogenic, mutagenic, pharmacological, immunopathological, microbiological and toxicological in humans (İrkin et al., 2019). Hence, it is necessary to determine the methods to get rid of the negative effects of antibiotics in poultry. Medicinal and aromatic herbs or their derivatives are among the types of non-antibiotic feed additives that can help maintain health and improve the growth performance of poultry (Cimrin et al., 2020; Karadağoğlu et al., 2020; Ölmez et al., 2021). Highly-concentrated diets have increased poultry meat production and enabled the animals to reach slaughter weight (SW) in a short time. However, they have negatively affected the metabolism by releasing various compounds into the bloodstream and affecting the organism's redox homeostasis. Antioxidants have eliminated harmful free radicals when they were above the normal levels to prevent oxidative stress in living organisms (Celi, 2010). Aromatic plants and their active substances are known as phytobiotics. Recent studies on animal nutrition have been identified by an increasing interest in the potential effect of phytobiotics on the growth performance and antioxidant status of poultry. Therefore phytobiotics are used as natural feed additives (Hussein et al., 2020; Yeşilbağ et al., 2020). Research plans have been developed, however, studies have not been consistent on the perception of the specific style of action and the functional aspects of phytobiotics (Faix et al., 2009; Barbarestani et al., 2020). Various studies have shown that phytogetic feed additives affect on performance and stimulate digestion (Akbari et al., 2020; Khoobani et al., 2020).

Honokiol - Magnololis the two major compounds found in the *Magnolia officinalis*. Sanguinarine (which is a quarternary benzo [c] phenanthridine alkaloid component), found in the seeds, stems and leaves of the *Macleaya cordata*. Many studies showed that Honokiol - Magnolol and Sanguinarine have antioxidant effects as free radicals and lipid peroxidation inhibitors (Ni et al., 2016; Park et al., 2020). Additionally, these major compounds have antibacterial and antifungal effects besides having an antioxidant activity (Niu et al., 2012; Wei et al., 2015). It has been reported that Honokiol - Magnolol and/or Sanguinarine can alter gut microbiota and nutrient digestibility due

to antioxidant activity (Vieira et al., 2008a; Goodarzi Boroojeni et al., 2018).

The aim of this study is to evaluate the effects of the supplementation of commercial natural herbal extract mixture (HEM) containing active ingredients of Honokiol - Magnolol and Sanguinarine on growth performance and antioxidant parameters in broilers.

MATERIAL AND METHODS

Ethical approval

The Animal Experiments Local Ethics Committee of Kafkas University approved this research (Approval no: KAÜ - HADYEK / 2019 - 160).

Animals and experimental design

A total of 300 male one-day-old Ross 308 chicks were supplied for this study from a special hatchery farm and fed in the broiler unit at Kafkas University Research Farm. After a one week adaptation period, the chicks were distributed to four main groups (with 75 chicks in each group), with no significant differences between mean body weight (161.57 ± 0.06 g). Each group was divided into five subgroups (15 chicks/cages). The chicks were housed in cages with a size of 140×200 cm. The temperature of the broiler unit was kept at 32 °C during the first three days. It was reduced 1 °C every two days, fixed at 24 °C and this temperature was maintained throughout the study. Water and feed were available to the animals *ad-libitum*. Trial lasted 42 days, including seven days of adaptation and 35 experimental periods. The chicks were fed with diets (grower and finisher) that were provided according to the requirements for broilers (NRC, 1994). Also, the chicks were fed a grower diet (23.5% CP and 3020 kcal/kg Metabolic Energy, ME) during the adaptation period. Metabolizable energy (ME) values of the diets are calculated according to TSE (1991). The composition of the diets is indicated in Table 1.

Herbal extract mixture (HEM) was added at the levels of 0.00% (C), 1.00% (HEM1), 1.50% (HEM2) and 2.00% (HEM3), respectively. The level of HEM was determined as per the manufacturer's instructions. Commercial natural HEM was provided from a manufacturer (Filopower®, Yem-Vit AŞ İzmir, Turkey). Herbal extract mixture (HEM) was a mix of 24.00% blend of plant flavoring compounds (magnolia and macleaya), 23.50% calcium carbonate, 50.00% wheat

Table 1. Composition of experimental diets

Ingredients, (%)	Grower (d 7 - 21)	Finisher (d 22 - 42)
Corn, yellow	50.85	52.78
Soybean meal, 48% CP	31.35	18.26
Rice bran	-	5.00
Wheat	5.00	5.00
Bran	5.00	4.00
CDDGS (Corn dried distillers' grains with solubles), 30% CP	-	4.00
Corn protein, 62% CP	2.00	4.00
Sunflower oil	1.01	2.82
Meat and bone meal, 50% CP	2.40	2.32
Dicalcium phosphate	1.05	0.52
Salt	0.25	0.15
Threonine	0.18	0.11
L-lysine	0.45	0.45
DL-methionine	0.10	0.28
Vitamin- Mineral premix*	0.25	0.20
Sodium bicarbonate	0.11	0.11
Chemical Analysis		
Crude protein (%)	23.54	19.80
Metabolic energy (kcal / kg ME)	3020.80	3190.60
Lysine (%)	1.29	1.10
Methionine + cystine (%)	0.90	0.87
Calcium (%)	1.00	0.90
Available phosphorus (%)	0.50	0.45

*: Vitamin-mineral premix per kg of diet. Vitamins: Vit A 10000 IU Vit D3: 4000IU Minerals: Fe (iron sulfate monohydrate): 30 mg, Se (selenium selenite); 0.3 mg, I (calcium iodine anhydride): 2 mg, Cu (copper sulfate pentahydrate); 5 mg, Mn (manganese oxide); 80 mg, Co (cobalt carbonate monohydrate); 0.5 mg, Zn (zinc oxide); 80 mg.

middlings, 2.00% by-products of tuber and root feeds, and 0.50% barley meal (amounts given by the producer).

Performance

Average body weight (BW) and feed consumption (FC) in subgroups were determined weekly. This was used to calculate the feed conversion ratio (FCR). At 42 days of age, eight broilers were randomly selected from each group (five replicates), weighed and slaughtered by cervical dislocation. The viscera from the slaughtered broilers were removed. Cold carcass weights were recorded after the carcasses were stored for 24 hours at + 4 °C. The cold carcass yields were calculated by dividing carcass weight by body weight.

Antioxidant parameters sampling and procedure

Biochemical procedure

Breasts and livers were harvested, and the tissues were rinsed with 0.9% NaCl. Tissues were homogenized in a phosphate (pH 7.4) buffer in 0.1 M KCl,

and the homogenates were subsequently centrifuged at 1500 rpm for 5 min. The supernatants obtained from the breast meat and liver were stored at - 20 °C for later measurement of glutathione (GSH) and malondialdehyde (MDA) contents. Analyses of GSH and MDA concentrations were carried out by the methods defined by Beutler (1963) and Yoshioka et al. (1979) respectively.

Immunohistochemical Procedure

Duodenum tissue samples taken from the broilers were fixed in a 10% formalin solution, and the routine histological procedure was followed by embedding the tissue samples in paraffin. Serial tissue sections with five µm thickness were cut from the paraffin blocks, and Mallory's modified triple staining method (Triple) was applied to the sections (Munro, 1971). The sections were taken from paraffin blocks on chrome alum gelatin-coated slides for immunohistochemical examinations. The slides were obtained from paraffin blocks incubated in 3% H₂O₂ (hydrogen peroxide) prepared in 0.1 M phosphate-buffered

saline (PBS) for 15 min in order to inhibit endogenous peroxidase activity after deparaffinization and rehydration procedures. Then, slides for releasing the antigenic receptors were boiled with microwaves at 600 watts for 10 minutes in a Citrate Buffer solution (pH: 6.0). The Avidyne-Biotin-Peroxidase protocol was used on the slides (Hsu et al., 1981). Slides were incubated with Large Volume Ultra V Block (Thermo Scientific / Waltham, MA, USA) for 10 minutes and then manganese-dependent superoxide dismutase (Mn-SOD) (B-1) (Santa Cruz Sc133254) (1 / 500 dilution) primary antibody diluted with PBS was applied. Slides were incubated at + 4 °C for 24 hours. Then Biotinylated Goat Anti (B) Polyvalent (Thermo Scientific / Waltham, MA USA) and Streptavidin Peroxidase (Thermo Scientific / Waltham, MA USA) were applied for 30 minutes. DAB - H₂O₂ (Diaminobenzidinehydrogenperoxide) was applied to the PBS washed slides as an colouring substrate (Shu et al., 1988). After adding a chromogen solution on the slides, the reaction was terminated with PBS depending on the status of immunoreactivity by controlling under the light microscope. Hematoxylin was applied on the slides for counterstaining after washing with distilled water. Slides were then dehydrated and covered with immunmount. The staining level was accepted as a criterion and scoring was performed with

a semiquantitative method. The ratio of the Mn-SOD immunoreactive cells were categorized as (+) weak, (++) moderate, (+++) or strong-immunolabeling. Slides prepared for histological and immunohistochemical investigations were examined and photographed with a light microscope (Olympus BX51, Japan).

Statistical analysis

The data was analyzed using a one-way analysis of variance (ANOVA) in statistical software (IBM SPSS portable 18). The post-hoc test (Duncan's multiple range test) measured the significance of the means. A statistical significance was present at P < 0.05 and P < 0.01.

RESULTS

HEM significantly affected the performance as FBW and BWG. The 2% added HEM group had the highest FBW and average BWG (P<0.01). Also, treatments of HEM influenced the FC and FCR (P<0.01) (Table 2).

The treatments of HEM affected slaughter weight (SW) (P<0.01), cold carcass weight (P<0.01) and carcass yield (P<0.01). The highest SW (3114.38 g) and carcass weight (2307.00 g) were found in the 2%

Table 2. The effect of HEM on performance parameters

Parameters	Groups*				P
	Control	HEM1	HEM2	HEM3	
IW [†] (g)	161.46±2.59	161.75±3.30	161.54±2.29	161.54±2.11	0.997
FBW [‡] (g)	2925.75±36.29 ^b	2985.79±18.76 ^{ab}	3052.50±24.98 ^{ab}	3118.79±17.95 ^a	0.001
BWG [§] (g)	2764.29±36.55 ^c	2824.04±18.73 ^{bc}	2890.96±24.64 ^{ab}	2957.25±17.21 ^a	0.001
FC (g)	5279.79±64.57 ^a	5252.71±52.55 ^a	5082.08±71.59 ^b	5086.47±88.68 ^b	0.001
FCR [£] (g/g)	1.91±0.03 ^a	1.86±0.02 ^a	1.76±0.04 ^b	1.72±0.03 ^b	0.001

*HEM1:1.00% Herbal extract mix, HEM2: 1.50% Herbal extract mix, HEM3: 2.00% Herbal extract mix.

[†]IW: Initial weight

[‡]FBW:Final body weight

[§]BWG: Body weight gain

^{||}FC: Feed consumption

[£]FCR: Feed conversion ratio

^{a-c} Mean ± SEM amounts in the same column with different superscripts differ significantly (P<0.05).

Table 3. The effect of HEM on carcass parameters

Parameters	Groups*				P
	Control	HEM1	HEM2	HEM3	
Slaughter weight (g)	2925.13±11.14 ^c	2983.25±29.95 ^{bc}	3033.13±33.17 ^b	3114.38±28.12 ^a	0.001
Cold carcass weight (g)	2136.50±9.80 ^c	2203.00±18.33 ^b	2242.75±24.26 ^b	2307.00±22.70 ^a	0.001
Carcass yield (%)	73.04±0.13 ^b	73.87±0.52 ^a	73.94±0.14 ^a	74.07±0.11 ^a	0.018

*HEM1:1.00% Herbal extract mix, HEM2: 1.50% Herbal extract mix, HEM3: 2.00% Herbal extract mix.

^{a-c}: Mean ± SEM amounts in the same column with different superscripts differ significantly (P<0.05).

Table 4. The effect of HEMon antioxidant parameters (nmol / g)

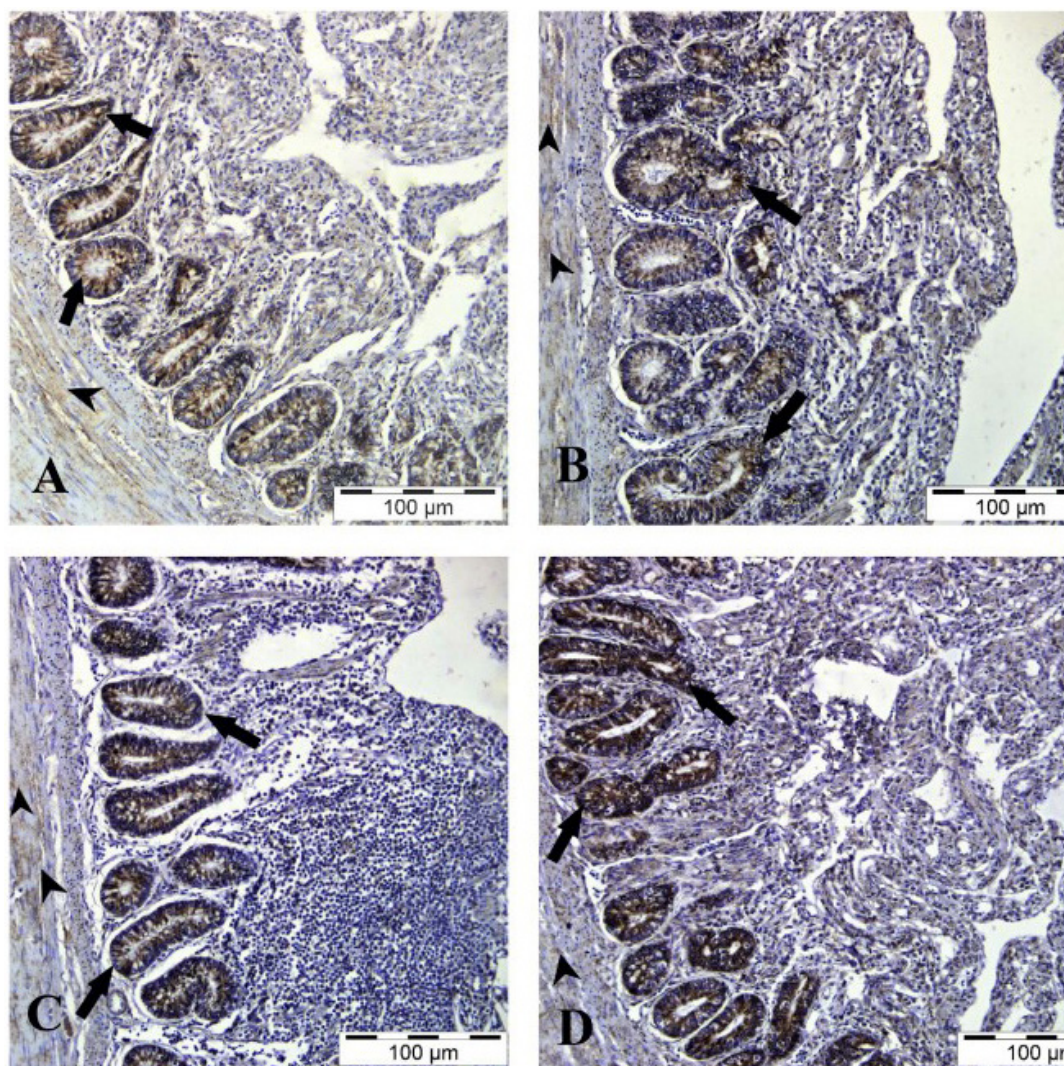
Parameters		Groups*				P
		Control	HEM1	HEM2	HEM3	
Breast	GSH [†]	3.96±0.13 ^c	5.05±0.18 ^a	5.15±0.22 ^a	4.48±0.04 ^b	0.001
	MDA [‡]	4.55±0.23 ^a	3.88±0.14 ^b	4.78±0.17 ^a	3.86±0.17 ^b	0.003
Liver	GSH [†]	4.32±0.03 ^c	5.89±0.15 ^a	4.74±0.11 ^b	5.71±0.09 ^a	0.001
	MDA [‡]	3.35±0.26 ^a	2.45±0.13 ^b	3.19±0.31 ^a	2.66±0.12 ^{ab}	0.039

*HEM1: 1.00% Herbal extract mix, HEM2: 1.50% Herbal extract mix, HEM3: 2.00% Herbal extract mix.

[†]GSH=Glutathione

[‡]MDA= Malondialdehyde

^{a-c} Mean ± SEM amounts in the same column with different superscripts differ significantly (P<0.05).

**Figure 1.** Broiler duodenum tissues

A: Control, B: HEM1, C: HEM2, D: HEM3. Arrowhead: Tunica muscularis, arrow: intestinal crypt. Mn-SOD immunoreactivity. HEM1: 1.00% Herbal extract mix, HEM2: 1.50% Herbal extract mix, HEM3: 2.00% Herbal extract mix.

added HEM group. Additionally, adding increasing-HEM levels to the rations positively affected the carcass yield in the experimental groups compared to the control group (Table 3).

The levels of antioxidant parameters (GSH and MDA) of breast and liver tissues were significantly affected in HEM supplemented groups compared with the control group (P<0.05) (Table 4).

Table 5. The effect of HEM on Mn-SOD immunoreactivity in duodenal tissues

Parameters	Groups*			
	Control	HEM1	HEM2	HEM3
Intestinal Crypts	++	+++	+++	+++
Tunica Muscularis	+	+	+	+

*HEM1: 1.00% Herbal extract mix, HEM2: 1.50% Herbal extract mix, HEM3: 2.00% Herbal extract mix.
Weak staining (+); moderate staining (++); strong staining (+++)

Mn-SOD immunoreactivity was determined in the duodenum tissues of the broiler chickens in all groups. However, the density of the immunoreactivity differed between the control and treatment groups (Table 5). In the control group, moderate cytoplasmic Mn-SOD immunoreactivity in intestinal crypts and weak cytoplasmic in the tunica muscularis layer was detected. Owing to supplemented HEM in the broiler diets, strong cytoplasmic Mn-SOD immunoreactivity in intestinal crypts and weak Mn-SOD immunoreactivity in the tunica muscularis layer were observed (Figure 1).

DISCUSSION

The study was conducted to evaluate the effect of HEM as a natural feed additive on performance, antioxidant parameters and duodenal Mn-SOD immunoreactivity in the broiler chickens. Increasing levels of HEM significantly affected the performance as FBW and BWG. The highest FBW and overall BWG were observed in the HEM3 group. Supplementation of HEM decreased the FC and increased the FCR. Also, HEM increased carcass weight and carcass yield. There was evidence that the HEM improved growth performance by showing antioxidant effects (Lee et al., 2014; Lin et al., 2017). This study confirmed several previous studies that reported that dietary phytobiotics could increase the performance of poultry because of the antioxidant activity (Hashemi and Davoodi, 2011; Fonseca-García et al., 2017; Lin et al., 2017; Abu Hafsa and Ibrahim, 2018). In contrast, some researchers reported that Honokiol-Magnolol and Sanguinarine, which were used combined or alone, did not affect performance (Karimi et al., 2014; Yeşilbağ et al., 2020). It was suggested that the supplemented Sanguinarine significantly increased digestibility compared to the control group by increasing the enzymatic activity (Franz Vienna et al., 2005; Yeşilbağ et al., 2020). Also, Vieira et al. (2008b) reported that active components of natural feed additive supported growth performance by increasing amino acid utilization. This result may explain the improvement in BW and FCR in HEM supplemented groups

despite the decrease in FC. Hassan et al. (2018) found that carcass weight and dressing percentage of broilers fed antibiotic or feed additives supplemented diets increased significantly compared to those fed the control diet. Increasing digestibility might cause higher carcass weight and yield. However Zdunczyk et al. (2010) showed that protein utilization was ineffective and did not support performance. Also, it was reported that HEM did not affect on the carcass weight, and carcass yield (Yeşilbağ et al., 2020).

In the present study, the biochemistry of GSH and MDA in the breast meat and liver tissues of broiler chickens was evaluated to determine the antioxidant activity of HEM. Further, Mn-SOD, which is the localized mitochondrial form of superoxide dismutase, was examined histologically in broiler duodenal tissue. Breast and liver antioxidant parameter (GSH and MDA) levels were influenced by supplementation of HEM compared to the control group. Additionally, the density of the immunoreactivity differed between the control and the HEM groups. In the control group, moderate cytoplasmic Mn-SOD immunoreactivity in intestinal crypts and weak cytoplasmic Mn-SOD immunoreactivity in the tunica muscularis layer was detected. Strong cytoplasmic Mn-SOD immunoreactivity in intestinal crypts due to the supplementation of HEM to broiler diets was observed. Free radicals produce reactive oxygen types in tissues, causing damage to cells and tissues. Antioxidants are involved in protecting cell homeostasis by eliminating the damage caused by protein and lipid peroxidation. GSH and SOD protect cells against oxidative stress by eliminating undesirable free radicals in the organism such as O_2^- , ROOH, hydrogen peroxide (H_2O_2). MDA, which is a parameter that is frequently evaluated in determining peroxidation, is the last product of lipid peroxidation (Nita et al., 2001; Ermak and Davies, 2002). In the current study, breast and liver GSH levels increased while the MDA level decreased in HEM1 and HEM2 groups ($P < 0.05$). Similarly, Oh et al. (2018) reported magnolia has higher antioxidant activity in broilers and Lee et al. (2014) also found

that the level of MDA in sanguinarine was lowered. This data shows that phenolic compounds have a protective effect on meat tissue and form a meat structure including less oxidative fatty acid (Juskiewicz et al., 2011). On the other hand, it was reported that the supplementation of sanguinarine in laying hens lowers serum MDA level (Bavarsadi et al., 2017; Liu et al., 2020) and increases the antioxidant activity of the honokiol-magnolol compound in mice (Pang et al., 2013). Likewise, it has been determined that phyto-genic additives increase antioxidant activity in many studies (Barbarestani et al., 2020; Skomorucha et al., 2020).

In the previous studies, it has been determined that various phyto-genics affect increasing SOD activity in tissues (Mahmoud et al., 2013; Qwele et al., 2013). It has been reported that phenolic compounds could boost antioxidant activity by increasing the expression of the SOD gene in broilers (Puvača et al., 2018). In another study, phytobiotics in broiler chickens increased the level of Mn-SOD in the jejunum, but did not influence this level in the liver (Barbarestani et al., 2020). Phyto-genic products can affect the antioxidant enzyme, such as SOD, which in turn decreases

the reactive oxygen types known as inflammatory agents on tissues, provoking atrophy and epithelial barrier disorder of the intestine (Moretti et al., 2018). In this way, the SOD activity of HEM in the duodenum might manage to develop the intestinal health of broiler chickens. All studies showed that natural feed additives increase growth performance and nutrients digestion due to the active ingredients of natural feed additives.

CONCLUSION

The present results demonstrate that the HEM may improve growth performance. Also, HEM can improve the antioxidant activity in breast, liver and duodenum of broilers. These parameters showed that HEM has potential to be a natural antioxidant product for performance improvement and disease prevention. In particular, up to 2% HEM may be used in broiler diets without a negative effect on growth performance, carcass yield and antioxidant status. Besides, future research on the antioxidant activity of HEM will enrich result explication.

CONFLICT OF INTEREST

None declared.

REFERENCES

- Abu Hafsa S, Ibrahim S (2018) Effect of dietary polyphenol-rich grape seed on growth performance, antioxidant capacity and ileal microflora in broiler chicks. *J Anim Physiol Anim Nutr (Berl)* 102:268-275.
- Akbari M, Ashrafi S, Bouyeh M, Jáber Mohamad JR, Seidavi A, Rodríguez Ventura M (2020) Evaluation of chamomile (*Matricaria chamomilla* L.) as an alternative growth promoter in broiler chicks. *Anim Nutr Feed Technol* 20:71-81.
- Barbarestani SY, Jazi V, Mohebodini H, Ashayerizadeh A, Shabani A, Toghyani M (2020) Effects of dietary lavender essential oil on growth performance, intestinal function, and antioxidant status of broiler chickens. *Livest Sci* 233:103958-103965.
- Bavarsadi M, Mahdavi A, Ansari-Mahyari S, Jahanian E (2017) Effects of different levels of sanguinarine on antioxidant indices, immunological responses, ileal microbial counts and jejunal morphology of laying hens fed diets with different levels of crude protein. *J Anim Physiol Anim Nutr* 101:936-948.
- Beutler E (1963) Improved method for the determination of blood glutathione. *J Lab Clin Med* 61:882-888.
- Celi P (2010) The role of oxidative stress in small ruminants' health and production. *R Bras Zootec* 39:348-363.
- Cimirin T, Tunca RI, Avsaroglu MD, Ayasan T, Küçükersan S (2020) Effects of an antibiotic and two phyto-genic substances (cinnamaldehyde and 1, 8-cineole) on yolk fatty acid profile and storage period-associated egg lipid peroxidation level. *R Bras Zootec* 49:e20190270.
- Ermak G, Davies KJA (2002) Calcium and oxidative stress: from cell signaling to cell death. *Mol Immunol* 38:713-721.
- Faix Š, Faixová Z, Plachá I, Koppel J (2009) Effect of Cinnamomum zeylanicum essential oil on antioxidative status in broiler chickens. *Acta Vet Brno* 78:411-417.
- Fonseca-García I, Escalera-Valente F, Martínez-González S, Carmo-na-Gasca CA, Gutiérrez-Arenas DA, Ávila-Ramos F (2017) Effect of oregano oil dietary supplementation on production parameters, height of intestinal villi and the antioxidant capacity in the breast of broiler. *Austral J Vet Sci* 49:83-89.
- Franz Vienna C, Bauer Graz R, Carle Hohenheim R, Tedesco Milano D, Tubaro Trieste A, Zitterl Eglseer Wien K (2005) Study on the assessment of plant/herb extracts and their naturally or synthetically produced components as "additives" for use in animal production. *EFSA Support Publ* 4:140-154.
- Goodarzi Borojjeni F, Männer K, Zentek J (2018) The impacts of Macleaya cordata extract and naringin inclusion in post-weaning piglet diets on performance, nutrient digestibility and intestinal histomorphology. *Arch Anim Nutr* 72:178-189.
- Hashemi SR, Davoodi H (2011) Herbal plants and their derivatives as growth and health promoters in animal nutrition. *Vet Res Commun* 35:169-180.
- Hassan H, Samy A, Youssef A, Mohamed M (2018) Using different feed additives as alternative to antibiotic growth promoter to improve growth performance and carcass traits of broilers. *Int J Poult Sci* 17:255-261.
- Hsu SM, Raine L, Fanger H (1981) Use of avidin-biotin-peroxidase complex (ABC) in immunoperoxidase techniques: a comparison between ABC and unlabeled antibody (PAP) procedures. *J Histochem Cytochem* 29:577-580.
- Hussein EO, Ahmed SH, Abudabos AM, Suliman GM, El-Hack A, Mohamed E, Swelum AA, N Alowaimer A (2020) Ameliorative effects of antibiotic-, probiotic- and phytobiotic-supplemented diets on the performance, intestinal health, carcass traits, and meat quality of Clostridium perfringens-infected broilers. *Animals* 10:669-683.
- İrkin R, Batu Z, Özbek K Hayvansal besinlerdeki antibiyotik kalıntılarının insan sağlığına etkileri. Pages 442-448, İzmir: pp 442-448.
- Juskiewicz J, Gruzauskas R, Zdunczyk Z, Semaskaite A, Jankowski J,

- Totilas Z, Jarule V, Sasyte V, Zdunczyk P, Raceviciute-Stupeliene A, Svirnickas G (2011) Effects of dietary addition of *Macleaya cordata* alkaloid extract on growth performance, caecal indices and breast meat fatty acids profile in male broilers. *J Anim Physiol Anim Nutr* 95:171-178.
- Karadağoğlu Ö, Şahin T, Ölmez M, Yakan A, Özsoy B (2020) Changes in serum biochemical and lipid profile, and fatty acid composition of breast meat of broiler chickens fed supplemental grape seed extract. *Turkish J Vet Anim Sci* 44:182-190.
- Karimi M, Forouzi F, Abedini M (2014) Effect of Sangrovit on performance and morphology of small intestine and immune response of broilers. *Biosci Biotechnol Res Asia* 11:855-861.
- Khoobani M, Hasheminezhad S-H, Javandel F, Nosrati M, Seidavi A, Kadim IT, Laudadio V, Tufarelli V (2020) Effects of dietary chicory (*chicorium intybus* L.) and probiotic blend as natural feed additives on performance traits, blood biochemistry, and gut microbiota of broiler chickens. *Antibiotics* 9:5-13.
- Lee KW, Kim JS, Oh ST, Kang CW, An BK (2014) Effects of dietary sanguinarine on growth performance, relative organ weight, cecal microflora, serum cholesterol level and meat quality in broiler chickens. *J Poultry Sci* 52:15-22.
- Lin Q, Zhao J, Xie K, Wang Y, Hu G, Jiang G, Dai Q, Fan Z, He J, He X, Hou D-X (2017) Magnolol additive as a replacer of antibiotic enhances the growth performance of Linwu ducks. *Anim Nutr* 3:132-138.
- Liu ZY, Wang XL, Ou SQ, Hou DX, He JH (2020) Sanguinarine modulate gut microbiome and intestinal morphology to enhance growth performance in broilers. *PLoS one* 15:e0234920.
- Mahmoud R, Ibrahim D, Badawi M (2013) Effect of supplementation of broiler diets with guava leaves and/or olive oil on growth, meat composition, blood metabolites and immune response. *Benha Vet Med J* 25:23-32.
- Moretti S, Mrakic-Sposta S, Roncoroni L, Vezzoli A, Dellanoce C, Monguzzi E, Branchi F, Ferretti F, Lombardo V, Doneda L (2018) Oxidative stress as a biomarker for monitoring treated celiac disease. *Clin Transl Gastroenterol* 9:157-165.
- Munro B (1971) Manual of histologic staining methods of the Armed Forces Institute of Pathology. 3 edn. Blakiston Division, McGraw-Hill
- Ni H, Martínez Y, Guan G, Rodríguez R, Más D, Peng H, Valdiviá Navarro M, Liu G (2016) Analysis of the impact of isoquinoline alkaloids, derived from *Macleaya cordata* extract, on the development and innate immune response in swine and poultry. *Biomed Res Int* 2016:1-7.
- Nita DA, Nita V, Spulber S, Moldovan M, Popa DP, Zagrean AM, Zagrean L (2001) Oxidative damage following cerebral ischemia depends on reperfusion—a biochemical study in rat. *J Cell Mol Med* 5:163-170.
- Niu X, Fan T, Li W, Xing W, Huang H (2012) The anti-inflammatory effects of sanguinarine and its modulation of inflammatory mediators from peritoneal macrophages. *Eur J Pharmacol* 689:262-269.
- NRC (1994) Nutrient requirements of poultry. National Academies Press Washington, DC
- Oh S, Gadde UD, Bravo D, Lillehoj EP, Lillehoj HS (2018) Growth-promoting and antioxidant effects of magnolia bark extract in chickens uninfected or co-infected with *Clostridium perfringens* and *Eimeria maxima* as an experimental model of necrotic enteritis. *Curr Dev Nutr* 2:nzy009.
- Ölmez M, Adıgüzel Işık S, Şahin T, Yörük MA (2021) The effects of Pennyroyal (*Mentha pulegium* L.) on performance, carcass and meat quality in Japanese quails (*Coturnix coturnix japonica*). *Ankara Üniv Vet Fak Derg* (In press)
- Pang Y, Han X, Bamikole M, Gong Z, Tang S, Tan Z, Xiao W, Zhou C, Wang M, Deng Y (2013) Anti-diarrhoea and anti-oxidant properties of magnolol. *Trop J Pharm Res* 12:85-91.
- Park I, Oh S, Lillehoj EP, Lillehoj HS (2020) Dietary supplementation with magnolia bark extract alters chicken intestinal metabolite levels. *Front Vet Sci* 7:157-165.
- Puvača N, Ljubović D, Čabarkapa I, Đuragić O, Popović S, Prodanović R, Bošković J (2018) Effects of turmeric powder (*Curcuma Longa*) in broiler nutrition: Coccidiosis and antioxidative status. *Con Dairy Vet Sci* 2:159-160.
- Qwele K, Muchenje V, Oyedemi S, Moyo B, Masika P (2013) Effect of dietary mixtures of moringa (*Moringa oleifera*) leaves, broiler finisher and crushed maize on anti-oxidative potential and physico-chemical characteristics of breast meat from broilers. *Afric J Biotechnol* 12:290-298.
- Shu S, Ju G, Fan L (1988) The glucose oxidase-DAB-nickel method in peroxidase histochemistry of the nervous system. *Neurosci Lett* 85:169-171.
- Skomorucha I, Sosnowka-Czajka E, Muchacka R (2020) Effects of supplementing drinking water with mixed herb extract or outdoor access on meat quality characteristics in broiler chickens. *Ann Anim Sci* 20:647-660.
- TSE (1991) Hayvan yemleri-metabolik (çevrilebilir) enerji tayini (kimyasal metot): TSE.
- Vieira SL, Berres J, Reis R, Oyarzabal OA, Coneglian JLB, Freitas DMd, Pena J, Torres CA (2008a) Studies with sanguinarine like alkaloids as feed additive in broiler diets. *Braz J Poultry Sci* 10:67-71.
- Vieira SL, Oyarzabal OA, Freitas DM, Berres J, Peña JEM, Torres CA, Coneglian JLB (2008b) Performance of broilers fed diets supplemented with sanguinarine-like alkaloids and organic acids. *J Appl Poultry Res* 17:128-133.
- Wei W, Dejie L, Xiaojing S, Tiancheng W, Yongguo C, Zhengtao Y, Naisheng Z (2015) Magnolol inhibits the inflammatory response in mouse mammary epithelial cells and a mouse mastitis model. *Inflammation* 38:16-26.
- Yeşilbağ D, Çetin I, Balcı F, Ardıçlı S, Özyiğit M, Cengiz Ş (2020) Effects of dietary supplementation of two commercial plant extracts on the growth performance and ileal inflammation score in broiler chickens. *Acta Vet Eurasia* 46:68-74.
- Yoshioka T, Kawada K, Shimada T, Mori M (1979) Lipid peroxidation in maternal and cord blood and protective mechanism against activated-oxygen toxicity in the blood. *Am J Obstet Gynecol* 135:372-376.
- Zdunczyk Z, Gruzauskas R, Juskiwicz J, Semaskaite A, Jankowski J, Godycka-Klos I, Jarule V, Mieželiene A, Alencikiene G (2010) Growth performance, gastrointestinal tract responses, and meat characteristics of broiler chickens fed a diet containing the natural alkaloid sanguinarine from *Macleaya cordata*. *J Appl Poultry Res* 19:393-400.