

Effects of Thymoquinone Supplementation on Somatostatin Secretion in Pancreas Tissue of Rats ^{[1][2]}

Buket BAKIR ¹  Ebru KARADAG SARI ² Sevda ELIS YILDIZ ³ Hasan ASKER ²

^[1] This study was presented as oral presentation in 3rd International Vetİstanbul Group Congress 2016 in Sarajevo, Bosnia and Herzegovina on 17-20 May, 2016

^[2] This study was supported by Namik Kemal University Commission for the Scientific Research (NKUBAP) (Project No. NKUBAP.00. M9. AR. 14. 02)

¹ Department of Histology and Embryology, Faculty of Veterinary Medicine, Namik Kemal University, TR-59030 Tekirdag - TURKEY

² Department of Histology and Embryology, Faculty of Veterinary Medicine, Kafkas University, TR-36040 Kars - TURKEY

³ School of Health Sciences, Kafkas University, TR-36040 Kars - TURKEY

Article Code: KVFD-2016-16893 Received: 01.10.2016 Accepted: 12.01.2017 Published Online: 15.01.2017

Citation of This Article

Bakir B, Karadag Sari E, Elis Yildiz S, Asker H: Effects of thymoquinone supplementation on somatostatin secretion in pancreas tissue of rats. *Kafkas Univ Vet Fak Derg*, 23 (3): 409-413, 2017. DOI: 10.9775/kvfd.2016.16893

Abstract

In this study, it was aimed to investigate the effects of thymoquinone (TQ), which is the bioactive phytochemical constituent of the seeds oil of *Nigella sativa*, on somatostatin secretion in the rat pancreatic tissue by immunohistochemical method. Animals (n=30) were divided into 3 groups as follows: control, sham and thymoquinone. While Thymoquinone group received 8 mg/kg of TQ which injected for 14 days, only isotonic saline was injected to the sham group for same time. The control group received nothing. Crossman's triple staining was applied to tissue sections to examine histology. Streptavidin-Biotin-Peroxidase Complex method was used to investigate somatostatin immunoreactivity in the pancreatic tissue. Specific somatostatin immunoreactivities were observed in endocrine cells (islets of Langerhans) in all groups. It was determined that somatostatin secretion increased in the thymoquinone group compared to control and sham. In conclusion, thymoquinone administration was concluded to increase the secretion of somatostatin that is known to regulate certain hormones such as growth hormone, insulin, glucagon, secretin and gastrin.

Keywords: Immunohistochemistry, *Nigella sativa*, Pancreas, Thymoquinone

Timokinon Uygulamasının Ratların Pankreas Dokusunda Somatostatin Salgısı Üzerine Etkileri

Özet

Bu çalışmada, *Nigella sativa* (Çörek otu) çekirdeğinin biyoaktif fitokimyasal bileşeni olan timokinonun (TQ), rat pankreas dokusundaki somatostatin salgısı üzerine etkisinin, immünohistokimyasal yöntem kullanılarak incelenmesi amaçlandı. Hayvanlar (n=30) kontrol, sham ve timokinon olmak üzere üç gruba ayrıldı. TQ grubuna, 8 mg/kg TQ 14 gün boyunca enjekte edilirken sham grubuna aynı süre sadece serum fizyolojik enjekte edildi. Kontrol grubuna ise herhangi bir uygulama yapılmadı. Histolojik incelemeler için doku kesitlerine Crosman'ın üçlü boyama yöntemi uygulandı. Pankreas dokusunda somatostatin immunoreaktivitesini incelemek için Streptavidin-Biotin-Peroxidase Complex metodu kullanıldı. Spesifik somatostatin immünoaktivitesi tüm grupların endokrin hücrelerinde (langerhans adacıkları) tespit edildi. Somatostatin sekresyonunun kontrol ve sham grupları ile karşılaştırıldığında thymoquinone grubunda arttığı tespit edildi. Sonuç olarak, TQ uygulamasının, büyüme hormonu, insulin, glukagon, sekretin, ve gastrin gibi hormonların salınımını düzenlediği bilinen somatostatinin salgısını arttırdığı sonucuna varıldı.

Anahtar sözcükler: Immünohistokimya, *Nigella sativa*, Pankreas, Timokinon

INTRODUCTION

The use of medicinal plants as therapeutics drugs is as old as mankind itself ^[1]. *Nigella sativa* (black seed) is an

annual flowering plant in the family Ranunculaceae and is among the most promising medicinal plants. It is used as a natural remedy in the Southern Europe, Northern Africa, Middle East, Saudi Arabia, and Southern and Southwestern



İletişim (Correspondence)



+90 282 2504715



buketbakir@nku.edu.tr

Asia [2]. Black seeds contain carbohydrates, fixed oils, vitamins, minerals, proteins [3], calcium, iron and potassium [4]. The bioactive constituents of the volatile oil of black seeds are thymoquinone (TQ), dithymoquinone (DTQ), thymohydroquinone (THQ) and thymol (THY) [3].

TQ has the most important bioactive components and antioxidant [5], antihistaminic [6], antiinflammatory [7], immunomodulatory [8], anti-microbial [9], anti viral [10], antihelminthic [11], anti-bacterial [12], hepatoprotective [13] and antitumoral [2] effects. Furthermore, several studies have examined the effects of TQ in diabetes, and found that it decreased levels of insulin and restored glucose homeostasis [14,15].

Somatostatin has two biologically active forms that are referred to as somatostatin-14 and somatostatin-28, and it was first isolated from ovine hypothalamus [16]. It can act as a neurotransmitter [17]. It has suppressive effects on growth hormone in the pituitary [18], glucagon, insulin and pancreatic polypeptide in the pancreas [15,19], and secretin and gastrin in the gastrointestinal tract [20].

In this study, it was aimed to examine the effect of TQ on the somatostatin positive cells in the pancreatic tissue of thymoquinone-treated rats.

MATERIAL and METHODS

Animals and Care Condition

Ethics approval was obtained from Kafkas University Local Ethics Committee for Animal Experiments (KAU-HADYEK/2015-38).

A total of 30 rats of the same species (*Sprague Dawley*), which were 40 days old, weighted approximately 250-300 g. The animals were not used in any previous studies and did not mate before. The rats were housed in standard cages at ambient temperature of $22\pm 2^{\circ}\text{C}$ and were maintained on a 12-h light/dark cycle with free access to water and pellet food. The amount of TQ used in our study was based on the study conducted by Hawsawi et al. [21].

Experimental Design

The rats in the control group (n=10) were fed on standard *ad libitum* and normal drinking water. One mL of isotonic saline was administered intraperitoneally to sham group (n=10). Eight mg/kg of TQ (274666, ALDRICH), which was dissolved in 1 mL of isotonic saline, was intraperitoneally injected daily for 14 days to thymoquinone group (n=10). The control group received nothing.

End of the experiment, pancreatic tissue samples were collected under euthanasia after deep ether anesthesia.

Histological Procedures

Pancreatic tissue samples were fixed in 10% formalin

solution for 48 h, dehydrated through graded alcohols and cleared in xylene. Tissues were infiltrated and embedded in paraffin. Sections (5 μm) from the paraffin blocks were stained with Crossman's triple staining.

Immunohistochemical Procedures and Statistical Analysis

Streptavidin-Biotin-Peroxidase Complex method was used to investigate somatostatin immunoreactivity in the pancreatic tissue. Following deparaffinization and re-hydration, sections were rinsed with Phosphate Buffer Solution (PBS) and incubated in 3% H_2O_2 (prepared in 0.1 M PBS) for 15 min. After rinsing with PBS, sections were processed in citrate buffer solution in microwave oven (800 watt) for 10 min in order to expose the antigenic sites. After rinsing with PBS again, sections were incubated in primary somatostatin antibodies (ab183855) (1:1000 dilution ratio) in humid environment at room temperature for 1 h. After rinsing with PBS, sections were kept at room temperature for 15 min with added streptavidin-horse radish peroxidase (HRP) (Invitrogen Histostain plus Broad Spectrum Ref. 85.9943). Sections were rinsed again with PBS and 3,3'-Diaminobenzidine tetrahydrochloride (Dako Corp.) was used for chromogen application. Finally, the sections were counterstained with Mayer's hematoxylin. Negative control sections were incubated only in PBS.

Somatostatin immunoreactivities in tissues were graded with 40X lens zoom from 0 to +3 (0: no reaction; 1: minimal reaction, 2: moderate reaction; 3: strong reaction). Cells were evaluated by two different observers. Intensity of staining of somatostatin positive cells were determined in six sections chosen randomly from six islets of Langerhans of each animals.

Somatostatin positive cells were counted by 100 square ocular micrometer (eye piece graticule) at 100X magnification under Olympus microscope (CX22-type I). All the obtained data was converted to number of somatostatin positive cells per 1 mm^2 unit area [22,23]. Numerical distribution of somatostatin positive cells were observed in six sections chosen from six unit area of Langerhans of each animals.

Statistical Package for the Social Sciences 16.0 (SPSS) software was used. Possible differences were determined by using One-Way ANOVA and Duncan's multiple range test and means were considered significantly different at $P < 0.001$.

RESULTS

Histological Results

The histological examination of pancreatic tissues in all groups exhibited normal findings. The obtained pancreatic tissues contained endocrine (islets of Langerhans) and exocrine cells (Fig. 1).

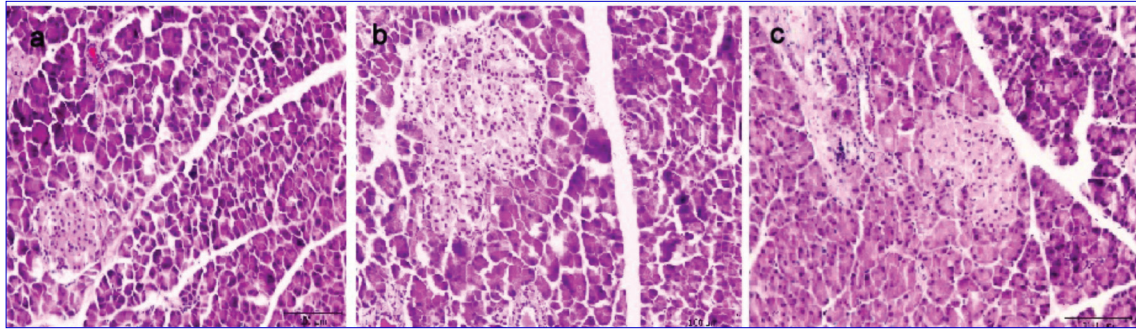


Fig 1. Rat pancreas. (a) Control group, (b) Sham group, (c) Thymoquinone group. Triple staining. Bar = 100 μ m

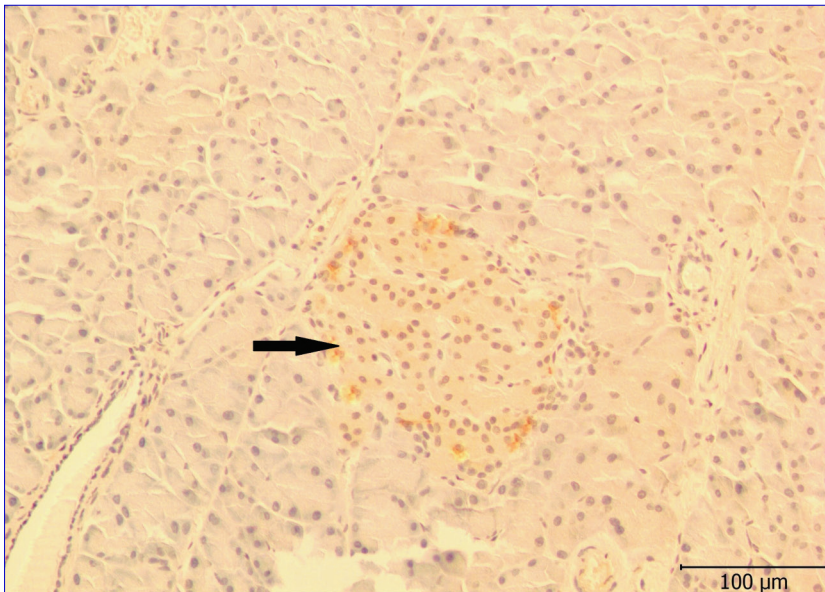


Fig 2. Somatostatin immunoreactivity in rat pancreas in control group. Somatostatin containing cell (arrow). Streptavidin-Biotin-Peroxidase Complex method. Bar = 100 μ m

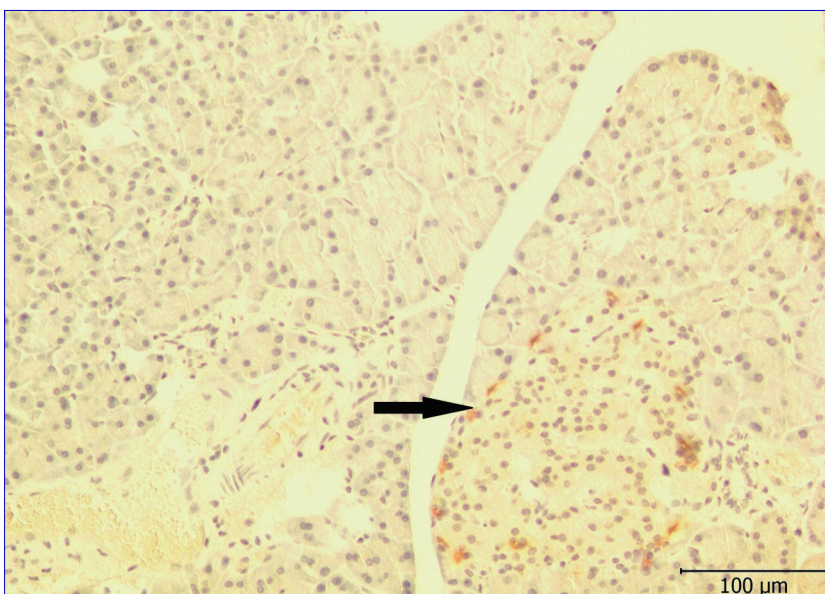


Fig 3. Somatostatin immunoreactivity in rat pancreas in sham group. Somatostatin containing cell (arrow). Streptavidin-Biotin-Peroxidase Complex method. Bar = 100 μ m

Immunohistochemical Results

Somatostatin expression was observed only in the endocrine cells (islets of Langerhans) of all groups. This cells was abundant especially in the peripheral areas of islets of Langerhans (Fig. 2, 3, 4).

When all groups compared with each others regarding intensity of staining of somatostatin expression in islets of Langerhans, values of somatostatin expression in thymoquinone group was significantly higher ($P < 0.001$) than control and sham groups. Intensity of immunohistochemical staining were summarized in Table 1.

When all the groups were compared with each others in terms of count of somatostatin positive cells. Thymoquinone group were observed more than both control and sham groups. And numerical distribution of this cells were determined statistically significant ($P < 0.001$). Count of somatostatin positive cells in islets of Langerhans among groups were summarized in Table 2.

DISCUSSION

Pharmacological plants are used in the preparation of herbal medicines, which are known safer than modern medicines. *N. sativa*, which has been used for many diseases, is one of the famous pharmacological plants [24].

Somatostatin is known to regulate the endocrine system, cell proliferation and neurotransmission [17]. Somatostatin-immunoreactive cells among endocrine cells (islets of Langerhans) in the pancreas were determined by immunohistochemical

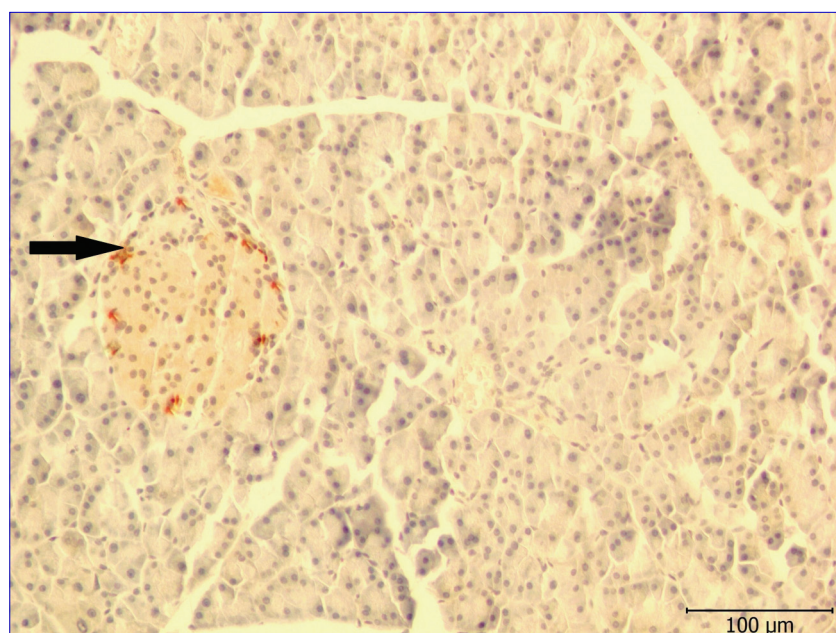


Fig 4. Somatostatin immunoreactivity in rat pancreas in thymoquinone group. Somatostatin containing cell (arrow). Streptavidin-Biotin-Peroxidase Complex method. Bar = 100 μm

Table 1. Comparison of intensity of immunohistochemical staining in islets of Langerhans among groups

Groups	Number (islets of Langerhans)	M+SD	P Value
Control	360	1.62±0.48 ^a	N.S
Sham	360	1.66±0.47 ^a	N.S
Thymoquinone	360	2.79±0.40 ^b	< 0.001

M: mean; SD: standard deviation; ^{a,b} Different superscripts in the same column indicate significant differences between groups (P<0.001); N.S: Not significant

Table 2. Comparison of count of somatostatin positive cells in islets of Langerhans among groups

Groups	Number (unit area)	M+SD	P Value
Control	360	11.13±3.2 ^a	N.S
Sham	360	11.27±4.1 ^a	N.S
Thymoquinone	360	12.24±3.6 ^b	< 0.001

M: mean; SD: standard deviation; ^{a,b} Different superscripts in the same column indicate significant differences between groups (P<0.001); N.S: Not significant

and morphometric studies. It was claimed that somatostatin-immunoreactive cells were rare among endocrine cells (islets of Langerhans) in the pancreas and that these cells were localized especially in the peripheral regions of islets of Langerhans [25,26]. Our study showed that somatostatin-immunoreactive cells were localized in the peripheral region of the endocrine parts and TQ administration increased somatostatin release in the endocrine cells.

The black seed and TQ were determined to have anti-tumoral and anti-diabetic effects on the pancreatic tissue [2,14].

It was reported that TQ have cytotoxic effects on several tumoral cells, including pancreatic adenocarcinoma [27]. It was demonstrated that TQ triggers apoptosis by Bcl-2 protein [28].

Several studies have been focused on *N. sativa* and TQ administration in diabetes [2,14,29]. A study showed that TQ administration in diabetic rats led to significant decrease in blood glucose levels [29]. It was argued that TQ managed to reduce insulin resistance and increase β-cell function [14]. Due to its anti-tumoral and anti-diabetic effects, somatostatin acts as a regulator in some diseases. It also suppresses hormone secretion, growth and proliferation, and triggers apoptosis [30].

Somatostatin is a regulatory hormone for insulin and glucagon, and it inhibits insulin and glucagon release from pancreatic islets. An immunohistochemical

study showed an increase in the number of somatostatin-secreting cells in patients with diabetes [31]. TQ administration also increased both intensity of staining and count of somatostatin positive cells in our study. Diabetes is known as a metabolic disorder and involves an imbalance between stimulatory (insulin) and inhibitory (glucagon, somatostatin) pancreatic islet hormones [32]. Based on our findings, it is possible to consider that TQ administration may be effective in the treatment of some conditions such as diabetes and tumors by increasing somatostatin expression in the pancreatic tissue.

In conclusion, somatostatin expression was present in the pancreatic islets in all groups, somatostatin expression was observed only in the peripheral region and it was determined TQ administration increased both intensity of immunohistochemical staining and numerical distribution of somatostatin positive cells in this study. Our findings may be useful for other studies on somatostatin.

REFERENCES

- Rahmani AH, Aly SM:** *Nigella Sativa* and its active constituents thymoquinone shows pivotal role in the diseases prevention and treatment. *Asian J Pharm Clin Res*, 8, 48-53, 2015.
- Worthen DR, Ghosheh OA, Crooks PA:** The *in vitro* anti-tumor activity of some crude and purified components of blackseed, *Nigella sativa* L. *Anticancer Res*, 18, 1527-1532, 1998.
- Omar A, Ghosheh S, Abdulghani A, Houdi A, Crookscor PA:** High performance liquid chromatographic analysis of the pharmacologically active quinones and related compounds in the oil of the black seed (*Nigella sativa* L.). *J Pharm Biomed Anal*, 19, 757-762, 1999. DOI: 10.1016/S0731-7085(98)00300-8
- Al-Gaby AM:** Amino acid composition and biological effects of supplementing broad bean and corn proteins with *Nigella sativa* (black cumin) cake protein. *Nahrung*, 42, 290-294, 1998. DOI: 10.1002/(SICI)1521-

3803(199810)42:05<290::AID-FOOD290>3.0.CO;2-Y

- 5. Erkan N, Ayranci G, Ayranci E:** Antioxidant activities of rosemary (*Rosmarinus officinalis* L.) extract, black seed (*Nigella sativa* L.) essential oil, carnolic acid, rosmarinic acid and sesamol. *Food Chem*, 110, 76-82, 2008. DOI: 10.1016/j.foodchem.2008.01.058
- 6. Kalus U, Pruss A, Bystron J, Jurecka M, Smekalova A, Lichius JJ, Kiesewtter H:** Effect of *Nigella sativa* (black seed) on subjective feeling in patients with allergic diseases. *Phytother Res*, 17, 1209-1214, 2003. DOI: 10.1002/ptr.1356
- 7. Houghton PJ, Zarka R, de la Heras B, Hoult JR:** Fixed oil of *Nigella sativa* and derived thymoquinone inhibit eicosanoid generation in leukocytes and membrane lipid peroxidation. *Planta Med*, 61 (1): 33-36, 1995.
- 8. Swamy SM, Tan BK:** Cytotoxic and immunopotentiating effects of ethanolic extract of *Nigella sativa* L. seeds. *J Ethnopharmacol*, 70, 1-7, 2000. DOI: 10.1016/S0378-8741(98)00241-4
- 9. Hanafy MS, Hatem ME:** Studies on the antimicrobial activity of *Nigella sativa* seed (black cumin). *J Ethnopharmacol*, 34, 275-278, 1991. DOI: 10.1016/0378-8741(91)90047-H
- 10. Akhter MS, Riffat S:** Field trail of *Saussurea lappa* roots against nematodes and *Nigella sativa* seed against cestodes in children. *J Pak Med Assoc*, 4, 185-187, 1991.
- 11. Khan MA, Ashfaq MK, Zuberi HS, Mahmood MS, Gilani AH:** The *in vivo* antifungal activity of the aqueous extract from *Nigella sativa* seeds. *Phytother Res*, 17, 183-186, 2003. DOI: 10.1002/ptr.1146
- 12. El-Fatraty HM:** Isolation and structure assignment of an antimicrobial principle from the volatile oil of *Nigella sativa* L. seeds. *Pharmazie*, 30, 109-111, 1975.
- 13. Gani MS, John SA:** Evaluation of hepatoprotective effect of *Nigella Sativa* L. *Int J Pharm Pharm Sci*, 5, 428-430, 2013.
- 14. Kanter M:** Protective effects of thymoquinone on β -cell damage in streptozotocin induced diabetic rats. *Tip Arařtırmaları Derg*, 7, 64-70, 2009.
- 15. Bamosa AO, Kaatabi H, Lebdaa FM, Elq AM, Al-Sultanb A:** Effect of *Nigella sativa* seeds on the glycemic control of patients with type 2 diabetes mellitus. *Indian J Physiol Pharmacol*, 54, 344-354, 2010.
- 16. Brazeau P, Vale W, Burgus R, Ling N, Butcher M, Rivier J, Guillemin R:** Hypothalamic polypeptide that inhibits the secretion of immunoreactive pituitary growth hormone. *Science*, 179, 77-79, 1973. DOI: 10.1126/science.179.4068.77
- 17. Patel YC:** Somatostatin and its receptor family. *Front Neuroendocrinol*, 20, 157-198, 1999. DOI: 10.1006/frne.1999.0183
- 18. Koerker D, Ruch W, Chideckel E, Palmer J, Goodner C, Ensinnck J, Gale C:** Somatostatin: Hypothalamic inhibitor of the endocrine pancreas. *Science*, 184, 482-484, 1974. DOI: 10.1126/science.184.4135.482
- 19. Alberti KG, Christensen NJ, Christensen SE, Hansen AP, Iversen J, Lundbaek K, Seyer-Hansen K, Orskov H:** Inhibition of insulin secretion by somatostatin. *Lancet*, 2, 1299-1301, 1973. DOI: 10.1016/S0140-6736(73)92873-0
- 20. Polak JM, Pearse A, Grimelius L, Bloom SR, Arimura A:** Growth-hormone release inhibiting hormone in gastrointestinal and pancreatic D-cells. *Lancet*, 1, 1200-1222, 1975. DOI: 10.1016/S0140-6736(75)92198-4
- 21. Hawsawi ZA, Basil AA, Bamosa AO:** Effect of *Nigella sativa* (Black Seed) and thymoquinone on blood glucose in albino rats. *Annals Saudi Med*, 21, 3-4, 2001.
- 22. Böck P:** *Romeis Mikroskopische Technik*. 17th edn., 561, Urban and Schwarzenhferg Verlag, München, 1989.
- 23. Elis Yıldız S, Yigit F, Duman Aydin B, Karadag Sari E, Deprem T, Koral Taşı S:** Effects of kefir, koumiss, milk and yoghurt administration on distribution of plasma cells and mast cells in mice spleen. *Kafkas Univ Vet Fak Derg*, 21, 195-201, 2015. DOI: 10.9775/kvfd.2014.12015
- 24. Ali BH, Blunden G:** Pharmacological and toxicological properties of *Nigella sativa*. *Phytother Res*, 17, 299-305, 2003. DOI: 10.1002/ptr.1309
- 25. Gulmez N, Kocamis H, Aslan S, Nazli M:** Immunohistochemical distribution of cells containing insulin, glucagon and somatostatin in the goose (*Anser anser*) pancreas. *Turk J Vet Anim Sci*, 28, 403-407, 2004.
- 26. Kocamis H, Karadag Sari E, Nazli M, Gulmez N, Aslan S, Deprem T:** Immunohistochemical distribution of insulin, glucagon, and somatostatin containing cells in the pancreas of the rat (*Wistar albino*). *Kafkas Univ Vet Fak Derg*, 15, 611-614, 2009. DOI: 10.9775/kvfd.2009.086-A
- 27. Islam SN, Begum P, Ahsan T, Huque S, Ahsan M:** Immunosuppressive and cytotoxic properties of *Nigella sativa*. *Phytother Res*, 18, 395-398, 2004. DOI: 10.1002/ptr.1449
- 28. Gali-Muhtasib H, Diab-Assaf M, Boltze C, Al-Hmaira J, Hartig R, Roessner A, Schneider-Stock R:** Thymoquinone extracted from black seed triggers apoptotic cell death in human colorectal cancer cells via a p53-dependent mechanism. *Int J Oncol*, 25, 857-866, 2004.
- 29. Al-Logmani A, Zari T:** Long-term effects of *Nigella sativa* L. oil on some physiological parameters in normal and streptozotocin-induced diabetic rats. *J Diabetes Mellitus*, 1, 46-53, 2011. DOI: 10.4236/jdm.2011.13007
- 30. De Herder WW, Hofland LJ, Van Der Lely AJ, Lamberts SW:** Somatostatin receptors in gastroentero-pancreatic neuroendocrine tumours. *Endoc Relat Cancer*, 10, 451-458, 2003.
- 31. Orci L, Baetens D, Rufener C, Amherdt M, Ravazzola M, Studer P:** Hypertrophy and hyperplasia of somatostatin-containing D-cells in diabetes. *Proc Natl Acad Sci USA*, 73, 1338-1342, 1976.
- 32. Keller J, Aghdassi AA, Lerch MM, Mayerle JV, Layer P:** Tests of pancreatic exocrine function-clinical significance in pancreatic and non-pancreatic disorders. *Best Pract Res Clin Gastroenterol*, 23, 425-439, 2009. DOI: 10.1016/j.bpg.2009.02.013