Biological Trace Element Research (2021) 199:173–184
https://doi.org/10.1007/s12011-020-02111-0

The Effects of Selenium in Acrylamide-Induced Nephrotoxicity in Rats: Roles of Oxidative Stress, Inflammation, Apoptosis, and DNA Damage

Emin Sengul[1] · Volkan Gelen[2] · Serkan Yildirim[3] · Samet Tekin[1] · Yusuf Dag[1]

Received: 25 January 2020 / Accepted: 3 March 2020 / Published online: 12 March 2020
© Springer Science+Business Media, LLC, part of Springer Nature 2020

Abstract

We sought to determine the effects of selenium (Se) on acrylamide (ACR)-induced nephrotoxicity in rats. In our study, 50 adult male Sprague-Dawley rats weighing 200–250 g were randomly divided into five groups. The control group was given intragastric (i.g.) saline (1 mL) for 10 days. The ACR group was given i.g. ACR in saline (38.27 mg/kg titrated to 1 mL) for 10 days. The Se0.5 + ACR and Se1 + ACR groups were administered Se in saline (0.5 and 1 mg/kg, respectively) for 10 days and given i.g. ACR (38.27 mg/kg) one hour after the Se injections. The Se1 group was administered i.g. Se (1 mg/kg) for 10 days. On day 11, intracardiac blood samples were obtained from the rats while they were under anesthesia, after which they were euthanized by decapitation. Urea and creatinine concentrations of blood serum samples were analyzed with an autoanalyzer. Enzyme-linked immunosorbence immunosorbent assay (ELISA) was used to quantify malondialdehyde (MDA), superoxide dismutase (SOD), glutathione (GSH), glutathione peroxidase (GPx), catalase (CAT), tumor necrosis factor-α (TNF-α), nuclear factor-κB (NF-κB), interleukin (IL)-33, IL-6, IL-1β, cyclooxygenase-2 (COX-2), kidney injury molecule-1 (KIM-1), mitogen-activated protein kinase-1 (MAPK-1), and caspase-3 in kidney tissues. Renal tissues were evaluated by histopathological and immunohistochemical examinations for 8-hydroxylo-2′-deoxyguanosin 8-hydroxy-2′-deoxyguanosine (8-OhDG) and Bax. Serum urea and creatinine levels were higher in the ACR group than in the control, and these ACR-induced increases were prevented by high doses of Se. Additionally, ACR induced the renal oxidative stress, inflammation, apoptosis, and damage to DNA and tissue; likewise, these were prevented by high doses of Se. Taken with ACR, Se confers protection against ACR-induced nephrotoxicity in rats by reducing oxidative stress, inflammation, apoptosis, and DNA damage.

Keywords Acrylamide · Inflammation · Nephrotoxicity · Oxidative stress · Rat · Selenium

Introduction

Acrylamide (ACR) is a chemical compound that contains highly reactive α-β unsaturated carbonyl groups. ACR is used as an additive in chemical engineering, molecular laboratories, water treatment systems, textiles, mining, paper manufacturing, and the cosmetic industry [1, 2]. ACR formation occurs during food processing, especially that of potato chips, as a result of exposing carbohydrates to temperatures higher than 200 °C [3–6]. ACR has been detected in many foods, including meat, bread, French fries, chips, cereals, and roasted coffee, which prepared at high temperatures (above 180–200 °C); previous studies have reported that ACR has carcinogenic, teratogenic, and neurotoxic effects [7–11]. Following exposure by ingestion or inhalation, ACR accumulates in the blood at higher levels than in other tissues. After ACR exposure, renal tubular cells undergo vacuolar degenerative changes, inflammatory cell infiltration, and periglomerular edema [12, 13]. In addition, it has been observed in rats that ACR administration increases serum urea, creatinine, uric acid, and renal proinflammatory cytokine levels, while also inducing lipid peroxidation and DNA damage [14]. In an effort to prevent and treat ACR nephrotoxicity, the effects of some antioxidant and anti-inflammatory compounds are currently being investigated [14–17]. Selenium (Se) is a compound frequently used

✉ Emin Sengul
emin.sengul@atauni.edu.tr; emin.sengul97@gmail.com

[1] Department of Physiology, Faculty of Veterinary, Atatürk University, Erzurum, Turkey

[2] Department of Physiology, Faculty of Veterinary, Kafkas University, Kars, Turkey

[3] Department of Pathology, Faculty of Veterinary, Atatürk University, Erzurum, Turkey

for therapeutic and protective purposes in animal models of experimentally induced nephrotoxicity [18–21]. Various selenoproteins play an important role in antioxidant defense systems [22], and Se has anti-inflammatory [23–25] and anti-apoptotic [26–28] effects.

To our knowledge, the possible effects of Se on ACR-induced renal damage have not been investigated yet. Based on this information, we hypothesize that Se can prevent or reduce ACR-induced nephrotoxicity. In this study, we investigated the effects of Se on renal oxidative stress, inflammation, apoptosis, and DNA damage caused by ACR-induced nephrotoxicity in rats.

Material and Methods

Chemicals

Acrylamide (≥ 99%) and Se (CAS Number: 7782-49-2) were supplied by Sigma Chemical Co. (St. Louis, MO). Malondialdehyde (MDA), glutathione (GSH), superoxide dismutase (SOD), glutathione peroxidase (GPx), catalase (CAT), tumor necrosis factor-alpha (TNF-α), interleukin-1 beta (IL-1β), interleukin-6 (IL-6), interleukin-33 (IL-33), kidney injury molecule-1 (KIM-1), nuclear factor kappa-B (NF-κB), cyclooxygenase-2 (COX-2), mitogen-activated protein kinase-1 (MAPK1) and caspase-3 enzyme linked immunosorbent assay (ELISA) kits were purchased from YL Biont (Shangai, China). 8-hydroxy-2' -deoxyguanosine (8-OHdG) and Bax antibodies for immunohistochemical staining were purchased by Abcam (United Kingdom).

Animals

In this study, 50 male Sprague-Dawley rats weighing 200–250 g were used. The rats were obtained from the Atatürk University Medical Experimental Application and Research Center and were housed at a room temperature of 25 °C with a standard 12-h light–dark cycle, ample ventilation, and ad libitum access to standard diet (Bayramoglu Feed and Flour Industry Trade A.Ş., Erzurum) and water.

Experimental Design

The rats were weighed before the experiment began and were randomly divided into five groups. Experimental groups were formed as follows:

Group I (control) was given 1 mL of intra-gastric (i.g.) saline daily for 10 days.

Group II (ACR) was given ACR in saline (38.27 mg/kg, i.g.) daily for 10 days [29].

Group III (Se0.5 + ACR) was given Se in saline (0.5 mg/kg, i.g) [20] for 10 days; ACR in saline (38.27 mg/kg, i.g.) was given one hour after Se administration.

Group IV (Se1 + ACR) was given Se in saline (1 mg/kg, i.g) [20] for 10 days; ACR in saline (38.27 mg/kg, i.g.) was given one hour after Se administration.

Group V (Se1) was given Se in saline (1 mg/kg, i.g.) for 10 days.

On day 11 of the experiment, the rats were weighed, and intracardiac blood samples were obtained while the rats were under ketamine-xylazine anesthesia, after which they were euthanized by decapitation. The kidney tissues of the rats were excised and weighed. The right kidney of each rat was washed with saline and immediately immersed and fixed in 10% formaldehyde for histopathological and immunohistochemical examination. The left kidney was washed with cold phosphate buffer, frozen with liquid nitrogen, and stored at −20 °C until the day of analysis.

Preparation of Serum Samples for Analysis of Urea and Creatinine Parameters

Blood samples were transferred to gel tubes with clotting factors and centrifuged at 3500–4000 rpm for 10 min at 4 °C. Serum samples were taken into godels and stored at −20 °C until the time of analysis. Serum urea and creatinine parameters were analyzed with a modular autoanalyzer (Randox IV Monaco Auto-Chemistry Analyzer).

Preparation of Renal Homogenates

The kidney tissues were homogenized to 5 μm in a TissueLyser II (Qiagen) with liquid nitrogen on the day of analysis; they were weighed and diluted to 1:20 with a phosphate buffer (pH 7.4) before homogenization. After homogenization, the homogenates were centrifuged for 20 min at 3000 rpm at 4 °C, and the supernatant was used for enzyme-linked immunosorbence assay (ELISA) analysis.

Analysis of Lipid Peroxidation and Antioxidant Enzyme Activities

Lipid peroxidation and antioxidant enzyme markers were analyzed using commercial ELISA kits. The levels of renal MDA and GSH and the activities of renal SOD, GPx, and CAT were quantified using their respective anti-rat ELISA kits (YL Biotech, Shanghai, China) according to the manufacturer's instructions.

Analysis of Inflammation Parameters and Kidney Injury Molecule-1 Levels

In kidney tissue homogenates, proinflammatory cytokines and KIM-1 were quantified using commercial ELISA kits. TNF-α, IL-6, IL-1β, IL-33, KIM 1, COX-2, and NF-κB levels were measured with anti-rat ELISA kits (YL Biotech, Shanghai, China) according to the manufacturer's instructions.

Analysis of Renal Apoptosis

MAPK1 and caspase-3 activity were determined using anti-rat ELISA kits (YL Biotech, Shanghai, China) according to the manufacturer's instructions.

Histopathological Analysis

After the necropsies of the rats were performed, kidney tissues were fixed in 10% formalin solution for 48 h. The samples were embedded in paraffin blocks after routine tissue tracking procedures. Sections of a thickness of 4 μm were taken from each block. Tissue sections were stained with hematoxylin-eosin (HE) for histopathological examination and visualized by light microscopy (Leica DM1000, Germany). The sections were graded as none (−), mild (+), moderate (++), or severe (+++) according to their immunoreactivity.

Immunohistochemical Analysis

The expression of 8-OHdG and Bax in the kidney tissues was determined with specific monoclonal antibodies. The renal tissue sections (4 μm) were deparaffinized. Subsequently, diaminobenzidine (DAB) was used as a chromogen, and slides were counterstained with hematoxylin, dehydrated, and covered by coverslips. Immunohistochemical staining of 8-OHdG was performed using anti-8-OHdG antibody (SantaCruz; 1:2500 dilution) with a Novolink polymer detection kit (Leica Microsystems Pte Ltd., Taipei, Taiwan) according to the manufacturer's instructions. Immunohistochemical staining of Bax was performed using the anti-Bax antibody (B-9, SantaCruz) according to the manufacturer's instructions. A minimum of ten high-power fields (×200) were taken per section, and the number of positive cells in each high-power field was counted. The mean number of positive cells was calculated to reflect the intensity of positive expression. The sections were graded as none (−), mild (+), moderate (++), and severe (+++) according to their immunoreactivity [30, 31].

Statistical Analysis

At the end of the studies, quantitative values were evaluated by applying Tukey test after one-way ANOVA was used in statistical analysis of more than two independent groups in SPSS 20.00 statistical data program. All the values were expressed as mean ± standard error (± SEM) and $P < 0.05$ was sustained as significant. The Kruskal–Wallis test was used for the analysis of histopathological examinations in terms of the differences between groups, and Mann-Whitney U test was used to compare the matched groups.

Results

Effects of Se on Body and Kidney Weights in ACR-Induced Nephrotoxicity

In this study, we investigated the effects of Se on ACR-induced nephrotoxicity in rats. The live weights of the rats did not differ among experimental groups before the experiment. During the experiment, the live weights of the ACR and Se0.5 + ACR groups were decreased significantly compared to the control. However, kidney weights did not differ among groups (Table 1).

Effects of Se on Renal Function Parameters

Serum urea and creatinine levels were significantly increased in the ACR and Se0.5 + ACR groups compared to the control group ($p < 0.01$). High doses of Se prevented this ACR-induced increase in urea and creatinine levels ($p < 0.05$). It was noted that urea levels tended to decrease in the Se0.5 + ACR group compared to the ACR group, but this was not statistically significant (Table 2).

Effects of Se on Renal MDA and GSH Levels

We observed that the ACR and Se0.5 + ACR groups had significantly higher renal MDA levels compared to the control group. Moreover, MDA levels were lower in the Se0.5 + ACR group than in the ACR group, but this was not statistically significant ($p > 0.05$). However, a higher dose of Se prevented increases in MDA levels ($p < 0.01$). Additionally, GSH levels decreased significantly in the ACR group compared to the control and Se1 + ACR groups ($p < 0.01$, Table 2), and low doses of Se did not prevent these GSH level reductions ($p > 0.05$, Table 2).

Effects of Se on Renal Antioxidant Enzyme Activities

Renal SOD, GPx, and CAT activities were significantly lower in the ACR group than in the control group ($p < 0.01$). SOD activity was increased in the Se1 + ACR group compared to the ACR group, but this was not statistically significant ($p > 0.05$). Likewise, GPx activity was significantly higher in the Se1 + ACR group than in the ACR group ($p < 0.01$).

Table 1 Body weights and kidney weights of the rats in the experimental groups at the beginning and end of the experiment

Parameters	Control	ACR	Se0,5 + ACR	Se1 + ACR	Se1
Initial body weights (g)	221,00 ± 12,56[a]	216,00 ± 15,58[a]	218,00 ± 12,57[a]	217,00 ± 15,66[a]	214,20 ± 11,62[a]
Final body weights (g)	269,10 ± 18,62 [a]	198,50 ± 24,30 [b]	205,40 ± 29,52 [b]	224,50 ± 29,04[ab]	238,60 ± 30,09[ab]
Absolute kidney weights (g)	1,16 ± 0,09[a]	0,98 ± 0,13[a]	1,02 ± 0,13[a]	1,04 ± 0,09[a]	1,08 ± 0,21[a]

[a-b]: $p < 0.01$; [a-c, b-c]: $p < 0.05$

In the Se0.5 + ACR and Se1 + ACR groups, CAT activity was higher than in the ACR group but lower than in the control group (Table 2).

Effects of Se on Renal Inflammation

Renal TNF-α, IL-6, and IL-1β levels were significantly higher in the ACR group compared to the control, Se1 + ACR, and Se1 groups (Fig. 1). Low doses of Se did not prevent these ACR-induced increases ($p > 0.05$, Fig. 1). In the ACR group, renal IL-33 and KIM-1 levels and COX-2 activity were significantly increased compared to the control, Se1 + ACR, and Se1 groups (Fig. 2). High doses of Se suppressed this effect significantly ($p < 0.05$, Fig. 2), while low doses of Se prevented increases only of KIM-1 levels ($p < 0.05$, Fig. 2b). In addition, renal NF-κB levels were significantly higher in the ACR group than in the control, Se1 + ACR, and Se1 groups (Fig. 2d), with the Se1 + ACR group being lower than the ACR group but significantly higher than the control group (Fig. 2d).

Renal MAPK1 and Caspase-3 Activity

Renal MAPK1 and caspase-3 activity were significantly higher in the ACR group than in the control ($p < 0.01$), Se1 + ACR ($p < 0.05$), and Se1 ($p < 0.01$) groups (Fig. 3). MAPK1 activity was lower in the Se1 + ACR group than in the ACR group ($p < 0.05$). However, the Se1 + ACR group had significantly higher MAPK1 activity than the control group ($p < 0.05$) (Fig. 3a).

Histopathological and Immunohistochemistry Findings

The renal tissues of the control rats had a normal histological structure (Fig. 4a), whereas rats in the ACR group had severe degeneration and necrosis in the tubular epithelium and severe hyperemia in the interstitial and glomerular vessels (Fig. 4b). Severe degeneration of the tubular epithelium, moderate necrosis, and severe hyperemia in interstitial and glomerular vessels were observed in kidney tissues of the Se0.5 + ACR group (Fig. 4c). In the renal tissues of the Se1 + ACR group, mild degeneration of the tubular epithelium and mild hyperemia in the interstitial and glomerular vessels were observed (Fig. 4d). The kidney tissues of the Se1 group appeared to be histologically normal (Fig. 4e, Table 3). When the kidney tissues of rats in the control group were examined immunohistochemically, negligible 8-OHdG and Bax expression were observed (Figs. 5a, 6a). High levels of cytoplasmic 8-OHdG and Bax expression were observed in the renal tubular epithelial cells of the ACR group (Figs. 5b, 6b), but expression was moderate in the Se0.5 + ACR group (Figs. 5c, 6c) and minimal in the Se1 + ACR group (Figs. 5d, 6d). In the Se1 group, renal 8-OHdG and Bax expression were not detected (Figs. 5e, 6e). These immunohistochemical findings are summarized in Table 3.

Discussion

In this study, the potential therapeutic effects of Se, a trace element, on oxidative stress, inflammation, apoptosis, and

Table 2 Effects of Se on renal function tests and some oxidative stress parameters in ACR-induced nephrotoxicity ($n = 10$)

Parameters	Control	ACR	Se0,5 + ACR	Se1 + ACR	Se1
Ürea (mg/dL)	34,81 ± 1,75[a]	50,90 ± 2,12[bc]	46,66 ± 3,44[c]	40,95 ± 4,98[ac]	37,43 ± 1,76[a]
Creatinine (mg/dL)	0,67 ± 0,02[a]	0,82 ± 0,04[b]	0,76 ± 0,03[b]	0,70 ± 0,02[a]	0,66 ± 0,02[a]
MDA (nmol/mg protein)	11,86 ± 1,06[a]	23,00 ± 4,42[bc]	17,04 ± 3,96[c]	13,83 ± 1,94[ac]	12,47 ± 1,46 [ac]
GSH (ng/mg protein)	7,17 ± 1,22[a]	3,35 ± 0,77[b]	4,12 ± 0,54[b]	5,91 ± 0,85[a]	6,10 ± 1,02[a]
SOD (ng//mg protein)	13,06 ± 2,81[a]	7,56 ± 1,61[b]	8,39 ± 0,94[b]	10,60 ± 1,70[ab]	12,05 ± 2,48[a]
GPx (ng/mg protein)	20,60 ± 2,51[a]	10,90 ± 2,05[b]	13,77 ± 2,07[b]	18,05 ± 1,41[a]	20,24 ± 2,60[a]
CAT (ng/mg protein)	9,56 ± 2,05[a]	4,30 ± 0,89[b]	5,88 ± 0,50[c]	6,51 ± 0,84[c]	9,36 ± 1,44[a]

[a-b]: $p < 0.01$; [a-c, b-c]: $p < 0.05$

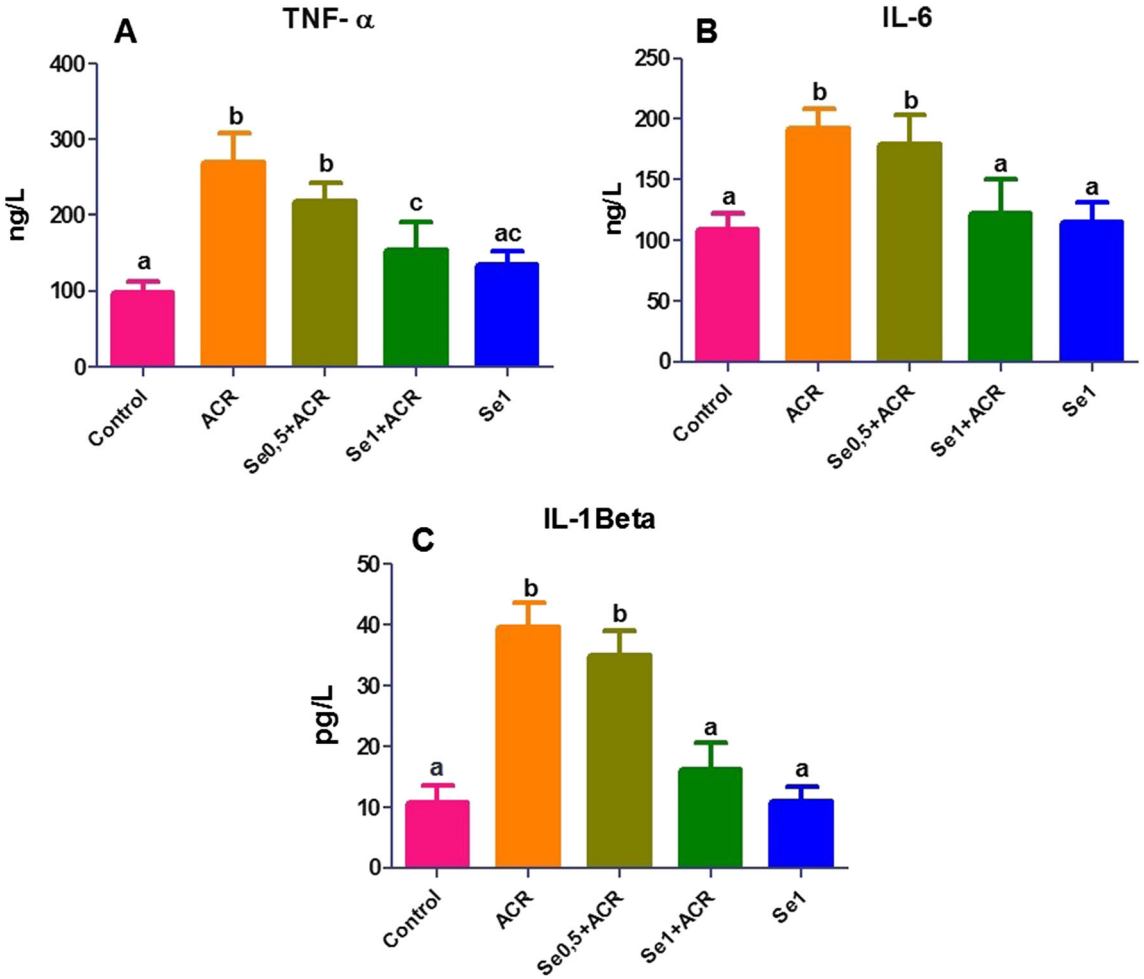

Fig. 1 Effects of Se on renal TNF-α (**a**), IL-6 (**b**) and IL-1β (**c**) levels in ACR-induced nephrotoxicity ($^{a\text{-}b}$ $p < 0.01$; $^{a\text{-}c,\ b\text{-}c}$ $p < 0.05$; $n = 10$; statistically different groups are represented by different letters)

DNA damage in ACR-induced nephrotoxicity were investigated in rats. Blood urea and creatinine levels are measured routinely for the evaluation of renal function in clinical settings because increases in their levels are highly indicative of renal dysfunction [32, 33]. Gelen et al. [34] reported a significant increase in serum creatinine and blood urea nitrogen (BUN) levels in a 5-fluorouracil (5-FU)-induced nephrotoxicity model in rats. Ghorbel et al. [16] founded that serum urea and creatinine levels increased significantly in ACR nephrotoxicity compared to controls. In our study, serum urea and creatinine levels were significantly increased in the ACR group compared to the control group. It was notable that a high dose of Se had protective effects against ACR nephrotoxicity and that urea and creatinine levels were significantly lower than in the ACR group and similar to that of the control. These results are compatible with several previous studies [35], and Se normalized the serum urea and creatinine levels by preventing kidney tissue injury and renal dysfunction through antioxidant and anti-inflammatory effects.

During the routine physiological activities of cells, chemical compounds called oxidants are constantly being released, and their production is controlled by antioxidant systems. The disturbance of the balance between oxidant and antioxidant systems is defined as oxidative stress. Oxidative stress plays a crucial role in the pathogenesis of many diseases and toxicities [36]. Experimental studies of ACR-induced nephrotoxicity in rats showed that renal MDA levels were increased, and GSH, GSH-Px, SOD, and CAT activities were significantly decreased in ACR-treated rats [16, 37]. Consistent with the literature, we observed that ACR induced the stimulation of renal lipid peroxidation, increased the MDA levels, and caused a significant decrease in GSH, GPx, SOD, and CAT activities. Soudani et al. [38] found that Se (0.5 mg/kg) administration in animal models of chromium-induced renal toxicity suppressed chromium-induced oxidative stress by preventing increases in renal MDA levels and reducing SOD, GPx, and CAT activity. In another study on cadmium-induced nephrotoxicity, cadmium co-administration with Se (0.1 mg/kg, 30 days) inhibited the antioxidant effects of Se by

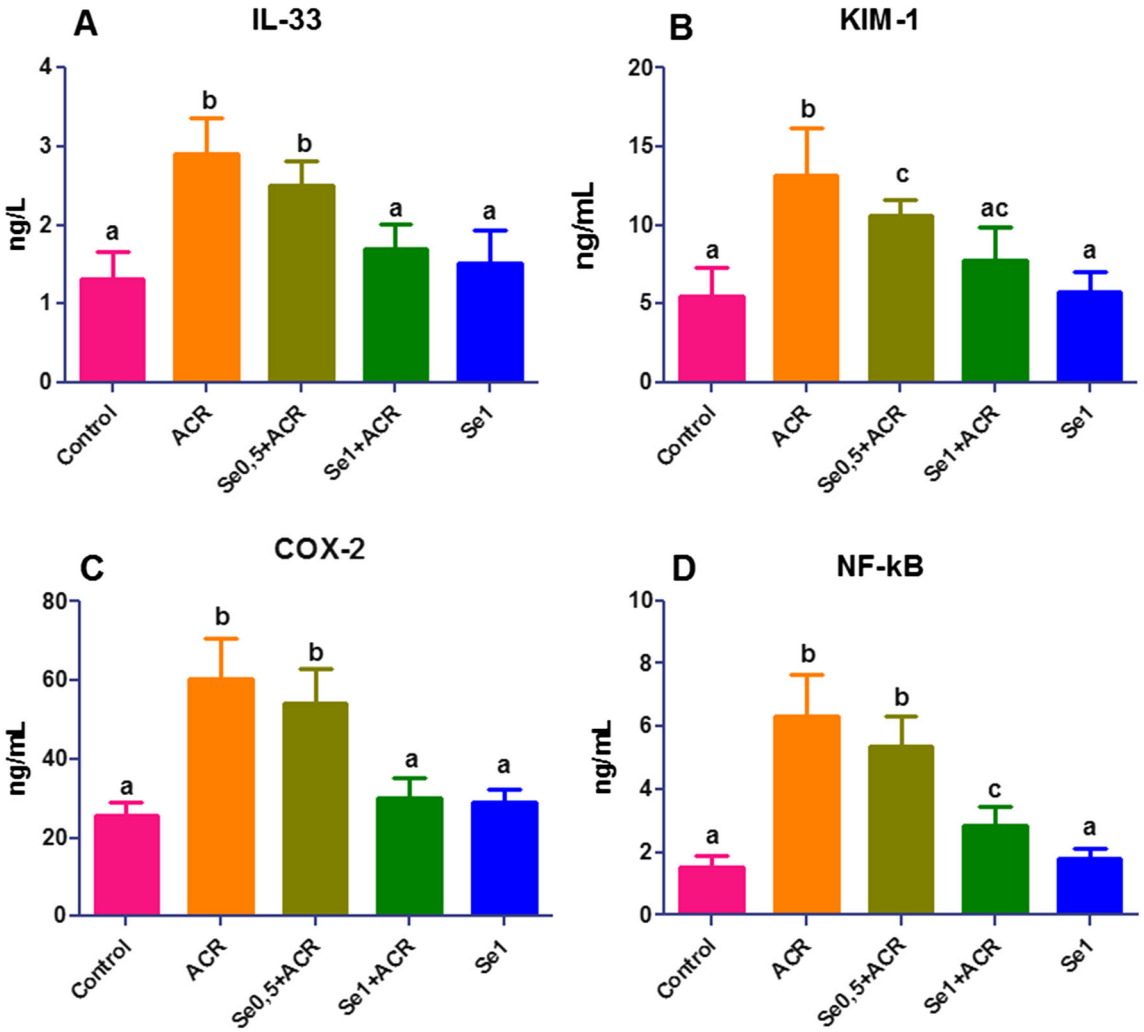

Fig. 2 Effects of Se on levels of renal IL-33 (**a**), KIM-1 (**b**), COX-2 (**c**) and NF-κB (**d**) in ACR-induced nephrotoxicity ($^{a\text{-}b}$ $p < 0.01$; $^{a\text{-}c,\ b\text{-}c}$ $p < 0.05$; $n = 10$; statistically different groups are represented by different letters)

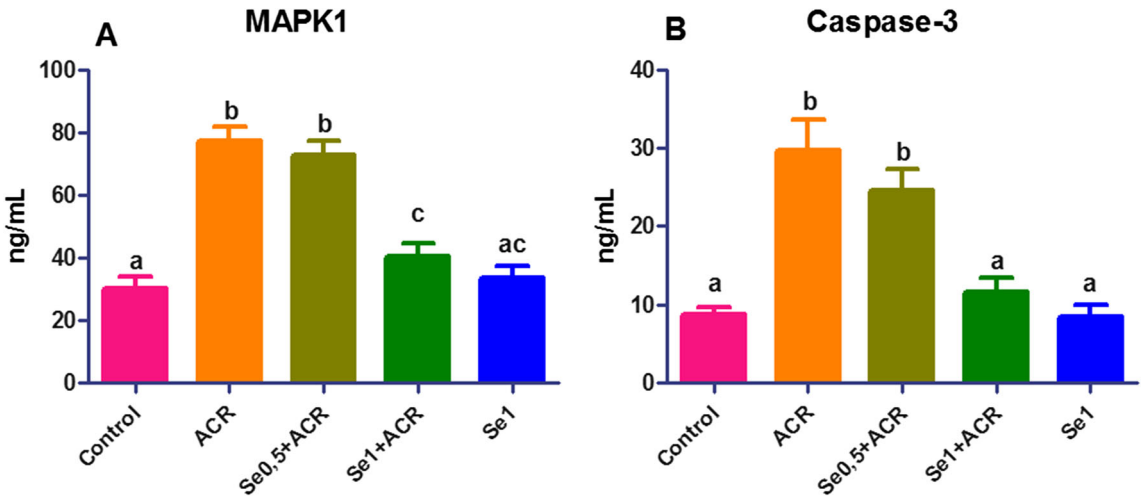

Fig. 3 Effects of Se on activities of renal MAPK1 (**a**) and Caspase-3 (**b**) in ACR-induced nephrotoxicity ($^{a\text{-}b}$ $p < 0.01$; $^{b\text{-}c}$ $p < 0.05$ $n = 10$; statistically different groups are represented by different letters)

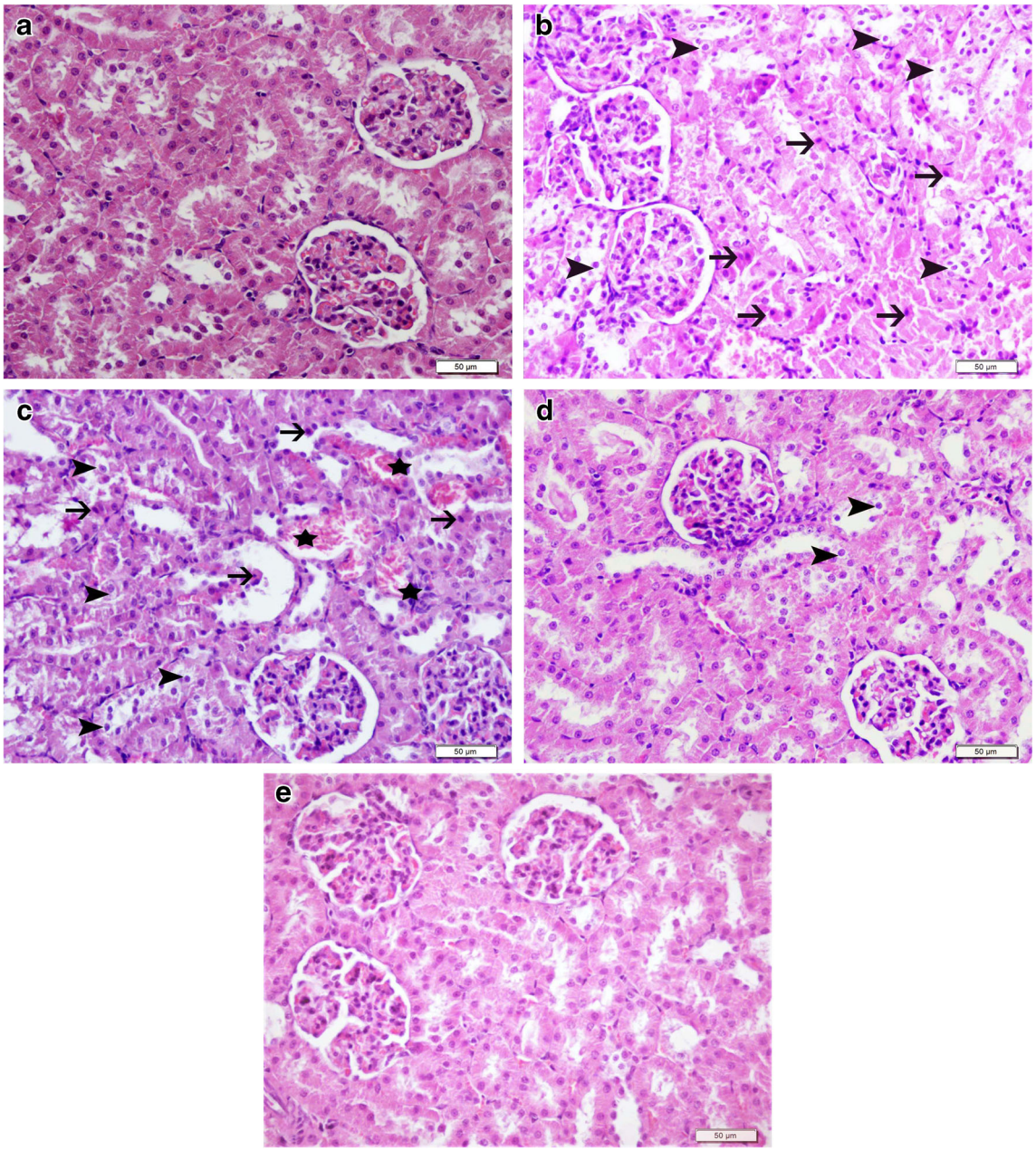

Fig. 4 The effects of Se application on renal histopathology in ACR-induced nephrotoxicity, H&E, bar 50 µm **a** (control) and **e** (Se1) kidney tissue, normal histological appearance; **b** (ACR) severe degeneration (arrowheads) and necrosis (arrows) in the kidney tubular epithelium, severe hyperemia in the interstitial and glomerular vessels; **c** (Se0,5 + ACR) severe degeneration in the tubules epithelium (arrowheads), moderate necrosis (arrows), severe hyperemia (stars) in the interstitial and glomerular vessels; **d** (Se1 + ACR) mild degeneration in the tubules epithelium (arrowheads), mild hyperemia in the interstitial and glomerular vessels

Table 3 Histopathological and immunohistochemical findings and their scores in kidney tissue

	Control	ACR	Se0,5 + ACR	Se1 + ACR	Se1
Degeneration of tubular epithelium	–	+++	+++	+	–
Necrosis of tubular epithelium	–	+++	++	–	–
Vascular hyperemia	–	+++	+++	++	–
8 OHdG expression	–	+++	++	+	–
Bax expression	–	+++	++	+	–

none (−), mild (+), moderate (++), and severe (+++)

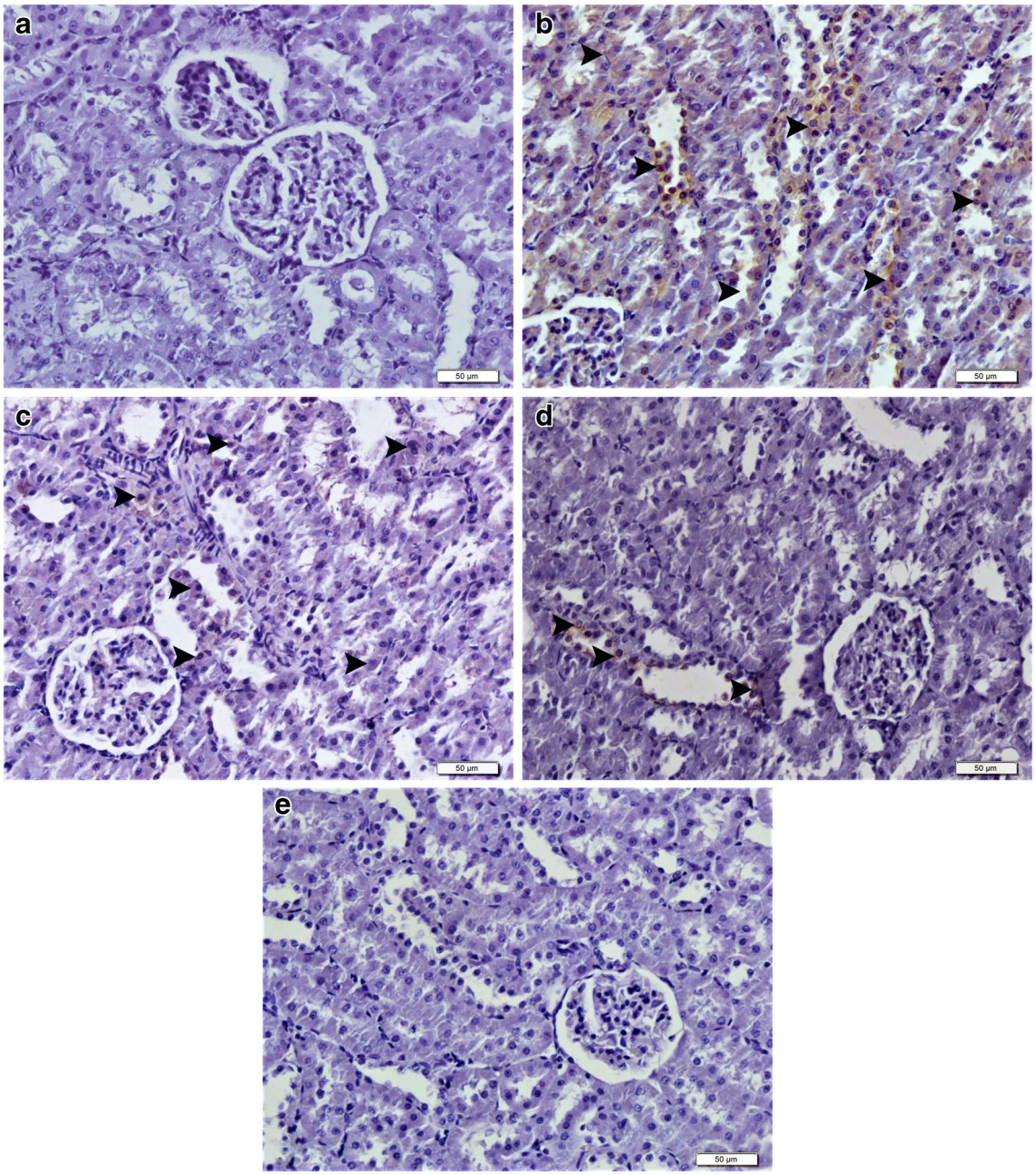

Fig. 5 Effects of Se application on ACR-induced nephrotoxicity kidney 8 OHdG expression, IHC-P, bar 50 µm **a** (control) and **e** (Se1) kidney tissue, negative 8 OHdG expression; **b** (ACR) severe cytoplasmic 8 OHdG expression in kidney tubular epithelium (arrowheads); **c** (Se0,5 + ACR) moderate intensity cytoplasmic 8 OHdG expression in tubules epithelium (arrowheads); **d** (Se1 + ACR):mild cytoplasmic 8 OHdG expression in the tubules epithelium (arrowheads)

significantly increasing renal MDA levels and decreasing SOD, GSH, GPx, and CAT activity [39]. Se is known to be associated with regulatory functions in cell growth, survival and cytotoxicity, as well as transformations involving redox regulation, chemical toxicity. Some reports showed that Se treatment may be associated with cell protection, recovery of glutathione peroxidase and thioredox inhibition in reductase activities, reduction of free radical-mediated lipid peroxidation, and regeneration of glutathione [40]. In our study, we showed that Se elicited antioxidant effects by suppressing ACR-induced renal oxidative stress, and our findings were consistent with the literature.

TNF-α, IL-1β, and IL-6 are proinflammatory cytokines that induce an acute response of inflammation by inducing the expression of adhesion molecules in endothelial cells, stimulating inflammatory cells, and causing circulating leukocytes to adhere to the endothelium [41]. IL-33, another proinflammatory cytokine [42], is released from necrotic cells and

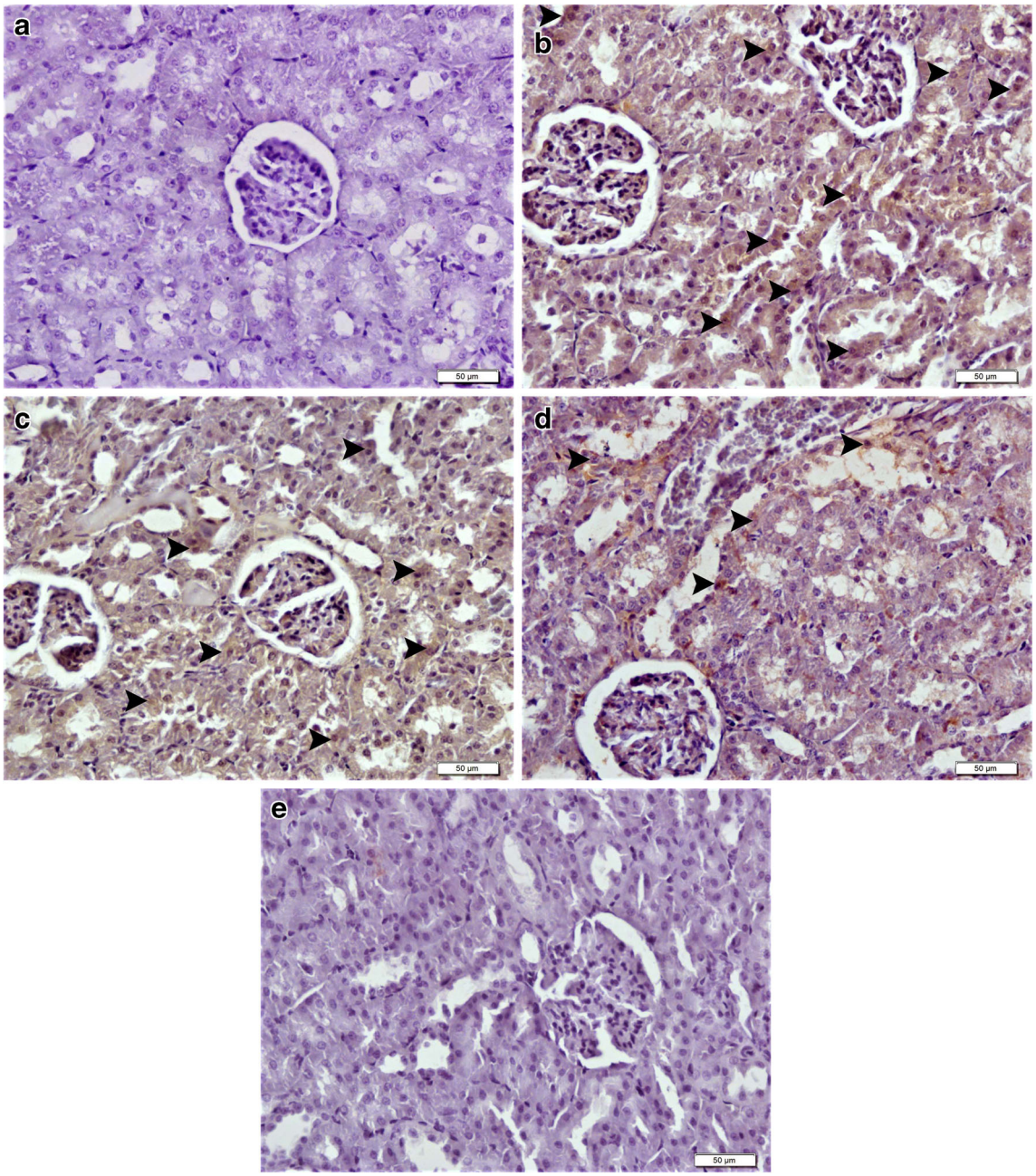

Fig. 6 Effects of Se application on ACR-induced nephrotoxicity kidney Bax expression, IHC-P, Bar 50 µm **a** (control) and **e** (Se1) kidney tissue, negative Bax expression; **b** (ACR) severe cytoplasmic Bax expression in kidney tubular epithelium (arrowheads); **c** (Se0,5 + ACR) moderate intensity cytoplasmic Bax expression in tubules epithelium (arrowheads); **d** (Se1 + ACR) mild cytoplasmic Bax expression in the tubules epithelium (arrowheads)

binds to STR2R receptors on immune cells, thereby stimulating inflammation by increasing secretion of cytokines [43]. In a mouse study, it was found that TNF-α and IL-1β levels increased significantly in ACR-induced neurotoxicity compared to controls, and that ACR promoted inflammation [11]. Increased ROS levels in ACR toxicity promote an increase in proinflammatory cytokine levels. In our study, ACR stimulated an oxidative stress and induced a renal ROS production. Ghorbel et al. [44] reported a significant increase in liver TNF-α, IL-1β, and IL-6 levels in ACR-treated rats compared to controls. Similarly, Kandemir et al. [45] found that IL-33 levels in renal paracetamol toxicity were increased in the paracetamol group compared to controls. In our study, it was noted that TNF-α, IL-1β, IL-6, and IL-33 levels in the ACR group were significantly higher than control rats, and these results were consistent with the literature. An earlier study has also reported that Se administration has anti-inflammatory effects in rats with experimental acute kidney

injury [39]. In rats with Se-deficient nutrition have determined to be increase serum levels of IL-1β, TNF-α, and IL-6 [46]. Our results were similar with regard to the anti-inflammatory effects of Se.

NF-κB is a transcription factor that plays an important role in immune and proinflammatory responses and is activated by oxidative stress. NF-κB amplifies the inflammatory response and stimulates the production of proinflammatory cytokines such as IL-6, TNF-α, and IL-1β [47]. Increased NF-κB activity occurs in nephrotoxicity models induced by various agents. Kalayarasan et al. [48] found that induced gentamicin induced a significant increase in renal NF-κB levels in rats. Likewise, Zhao et al. [49] found that ACR-induced neurotoxicity increased NF-κB activation significantly compared to controls. In our study, renal NF-κB activation in ACR-treated rats was significantly higher than in controls. On the other hand, in agreement with the literature [50], we found that Se administration, especially in high doses, inhibits inflammation by suppressing the activation of the NF-κB.

Studies have shown that COX-2 is potentially effective in ACR carcinogenicity. NF-κB is a key transcription factor in the regulation of COX-2 expression. ACR administration increases NF-κB expression and consequently induces COX-2 expression [51]. Studies have reported that COX-2 levels in the cerebral cortex [52], liver, and kidney tissues [53] were significantly increased in ACR-treated rats compared to controls, and our results were consistent with these earlier findings. Furthermore, in our study, Se suppressed the ACR-induced increase in COX-2 levels, a finding that has been previously reported [54, 55].

The renal levels of KIM-1 increase dramatically in cases of acute kidney injury [56]. KIM-1 levels have been found to be significantly increased in chemically induced renal toxicity models compared to the control groups [57]. In agreement with these reports, we noted that ACR caused kidney damage and KIM-1 levels increased significantly. In a study, it has determined that Se prevents renal oxidation and inflammation and therefore significantly reduces the level of KIM-1 [58]. In our study, Se application in ACR-induced renal toxicity significantly suppressed the increase in KIM-1 level.

The MAPK pathway regulates different cellular activities such as cell proliferation, differentiation, apoptosis, and inflammation [59]. MAPK-mediated apoptosis and cell death are associated with activation of the JNK and p38 pathways, which are activated by cellular stress [60, 61]. In our study, it was observed that ACR induced a renal oxidative stress and elevated the renal MAPK1 levels. Se administration was found to inhibit both oxidative stress and MAPK1 expression.

Caspase-3 is a key protease that is activated in the early stages of apoptosis [62]. Caspase-3 expression is significantly increased in the sciatic nerves and spinal cord of ACR-treated rats [63]. In another study, liver caspase-3 expression was significantly increased in ACR-induced hepatotoxicity [64]. The findings of our study are similar to that of the literature in that ACR significantly increased renal caspase-3 expression and stimulated apoptosis. The effects of selenium as an antioxidant have been investigated in various studies, and it has been reported that it can reduce cellular degradation factor including caspase-3 [65]. In particular, we determined that high doses of Se inhibit caspase-3 activity, and thus, Se has anti-apoptotic effect.

Studies have shown that ACR toxicity results in Bowman's capsule enlargement, tubular dilation, leukocyte infiltration, and vascular congestion between tubules and glomerulus fragments [16, 66]. In this study, we found that ACR caused severe degeneration and necrosis in the renal tubular epithelium, and severe hyperemia in the interstitial and glomerular vessels; high doses of Se prevented these pathologies significantly and Se on its own had no toxic effects on the kidneys. ACR application significantly increases renal 8-OHdG [67] and Bax [63] expression, which is in line with our results. 8-OHdG is the most important indicator of DNA damage [68], and DNA damage was diminished following the administration of some antioxidants in organ toxicity models [69]. This supports the current study finding. We have determined in a similarly that Se, a strong antioxidant, reduced to renal oxidative stress and 8-OHdG levels and so prevented to DNA damage. Bax is a member of the Bcl-2 gene family and promotes cell apoptosis. We hypothesize that the antioxidant effects of Se reduces renal damage caused by ACR and inhibits to be formed of cell apoptosis at a certain degree. In our study, we determined in accordance with the literature [70] that Se has an anti-apoptotic effect and decreased the level of Bax.

In conclusion, it was determined that ACR induced nephrotoxicity in rats by stimulating oxidative stress, inflammation, apoptosis, and DNA damage. Conversely, high doses of Se suppressed this nephrotoxicity with antioxidant, anti-inflammatory, anti-apoptotic, and genoprotective effects.

Funding Information This research was supported by the Atatürk University Scientific Research Projects Coordinator (Project No: 2019/7021).

Compliance with Ethical Standards

Conflict of Interest The authors declare that they have no conflict of interests.

Ethical Approval This study was approved by the Atatürk University Rectorate Animal Experiments Local Ethics Committee (Ethics code: 2018/205).

References

1. Riboldi BP, Vinhas AM, Moreira JD (2014) Risks of dietary acrylamide exposure: a systematic review. Food Chem 157:310–322

2. Tepe Y, Çebi A (2019) Acrylamide in environmental water: a review on sources, exposure, and public health risks. Exposure Health 11(1):3–12
3. Yerlikaya FH, Toker A, Yener Y (2013) Effects of acrylamide treatment on oxidant and antioxidant levels in rats. Kafkas Univ Vet Fak Derg 19(4):607–612
4. Kjuus H, Hansteen IL, Ryberg D, Goffeng LO, Øvrebø S, Skaug V (2005) Chromosome aberrations in tunnel workers exposed to acrylamide and N-methylolacrylamide. Scand J Work Environ Health 31(4):300–306
5. Schettgen T, Weiss T, Drexler H, Angerer J (2003) A first approach to estimate the internal exposure to acrylamide in smoking and non-smoking adults from Germany. Int J Hyg Environ Health 206(1):9–14
6. Rydberg P, Eriksson S, Tareke E, Karlsson P, Ehrenberg L, Törnqvist M (2003) A first approach to estimate the internal exposure to acrylamide in smoking and non-smoking adults froand. Food Chem 51(24):7012–7018
7. Becalski A, Lau BPY, Lewis D, Seaman SW (2003) Acrylamide in foods: occurrence, sources, and modeling. J Agric Food Chem 51(3):802–808
8. Dortaj H, Anvari M, Yadegari M, Hosseini Sharifabad M, Abbasi Sarcheshmeh A (2017) Stereological survey of the effect of vitamin C on neonatal rat kidney tissue treated with acrylamide. Mod Med Lab J 1(2):42–49
9. Bortolomeazzi R, Munari M, Anese M, Verardo G (2012) Rapid mixed mode solid phase extraction method for the determination of acrylamide in roasted coffee by HPLC–MS/MS. Food Chem 135: 2687–2693
10. Brunton NP, Gormley R, Butler F et al (2007) A survey of acrylamide precursors in Irish ware potatoes and acrylamide levels in French fries. Food Sci Technol 40:1601–1609
11. Santhanasabapathy R, Vasudevan S, Anupriya K, Pabitha R, Sudhandiran G (2015) Farnesol quells oxidative stress, reactive gliosis and inflammation during acrylamide-induced neurotoxicity: behavioral and biochemical evidence. Neuroscience 308:212–227
12. Totani N, Yawata M, Ojiri Y, Fujioka Y (2007) Effects of trace acrylamide intake in Wistar rats. J Oleo Sci 56:501–516
13. Mansour MK, Ibrahim EM, El-Kholy MM, El-Madawy SA (2008) Antioxidant and histopathological effect of catechin and neem leaves extract in acrylamide toxicity of rats. Egypt J Comp and Clinic Pathol 21:290–313
14. Abdel-Daim MM, Abd Eldaim MA, Hassan AG (2014) Trigonella foenum-graecum ameliorates acrylamide-induced toxicity in rats: roles of oxidative stress, proinflammatory cytokines, and DNA damage. Biochem Cell Biol 93(3):192–198
15. Rajeh NA, Al-Dhaheri NM (2017) Antioxidant effect of vitamin E and 5aminosalicylic acid on acrylamide induced kidney injury in rats. Saudi Med J 38(2):132–137
16. Ghorbel I, Elwej A, Fendri N, Mnif H, Jamoussi K, Boudawara T, Grati Kamoun N, Zeghal N (2016) Olive oil abrogates acrylamide induced nephrotoxicity by modulating biochemical and histological changes in rats. Ren Fail 39(1):236–245
17. Atef H, Attia GM, Rezk HM, El-Shafey M (2017) Effect of vitamin E on biochemical and ultrastructural changes in acrylamide-induced renal toxicity in rats. Int J Sci Rep 3(5):134–143
18. Wan H, Zhu Y, Chen P, Wang Y, Hao P, Cheng Z et al (2017) Effect of various selenium doses on chromium (IV)-induced nephrotoxicity in a male chicken model. Chemosphere 174:306–314
19. Kamel KM, Fawzy HM, Metwally SA, El-Latif HAA, El-sayed ME (2015) Protective effects of onion oil and selenium against cisplatin-induced nephrotoxicity and oxidative stress in rats. Egypt J Hosp Med 58:18–25
20. Gunes S, Sahinturk V, Uslu S, Ayhanci A, Kacar S, Uyar R (2018) Protective effects of selenium on cyclophosphamide-induced oxidative stress and kidney injury. Biol Trace Elem Res 185(1): 116–123
21. Liu L, Yang B, Cheng Y, Lin H (2015) Ameliorative effects of selenium on cadmium-induced oxidative stress and endoplasmic reticulum stress in the chicken kidney. Biol Trace Elem Res 167(2):308–319
22. Soudani N, Troudi A, Bouaziz H, Ben Amara I, Boudawara T, Zeghal N (2011) Cardioprotective effects of selenium on chromium (VI)-induced toxicity in female rats. Ecotoxicol Environ Saf 74: 513–520
23. Tyszka-Czochara M, Pasko P, Zagrodzki P, Gajdzik E, Wietecha-Posluszny R, Gorinstein S (2016) Selenium supplementation of amaranth sprouts influences betacyanin content and improves anti-inflammatory properties via NFκB in murine RAW 264.7 macrophages. Biol Trace Elem Res 169(2):320–330
24. El-Ghazaly MA, Fadel N, Rashed E, El-Batal A, Kenawy SA (2016) Anti-inflammatory effect of selenium nanoparticles on the inflammation induced in irradiated rats. Can J Physiol Pharmacol 95(2):101–110
25. Kim Y, Kim DC, Cho ES, Ko SO, Kwon WY, Suh GJ, Shin HK (2014) Antioxidant and anti-inflammatory effects of selenium in oral buccal mucosa and small intestinal mucosa during intestinal ischemia-reperfusion injury. J Inflamm 11(1):36
26. Demirci K, Nazıroğlu M, Övey İS, Balaban H (2017) Selenium attenuates apoptosis, inflammation and oxidative stress in the blood and brain of aged rats with scopolamine-induced dementia. Metab Brain Dis 32(2):321–329
27. Jin X, Xu Z, Zhao X, Chen M, Xu S (2017) The antagonistic effect of selenium on lead-induced apoptosis via mitochondrial dynamics pathway in the chicken kidney. Chemosphere 180:259–266
28. Balaban H, Nazıroğlu M, Demirci K, Övey İS (2017) The protective role of selenium on scopolamine-induced memory impairment, oxidative stress, and apoptosis in aged rats: the involvement of TRPM2 and TRPV1 channels. Mol Neurobiol 54(4):2852–2868
29. Uthra C, Shrivastava S, Jaswal A, Sinha N, Reshi MS, Shukla S (2017) Therapeutic potential of quercetin against acrylamide induced toxicity in rats. Biomed Pharmacother 86:705–714
30. Sengul E, Gelen SU, Yıldırım S, Çelebi F, Çınar A (2019) Probiotic bacteria attenuates cisplatin-induced nephrotoxicity through modulation of oxidative stress, inflammation and apoptosis in rats. Asian Pac J Trop Biomed 9(3):116
31. Gelen V, Şengül E, Gedikli S, Gür C, Özkanlar S (2017) Therapeutic effect of quercetin on renal function and tissue damage in the obesity induced rats. Biomed Pharmacother 89:524–528
32. Mahgoub E, Kumaraswamy SM, Kader KH, Venkataraman B, Ojha S, Adeghate E, Rajesh M (2017) Genipin attenuates cisplatin-induced nephrotoxicity by counteracting oxidative stress, inflammation, and apoptosis. Biomed Pharmacother 93:1083–1097
33. Morel G, Ban M, Bonnet P, Zissu D, Brondeau MT (2005) Effect of β-naphthoflavone and phenobarbital on the nephrotoxicity of chlorotrifluoroethylene and 1, 1-dichloro-2, 2-difluoroethylene in the rat. J Appl Toxicol 25:153–165
34. Gelen V, Sengul E, Yildirim S, Atila G (2018) The protective effects of naringin against 5-fluorouracil-induced hepatotoxicity and nephrotoxicity in rats. Iran J Basic Med Sci 21:404–410
35. Hagiwara S, Koga H, Iwasaka H, Kudo K, Hasegawa A, Kusaka J, Yokoi I, Noguchi T (2011) ETS-GS, a new antioxidant, ameliorates renal ischemia-reperfusion injury in a rodent model. J Surg Res 171:226–233
36. Kara A, Gedikli S, Sengul E, Gelen V, Ozkanlar S (2016) Oxidative stress and autophagy, 1st edn. InTechOpen, Free Radicals and Diseases, London, pp 69–86
37. Elhelaly AE, AlBasher G, Alfarraj S, Almeer R, Bahbah EI, Fouda MM et al (2019) Protective effects of hesperidin and diosmin against acrylamide-induced liver, kidney, and brain oxidative damage in rats. Environ Sci Pollut Res Int 26(34):1–12

38. Soudani N, Sefi M, Amara IB, Boudawara T, Zeghal N (2010) Protective effects of selenium (Se) on chromium (VI) induced nephrotoxicity in adult rats. Ecotoxicol Environ Saf 73(4):671–678
39. El-Boshy ME, Risha EF, Abdelhamid FM, Mubarak MS, Hadda TB (2015) Protective effects of selenium against cadmium induced hematological disturbances, immunosuppressive, oxidative stress and hepatorenal damage in rats. J Trace Elem Med Biol 29:104–110
40. Gan L, Liu Q, Xu HB, Zhu YS, Yang XL (2002) Effects of selenium overexposure on glutathione peroxidase and thioredoxin reductase gene expressions and activities. Biol Trace Elem Res 89(2): 165–175
41. Ikram N, Khalid H, Samina T (2004) Review article cytokines. Int J Pathol 1:47–58
42. Moussion C, Ortega N, Girard J-P (2008) The IL-1-like cytokine IL-33 is constitutively expressed in the nucleus of endothelial cells and epithelial cells in vivo: a novel 'alarmin'? PLoS One 3:e3331
43. Lamkanfi M, Dixit VM (2009) IL-33 raises alarm. Immunity 31: 5–7
44. Ghorbel I, Maktouf S, Kallel C, Chaabouni SE, Boudawara T, Zeghal N (2015) Disruption of erythrocyte antioxidant defense system, hematological parameters, induction of pro-inflammatory cytokines and DNA damage in liver of co-exposed rats to aluminium and acrylamide. Chem Biol Interact 236:31–40
45. Kandemir FM, Kucukler S, Eldutar E, Caglayan C, Gülçin I (2017) Chrysin protects rat kidney from paracetamol-induced oxidative stress, inflammation, apoptosis, and autophagy: a multi-biomarker approach. Sci Pharm 85(1):4
46. Zhou X, Wang Z, Chen J, Wang W, Song D, Li S, Chen C (2014) Increased levels of IL-6, IL-1β, and TNF-α in Kashin–Beck disease and rats induced by T-2 toxin and selenium deficiency. Rheumatol Int 34(7):995–1004
47. Kopp EB, Ghosh S (1995) NF-κB and rel proteins in innate immunity. Adv Immunol 58:1–27
48. Kalayarasan S, Prabhu PN, Sriram N, Manikandan R, Arumugam M, Sudhandiran G (2009) Diallyl sulfide enhances antioxidants and inhibits inflammation through the activation of Nrf2 against gentamicin-induced nephrotoxicity in Wistar rats. Eur J Pharmacol 606(1–3):162–171
49. Zhao M, Wang FSL, Hu XS, Chen F, Chan HM (2017) Effect of acrylamide-induced neurotoxicity in a primary astrocytes/microglial co-culture model. Toxicol in Vitro 39:119–125
50. Bi CL, Wang H, Wang YJ, Sun J, Dong JS, Meng X, Li JJ (2016) Selenium inhibits Staphylococcus aureus-induced inflammation by suppressing the activation of the NF-κB and MAPK signalling pathways in RAW264. 7 macrophages. Eur J Pharmacol 780: 159–165
51. Lim TG, Lee BK, Kwon JY, Jung SK, Lee KW (2011) Acrylamide up-regulates cyclooxygenase-2 expression through the MEK/ERK signaling pathway in mouse epidermal cells. Food Chem Toxicol 49(6):1249–1254
52. He Y, Tan D, Mi Y, Zhou Q, Ji S (2017) Epigallocatechin-3-gallate attenuates cerebral cortex damage and promotes brain regeneration in acrylamide-treated rats. Food Funct 8(6):2275–2282
53. Wang D, Qi J, Pan X, Yan D, Yan H (2016) The antagonistic effect and mechanism of N-acetylcysteine on acrylamide-induced hepatic and renal toxicity. Zhonghua Lao Dong Wei Sheng Zhi Ye Bing Za Zhi 34(1):13–17
54. Saif-Elnasr M, Abdel-Aziz N, El-Batal AI (2019) Ameliorative effect of selenium nanoparticles and fish oil on cisplatin and gamma irradiation-induced nephrotoxicity in male albino rats. Drug Chem Toxicol 42(1):94–103
55. Khalaf AA, Ahmed WMS, Moselhy WA, Abdel-Halim BR, Ibrahim MA (2019) Protective effects of selenium and nano-selenium on bisphenol-induced reproductive toxicity in male rats. Hum Exp Toxicol 38(4):398–408
56. Bonventre JV, Yang L (2010) Kidney injury molecule-1. Curr Opin Crit Care 16(6):556–561
57. Kim KS, Lim HJ, Lim JS, Son JY, Lee J, Lee BM, Chang SC, Kim HS (2018) Curcumin ameliorates cadmium-induced nephrotoxicity in Sprague-Dawley rats. Food Chem Toxicol 114:34–40
58. Shanu A, Groebler L, Kim HB, Wood S, Weekley CM, Aitken JB, Harris HH, Witting PK (2013) Selenium inhibits renal oxidation and inflammation but not acute kidney injury in an animal model of rhabdomyolysis. Antioxid Redox Signal 18(7):756–769
59. Kim EK, Choi EJ (2015) Compromised MAPK signaling in human diseases: an update. Arch Toxicol 89(6):867–882
60. Liu J, Chang F, Li F, Fu H, Wang J, Zhang S, Zhao J, Yin D (2015) Palmitate promotes autophagy and apoptosis through ROS-dependent JNK and p38 MAPK. Biochem Biophys Res Commun 463(3):262–267
61. Sui X, Kong N, Ye L, Han W, Zhou J, Zhang Q, He C, Pan H (2014) p38 and JNK MAPK pathways control the balance of apoptosis and autophagy in response to chemotherapeutic agents. Cancer Lett 344(2):174–179
62. Yang GS, Wang W, Wang YM, Chen ZD, Wang S, Fang JJ (2006) Effect of cocaine on germ cell apoptosis in rats at different ages. Asian J Androl 8(5):569–575
63. Li SX, Cui N, Zhang CL, Zhao XL, Yu SF, Xie KQ (2006) Effect of subchronic exposure to acrylamide induced on the expression of bcl-2, bax and caspase-3 in the rat nervous system. Toxicology 217(1):46–53
64. Seydi E, Rajabi M, Salimi A, Pourahmad J (2015) Involvement of mitochondrial-mediated caspase-3 activation and lysosomal labilization in acrylamide-induced liver toxicity. Toxicol Environ Chem 97(5):563–575
65. Ren H, Mu J, Ma J, Gong J, Li J, Wang J, Gao T, Zhu P, Zheng S, Xie J, Yuan B (2016) Selenium in-hibits homocysteine-induced endothelial dysfunction and apopto-sis via activation of AKT. Cell Physiol Biochem 38(3):871–882
66. Ghorbel I, Maktouf S, Fendri N, Jamoussi K, Ellouze Chaabouni S, Boudawara T, Zeghal N (2016) Co-exposure to aluminum and acrylamide disturbs expression of metallothionein, proinflammatory cytokines and induces genotoxicity: biochemical and histopathological changes in the kidney of adult rats. Environ Toxicol 31(9): 1044–1058
67. Alturfan AA, Tozan-Beceren A, Şehirli AÖ, Demiralp E, Şener G, Omurtag GZ (2012) Resveratrol ameliorates oxidative DNA damage and protects against acrylamide-induced oxidative stress in rats. Mol Biol Rep 39(4):4589–4596
68. Stepniak J, Karbownik-Lewinska M (2016) 17 β-estradiol prevents experimentally-induced oxidative damage to membrane lipids and nuclear DNA in porcine ovary. Syst Biol Reprod Med 62:17–21
69. Ince S, Arslan Acaroz D, Neuwirth O, Hasan Hüseyin D, Barıs D, İsmail K et al (2014) Protective effect of polydatin, a natural precursor of resveratrol, against cisplatin induced toxicity in rats. Food Chem Toxicol 72:147–153
70. Yang SY, Zhang L, Miao KK, Qian W, Zhang ZG (2013) Effects of selenium intervention on chronic fluorosis-induced renal cell apoptosis in rats. Biol Trace Elem Res 153(1–3):237–242

Publisher's Note Springer Nature remains neutral with regard to jurisdictional claims in published maps and institutional affiliations.