ePublishing

ΕΘΝΙΚΟ ΚΕΝΤΡΟ ΤΕΚΜΗΡΙΩΣΗΣ
EKT
NATIONAL DOCUMENTATION CENTRE

Journal of the Hellenic Veterinary Medical Society

Vol 70, No 1 (2019)



Perivulvar squamous cell carcinoma in a cow

H. ORAL, E. BEYTUT, M. KURU, E. KARAKURT, M. C. DEMIR, İ. ÖZAYDIN

doi: 10.12681/jhvms.20354

Copyright © 2019, H. ORAL, E. BEYTUT, M. KURU, E. KARAKURT, M. C. DEMIR, İ. ÖZAYDIN

This work is licensed under a Creative Commons Attribution-NonCommercial 4.0.

To cite this article:

ORAL, H., BEYTUT, E., KURU, M., KARAKURT, E., DEMIR, M. C., & ÖZAYDIN, İ. (2019). Perivulvar squamous cell carcinoma in a cow. *Journal of the Hellenic Veterinary Medical Society*, *70*(1), 1449–1454. https://doi.org/10.12681/jhvms.20354

https://epublishing.ekt.gr | **e-Publisher:** EKT | **Downloaded at:** 12/10/2026 00:17:09

J HELLENIC VET MED SOC 2019, 70(1): 1449-1454
2019, 70(1): 1449-1454

Case report
Κλινικό περιστατικό

Perivulvar squamous cell carcinoma in a cow

H. Oral [1], E. Beytut [2], M. Kuru [1]*, E. Karakurt [2], MC. Demir [1], İ. Özaydın[3]

[1]*Department of Obstetrics and Gynecology, Faculty of Veterinary Medicine, Kafkas University, Kars, Turkey*

[2]*Department of Pathology, Faculty of Veterinary Medicine, Kafkas University, Kars, Turkey*

[3]*Department of Surgery, Faculty of Veterinary Medicine, Kafkas University, Kars, Turkey*

ABSTRACT. We present a case of perivulvar squamous cell carcinoma in an 8-year-old crossbred Simmental cow. A tumoral mass, of considerably large volume localized in the perivulvar region and growing at a slow pace, was detected in the animal. The mass, subsequently identified histopathologically and immunohistochemically as squamous cell carcinoma, was surgically excised from the perivulvar region using intrathecal anesthesia.

Keywords: cow, spinal anesthesia, vulva, squamous cell carcinoma.

Corresponding Author:
Mushap Kuru, Department of Obstetrics and Gynecology, Faculty of Veterinary Medicine, University of Kafkas, Paşaçayırı Campus,
TR-36100, Kars, Turkey,
Email address: mushapkuru@hotmail.com

Date of initial submission: 09-04-2018
Date of revised submission: 09-04-2018
Date of acceptance: 09-04-2018

INTRODUCTION

Vaginal malignant tumors are uncommon; however, recurring squamous cell carcinomas in the vulva are frequently encountered (Khodakaram-Tafti et al., 2013). Squamous cell carcinomas originating from stratum spinosum cells are mainly seen in adult cows, sheep, and mares. While this tumor is observed in various parts of the body, it is typically located in non-pigmented and hairless regions. Prolonged exposure to ultraviolet rays is considered an important factor related to tumor formation (Erer and Kıran, 2005; Hillman and Gilbert, 2008; Khodakaram-Tafti et al., 2013; McEntee, 1990; Pimenta-Oliveira, 2011). Squamous cell carcinoma, which has an aggressive character, may infiltrate locally or metastasize if not diagnosed in the early stage (Hillman and Gilbert, 2008). Clinically, it may have a productive or erosive character. The productive type may reportedly be cauliflower-like in appearance, and there may be bleeding and ulceration present on the surface (Agnew and MacLachlan, 1990; Erer and Kıran, 2005; McEntee, 1990).

Squamous cell carcinoma of the vulva has typically been reported in cattle, sheep, goats, and sometimes other mammalian species (Khodakaram-Tafti et al., 2013; McEntee, 1990). Tumors of vaginal origin are detected particularly during colposcopy or artificial insemination procedures (Hillman and Gilbert, 2008; Meyers and Read, 1990). Squamous cell carcinoma was observed in 0.44% of 7483 cattle during necropsy, and in 4.97% of tumor-detected cases (Rosa et al., 2012). Yeruham et al., (1999) reported vulvar squamous cell carcinoma detection at a rate of 0.91% in dairy cattle and 0.38% in beef cattle. In Turkey there are a limited number of reports regarding vulvar squamous cell carcinoma in cattle (Alaçam et al., 1981; Öcal et al., 1995).

Early diagnosis increases the possibility of success in the treatment of squamous cell carcinoma of the vulva. In such cases, the treatment of choice is cryotherapy and wide surgical excision (Hillman and Gilbert, 2008; McEntee, 1990).

Here we aimed to present pathological findings of perivulvar squamous cell carcinoma diagnosed in a crossbred Simmental cow and to describe surgical removal of the tumor using intrathecal anesthesia.

CASE HISTORY

The present case involves an 8-year-old crossbred Simmental cow which had given birth for the fifth time one month prior. The clinical history revealed that the cow had a normal delivery during which a mass with a diameter approximately 3-4 cm was noticed on the right side of the vulva. The mass had increased within 1 month following the delivery (roughly 10 cm) and would occasionally bleed.

During a clinical examination of the animal by the Obstetrics and Gynecology Clinic of Kafkas University Veterinary Faculty, a bleeding and necrotic in some regions, ulcerated multi-nodular mass was detected on the right side of the vulva (Figure 1). No diseases or symptoms other than the mass were observed. Upon the rectal palpation, the uterus and ovaries were determined to be normal. Based on the clinical evaluation, a decision was made to remove the mass surgically using the spinal (intrathecal) anesthesia Bupivacaine (0.5%, Marcaine®, 5 mg/mL, Astra Zenaca) via a 20 gauge spinal needle for subdural injection.

Figure 1: Large tumor mass on the vulva with ulcer, bleeding, and necrosis.



The animal was placed on a Hannover carriage in the right lateral position and immobilized appropriately to prevent cranial extension of the anesthetic agent during injection. After shaving and antisepsis of the lumbosacral region, a spinal needle was extended vertically until it passed the

ligamentum flavum through the lumbosacral space. After noting that it touched the dura mater, the needle was pushed slightly forward to enter the subdural space. The flow of cerebrospinal fluid (CSF) was observed by removing the stylet from the spinal needle. A certain amount of CSF was aspirated to avoid a pressure increase as a result of the local anesthetic to be injected. A volume of 10 mL of bupivacaine, previously loaded into an injector, was slowly introduced into the spinal cord. Once anesthesia of the tail and vulva area was achieved, the mass was removed from the perivulvar area following a routine surgical procedure with bleeding controlled by electrocautery. Routine parenteral fluid infusion (Lactated Ringers) throughout the operation and postoperative antibiotic administration was performed.

The excised mass was measured 15x10x20 cm and exhibited ulcers and bleeding at the surface. When the mass was cross-sectioned, multiple small and hard greyish nodules with a cauliflower appearance on the cut surface were noticed. Since the animal's owner rejected euthanasia, an examination of both carcass and regional lymph nodes could not be performed, and therefore the presence of metastasis in internal organs could not be evaluated.

The mass was sent to the Department of Pathology for histopathological examination. Tissue samples taken from the mass were fixed in 10% buffered formalin solution. Routinely prepared paraffin blocks were cut to 5 μm thickness, stained with hematoxylin and eosin, and evaluated by light microscopy. For immunoperoxidase staining, serial sections 4 um in thickness were deparaffinized in xylene and hydrated through grading alcohols. The sections were incubated in 3% H_2O_2 for 20 min at room temperature to block endogenous peroxidase activity. After the sections were washed for 5 min in Tris buffered saline (TBS), they were boiled in citrate buffer saline (pH 6.0) for 20 min in a microwave oven to induce antigen release. All sections were stained with Genemed Acu-Stain Mouse+Rabbit HRP Instant Kits using mouse monoclonal Ki-67 (Genemed, Clone; GM010), mouse monoclonal anti-p53 (Biorbyt, Clone; SPM590) and mouse monoclonal anti-cytokeratin (Thermo Scientific, Clone; DE-SQ) primer antibodies according to the manufacturers' instructions. For immunolabeling, 3,3'-diaminobenzidine (DAB) was used as the chromogen. Mayer's hematoxylin was used as the counterstain. Negative control sections were incubated with TBS instead of the primer antibodies.

Histopathologically, the tumor mass was diagnosed as squamous cell carcinoma. Neoplastic cells showed often nuclear pleomorphism. The cells had an eosinophilic cytoplasm with considerably large, hyperchromatic, and ovoid nuclei, with at least 2-3 nucleoli. Neoplastic proliferation revealed frequently keratin pearls consisting of laminated keratin structures (Figure 2). Keratin pearls were not seen in all of the tumor islands, and a small number of tumor cells showed immature keratinization within the cytoplasm. In particular, in some areas close to the surface of the mass, diffuse and severe neutrophilic infiltration along with bacterial clusters, necrosis, and thrombi were observed. Interestingly, eosinophil leukocyte infiltrations were commonly seen in the mass. Pleomorphic tumor cells showed frequent mitotic figures numbering 7-10 on a microscopic field of high magnification (40x) (Figure 3). Tumor cells spread into the dermis in some areas, and in some regions of the mass, neoplastic proliferations were supported by delicate stromal tissue.

Figure 2: Characteristic keratin pearl in tumor tissue and neoplastic cells with considerably large nuclei, (H&E x 20).

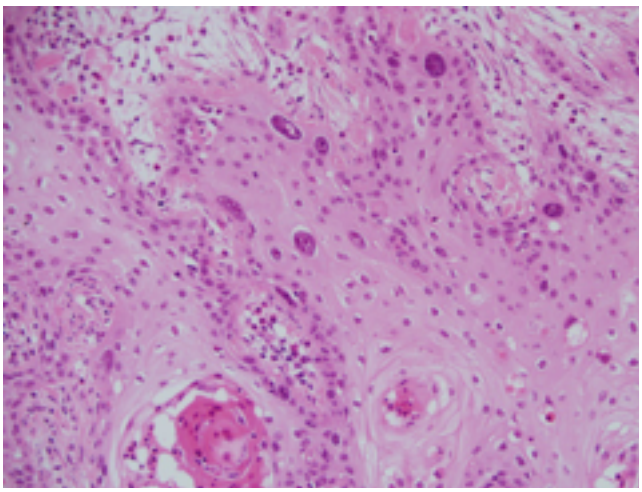

Immunohistochemically, a severe cytoplasmic positive reaction of neoplastic cells for cytokeratin was observed in the entire tumor tissue. But there was

Figure 3: Mitotic figures (arrows) in the tumor tissue (H&E x40), (arrows)(H&E4.)

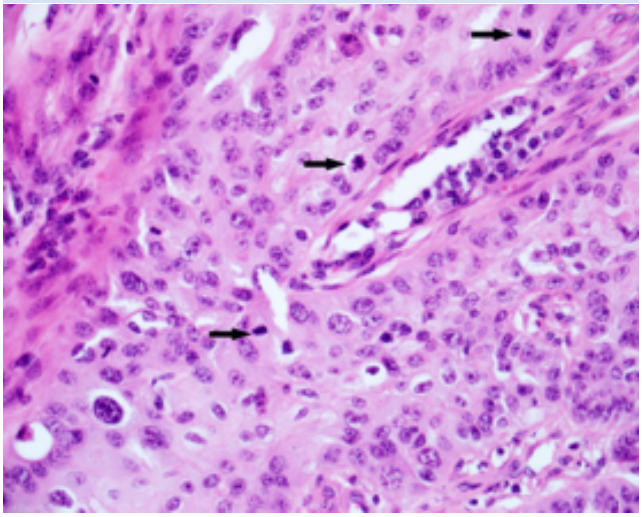

no reaction in the stromal tissue. (Figure 4). Immune reaction products appeared to be fine granular and more intense in the areas adjacent to the cellular

Figure 4: Intense cytoplasmic positive reaction (ABCx10).

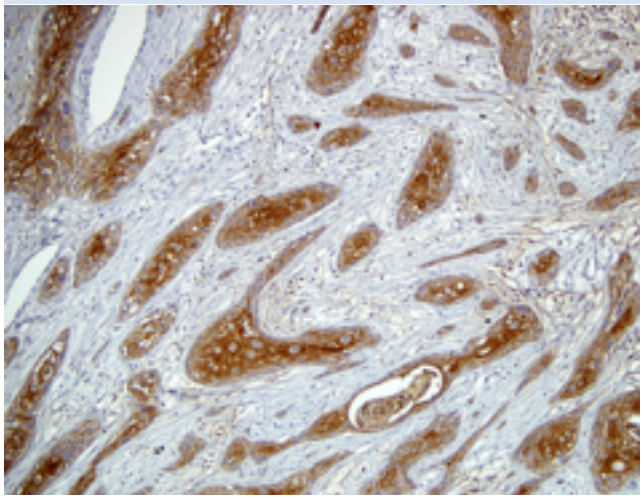

membrane, with no staining of desmosomes. In addition to the tumor cells, a cytokeratin-positive reaction was also detected in the keratin pearls. Ki-67 staining revealed tumor cells with nuclear positive labelling. Positive staining was also found in the nuclei of hyperchromatic cells and in cells undergoing mitosis (Figure 5). In the large neoplastic cells, nuclear staining spread to the whole nuclei in the form of particles. Additionally, Ki-67 nuclear-positive labelling was observed in a small number of germinative cells of the epidermal layer.

Figure 5: Ki67 nuclear positive reaction in tumor cells (ABC x 40)

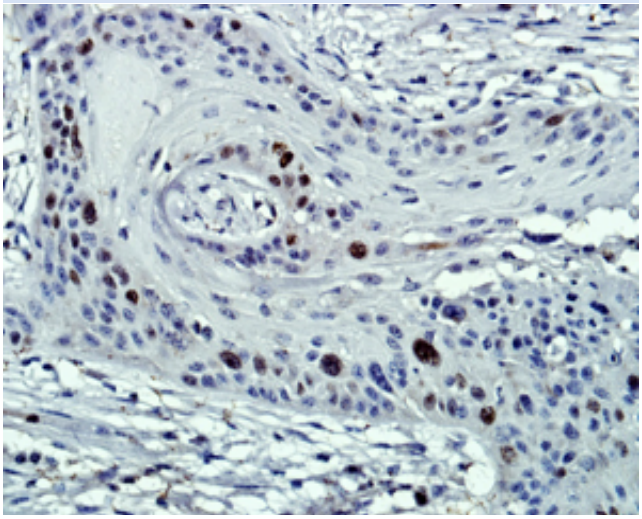

DISCUSSION

Tumors such as squamous cell tumors, leiomyoma, fibroma, fibro-papilloma, hemangioma, fibrosarcoma, leiomyosarcoma, and melanoma can be located in the vulva and vagina of cattle (Kuru et al., 2016; Yeruham et al., 1999). Squamous cell tumors can be found especially in pigment-free regions of the body, and are more frequently detected in elderly animals (Pandey, et al., 2010; Prasath et al., 2009). In the case presented, it was observed that the mass was only on the right side of the vulva.

Vaginal tumors are typically excised by electrocautery. Small-scale masses can easily be removed with sedation and local anesthesia, while removal of large masses requires more substantial anesthesia (Çolak et al., 1997; Enginler et al., 2011; Kuru et al., 2016). Lower or upper epidural anesthesia is generally preferred for large-scale gynecologic operations in cattle (Hillman and Gilbert, 2008). In this case, the surgical operation was performed with intrathecal anesthesia, and no signs of pain or anesthetic complications were encountered during the intra-operative period.

Khodakaram-Tafti et al., (2013) reported that squamous cell carcinoma produces keratin pearls and has a good level of differentiation, and that this tumor also metastasizes to the nearest lymph node nodules. In the present case, we detected numerous bleeding and necrotic masses; however, the clinical examination revealed the lymph nodes (prefemoral, prescapular

and supramammary) to be of normal size and surface. This situation may be due to the relatively short tumor history. In the literature (Khodakaram-Tafti et al., 2013; Yeruham et al., 1999), it has been suggested that squamous cell carcinomas are highly invasive and metastasize to the lymph nodes. However, since postmortem examination could not be performed on the present case, it was not possible to determine whether the tumor had metastasized to surrounding tissues and organs.

Histopathological and immunohistochemical studies revealed that the microscopic findings generally corresponded with the literature data, and the determination that the tumor was a squamous cell carcinoma. Epithelial proliferative foci and keratin pearls in the form of submucosal islets and cords in the neoplastic epithelial cells of this squamous cell carcinoma have also been described by other authors (Devi et al., 2010; Pimenta-Oliveira et al., 2011). Likewise, keratinization is generally seen in tumor cell foci and in individual cells. The formation of loose connective tissue which were widely observed in the tissue of the tumor have been described as desmoplasia/stromal fibroplasia in the literature and it has been suggested that they are important in the diagnosis of invasive carcinomas. The tumor parenchyma supported by fibrotic tissue in the present case supports this theory. Ulceration, necrosis, and inflammatory cell infiltration that are commonly seen in the tumoral tissue are explained by ulceration and contamination of the surface of the mass (Devi et al., 2010; Khodakaram-Tafti et al., 2013; Pimenta-Oliveira et al., 2011). In the presented case, tumor tissue was stained using the immunoperoxidase technique with cytokeratin and Ki67 markers. The cytokeratins are considered to be the largest intermediate filaments of squamous epithelium and are critically important for the stabilization, shape, intracellular communication and transport within the cell. Therefore, cytokeratin expression is of considerable importance in tumor progression (Frohwitter et al., 2016). Based on cytokeratin immunostaining, all of the tumor parenchyma and squamous mucosal epithelial cells were identified as having positive cytoplasmic staining, and the tumor was confirmed to be of epithelial origin. Similarly, in some studies (Devi et al., 2010; Vala et al., 2001), pervasive positive cytokeratin staining of tumor cells has been observed for ocular squamous cell carcinomas in cattle. The importance of cytokeratin staining for the identification and differentiation of tumor origins has been emphasized. Neoplastic cells in the tumor tissue were also observed to be nuclear positive for the Ki67 protein. As stated by Pimenta-Oliveira et al. (2011), frequent mitoses together with nuclear pleomorphism and desmoplasia are indicative of a poor prognosis.

In conclusion, based on characteristic histological features, the neoplasm was diagnosed as a vulvar squamous cell carcinoma. The importance of early diagnosis and treatment is emphasized, as a good prognosis is possible if the mass is surgically removed in the early phase of the disease. In addition, an intrathecal anesthetic protocol can be successfully utilized for the surgical intervention

CONFLICT OF INTEREST

The authors declare no conflict of interest.

REFERENCES

Agnew DW, MacLachlan NJ (2017) Tumors of the genital systems. In: Tumors of Domestic Animals. Wiley Blacwell, Iowa, USA: pp 689-722.

Alaçam E, Metin N, Deveci H, Timurkan H (1981) A case of squamous cell carcinoma of the vulva in a cow. Fırat Üniv Sağ Bil Derg 6: 80-84.

Çolak A, Sağlam YS, Kamiloğlu A, Karaman M (1997) Bir inekte rastladığımız vaginal tümör olgusu. Kafkas Univ Vet Fak Derg 3: 93-96.

Devi VR, Veeraiah G, Annapurna P, Estheru S (2010) Squamous cell carcinoma of ear in an Indian Buffalo (Bubalus bubalus). Braz J Vet Path 3: 60-62.

Enginler SO, Gunduz MC, Sabuncu A, Senunver A, Yildiz F, Arun SS (2011) Vaginal leiomyosarcoma in a Holstein cow. Kafkas Univ Vet Fak Derg 17: 325-327.

Erer H, Kıran MM (2005) Veteriner Onkoloji. Damla Ofset, Konya, Turkey.

Frohwitter G, Buerger H, Van Diest PJ, Korsching E, Kleinheinz J, Fillies T (2016) Cytokeratin and protein expression patterns in squamous cell carcinoma of the oral cavity provide evidence for two distinct pathogenetic pathways. Oncology Letters 12: 107-113.

Hillman R, Gilbert RO (2008) Reproductive disease. In: Rebhun's Diseases of Dairy Cattle. Saunders Elsevier, Missouri, USA: pp 395-446.

Khodakaram-Tafti A, Motaghypisheh M, Shirian S (2013) Pathological study of naturally occurring vulvar and vaginal squamous cell carcinoma (SCC) in cattle. Comp Clin Pathol 22: 713-716.

Kuru M, Beytut E, Kaya S, Karakurt E Kaçar C (2016) Vaginal fibrosarcoma in a Brown Swiss cow. Atatürk Üniversitesi Vet Bil Derg 11: 327-331.

McEntee K (1990) Reproductive Pathology of Domestic Mammals. Academic Press Inc., New York, USA.

Meyers SA, Read WK (1990) Squamous cell carcinoma of the vulva in a cow. J Am Vet Med Assoc 196: 1644-1646.

Öcal H, Deveci H, Apaydın AM, Kalkan C, Çetin H, Kaygusuzoğlu E (1995) İnek vulvasında rastlanılan yassı hücreli karsinom olguları. FÜ Sağlık Bil Enst Derg 9: 266-271.

Pandey GS, Chamilunda B, Mumba C (2010) Vulvar squamous cell carcinoma in a Holstein Friesian cross – bred cow in Zambia. Indian J Vet Pathol 34: 185-186.

Pimenta-Oliveira A, Oliveira-Filho JP, Cagnini DQ, Badial PR, Cisneros-Álvarez E, Laufer-Amorim R, Prestes NC (2011) Squamous cell carcinoma in vaginal fundus in a Brahman cow. Arq Bras Med Vet Zootec 63: 749-752.

Prasath NB, Balachandran C, Raman A (2009) Vulvar squamous cell carcinoma in a Holstein Friesian cross bred cow. Indian Vet J 86: 411-412.

Rosa FB, Kommers GD, Lucena RB, Galiza GJN, Tochetto C, Silva TM, Silveira IP (2012) Epidemiological, clinicopathological and immunohistochemical aspects of vulval squamous cell carcinomas in 33 cows. Pesq Vet Bras 32: 1127-1132.

Vala H, Fondevilla D, Carvalho T, Pinto C, Peleteiro C, Pinho M, Ferrer L (2001) Immunohistochemistry studies on bovine squamous cell carcinoma morphological characterization of epidermal cell proliferation and differentiation markers and characterization of cytokeratins. In: 1st International Symposium - Research in Veterinary Science, 24-25 May, Lisboa, Portugal: pp 1-6.

Yeruham I, Perl S, Orgad U, Yakobson B (1999) Tumors of the vulva and vagina in cattle – A 10-year survey. Vet J 158: 237-239.