Environmental Science and Pollution Research (2021) 28:47046–47055
https://doi.org/10.1007/s11356-021-13969-5

RESEARCH ARTICLE

The protective effects of hesperidin and curcumin on 5-fluorouracil–induced nephrotoxicity in mice

Volkan Gelen[1] · Emin Şengül[2] · Serkan Yıldırım[3] · Esra Senturk[4] · Samet Tekin[2] · Abdulsamed Kükürt[5]

Received: 23 December 2020 / Accepted: 12 April 2021 / Published online: 22 April 2021
© The Author(s), under exclusive licence to Springer-Verlag GmbH Germany, part of Springer Nature 2021

Abstract

Nephrotoxicity is a very important complication of 5-fluorouracil (5-FU)–treated cancer patients. Increased oxidative stress, kidney damage, and apoptosis play an important role in the pathogenesis of nephrotoxicity caused by 5-FU. In this study, protective effects of two natural compounds, hesperidin and curcumin, on experimentally induced kidney damage in mice with 5-FU were determined. Application of 5-FU resulted in severe histopathological changes and severe renal failure with increased serum urea and creatinine levels. Also, 5-FU–induced kidney damage, increased levels of malondialdehyde (MDA), decreased superoxide dismutase (SOD), catalase (CAT), glutathione reductase (GR) activity, and glutathione (GSH) level have been demonstrated. Also, where 5-FU is in the concentration of caspase-3 and 8-OHdG immune-positive cells and therefore causes apoptosis and DNA damage in kidney tissue cells. However, especially high doses of hesperidin and curcumin treatment significantly improved 5-FU–induced oxidative stress/lipid peroxidation, apoptosis/DNA damage, and renal dysfunction. Based on these data, our results suggest that hesperidin and curcumin may be used as new and promising agents against 5-FU–induced nephrotoxicity.

Keywords Nephrotoxicity · Apoptosis · Curcumin · Hesperidin · Histopathology · Immunohistochemistry · Mice

Introduction

5-Fluorouracil (5-FU) is a pyrimidine antimetabolite known since 1957 and has been used clinically for the last 40 years. In addition to the antitumor activity of 5-FU, synergism with other anticancer drugs has been used in the treatment of various types of cancer (Miura et al. 2010). When 5-FU is metabolized in the body, the metabolic product 5-fluoro-2-deoxyuridine5-monophosphate (FdUMP) is formed; it inhibits thymidylate synthase, an enzyme necessary for the synthesis of thymine. Thus, it reduces the production of 2′-deoxythymidine-5′-monophosphate (dTMP) which is of great importance for the replication and repair of DNA and causes cell toxicity (Chibber et al. 2011). Besides, the liver is catabolized in dihydrouracil in ammonia, urea, and carbon dioxide, thus causing nephrotoxicity (Nora and Ali 2012). 5-FU is used in the treatment of various types of cancer, including breast cancer, stomach cancer, colorectal cancer, genitourinary system cancer, liver cancer, and skin cancer. In some studies, the use of various chemotherapeutic agents has been reported to cause nephrotoxicity (Abdel-Diam et al. 2019; Gelen et al. 2018). One of these agents 5-FU has been found to hinder the division of normal cells in patients as well as tumors, induce apoptosis, and cause cell death, leading to extensive side effects such as DNA damage (Gelen et al. 2017a, 2017b; Gelen et al. 2018). As with other agents, common clinical side effects caused by 5-FU include cardiotoxicity and hepatotoxicity as well as nephrotoxicity (Sengul et al. 2021a, 2021b; Nora and Ali 2012; David et al. 2011; Chang et al. 2012; Lamberti et al. 2012; Kinhult et al. 2003). Several recent studies have focused on the use of natural compounds

Responsible Editor: Mohamed M. Abdel-Daim

✉ Volkan Gelen
gelen_volkan@hotmail.com

[1] Department of Physiology, Veterinary Faculty, Kafkas University, Kars, Turkey

[2] Department of Physiology, Veterinary Faculty, Ataturk University, Erzurum, Turkey

[3] Department of Pathology, Veterinary Faculty, Ataturk University, Erzurum, Turkey

[4] School of Health Services, Agri Ibrahim Cecen University, Agri, Turkey

[5] Department of Biochemistry, Veterinary Faculty, Kafkas University, Kars, Turkey

that have antioxidative and antiapoptotic effects to reduce or eliminate various organ toxicity caused by chemotherapeutic drugs (Gelen et al. 2017a, 2017b; Gelen et al. 2018; Khan and Sultana 2011; Şengül et al. 2017; Gelen et al. 2019; Gelen and Şengül 2018; Gelen and Şengül 2020). Several recent studies have reported that the consumption of various fruits and vegetables in animal models and humans reduces the risk of cancer because of flavonoids found in the structures (Surh et al. 2001; Middleton Jr et al. 2000). Flavonoids are natural phenolic compounds of plant origin with numerous effects such as antibacterial, anti-inflammatory, anti-allergic, antithrombotic, and antiapoptotic (Bosetti et al. 2007). Today, due to the use of herbal preparations for the prevention of diseases, alternative medicine has received very much attention. Therefore, the biological role of natural phenolics known as the main components of some traditional medicinal plants and the prevention of the damage caused by the application of some chemical agents are becoming more important (Wang and Morris 2007). It is reported that there are antioxidant, anti-inflammatory, and antiapoptotic effects of various plants in hesperidin (H) and curcumin (CUR), which are natural phenolic compounds (Ahmad et al. 2012; Hussein and Othman 2011; Selvaraj and Pugalendi 2012; Suarez et al. 1998; Chanet et al. 2012; Inano et al. 2000; Ammon and Wahl 1991; Farombi et al. 2007). Besides, it has been determined that H and CUR have protective effects against the brain, liver, kidney, and oxidative damage caused by various toxic agents (Abdel-Daim and Abdou 2015; Elhelaly et al. 2019). In line with this information, this study aimed to investigate the nephroprotective effects of H and CUR in the 5-FU–induced experimental nephrotoxicity model in mice.

Materials and methods

Animals

The protocol of this study was approved by the Atatürk University Rectorate Animal Experiments Local Ethics Committee (HADYEK 2019/16). Forty-eight male mice weighing between 20 and 25g were obtained from Atatürk University Medical Experimental Research and Application Center and were housed in a controlled environment (temperature, 24±3 °C and relative humidity, 55±15%) with a 12-h light/dark cycle. During the experimental period, animals were allowed free access to food and water.

Experimental design

In our study, the protective effects of H (25 and 50 mg/kg for 7 days, intraperitoneal) and CUR (100 and 200 mg/kg for 7 days, intraperitoneal) on 5-fluorouracil–induced nephrotoxicity in mice (400 mg/kg, intraperitoneal) were examined. Mice were divided into 6 groups according to their weight, 8 in each group. Experimental groups and application methods of chemicals are as follows:

1. Control: 1 ml propylene glycol (25 ml) + saline (75 ml) was applied for 7 days.
2. 5-FU: Propylene glycol (25 ml) + saline (75 ml) was administered for 7 days. Three doses of 5-FU (400 mg/kg) were administered to the same group from the 4th day of administration.
3. 5-FU+H25: H (25 mg/kg) was administered for 7 days. Three doses of 5-FU (400 mg/kg) were administered to the same group from the 4th day of administration.
4. 5-FU+H50: H (50 mg/kg) was administered for 7 days. Three doses of 5-FU (400 mg/kg) were administered to the same group from the 4th day of administration.
5. 5-FU+CUR100: CUR (100 mg/kg) was administered for 7 days. Three doses of 5-FU (400 mg/kg) were administered to the same group from the 4th day of administration.
6. 5-FU+CUR200: CUR (200 mg/kg) was administered for 7 days. Three doses of 5-FU (400 mg/kg) were administered to the same group from the 4th day of administration.

Renal toxicity markers

At the end of the experiment, serum samples were obtained from blood samples of mice, and kidney damage markers (creatinine and urea) were determined by an autoanalyzer (Klinkhammer et al. 2020).

Oxidative stress markers

At the end of the applications, the abdominal regions of the mice were opened, and the kidney tissues were removed. The kidney tissues taken were weighed in equal proportions and transferred to the Eppendorf tube. Tissue samples were then homogenized, and samples were prepared by centrifugation for experimental protocols. At the end of the experiment, MDA (Placer et al. 1966) and GSH (Sedlak and Lindsay 1968) level, SOD (Sun et al. 1988), CAT (Aebi 1983), and GR (Carlberg and Mannervik 1975) activities were determined by a spectrophotometric method using commercial kits.

Histopathological study

The kidney tissue samples were collected, placed in a 10% formalin solution for 48 h, and then washed under running tap water for histopathological evaluation. The tissue was routinely processed and was then buried in blocks of paraffin. Tissue

sections cut to 4-μm thickness were taken from each block, placed on the slides, stained, and examined under a Leica DM1000 Laboratory Microscope (Leica Microsystems, Buffalo Grove, USA) to perform an accurate assessment of the hematoxylin-eosin. The sections were graded as none (0), mild (1), moderate (2), and severe (3) according to their histopathological findings. Degeneration in the renal tubular epithelium was defined as a degenerated cell number of 0 (none), 1–10 (1), 11–20 (2), and > 20 (3). Necrosis in the renal tubular epithelium was defined as a necrosed cell number of 0 (none), 1–10 (1), 11–20 (2), and >20 (3). Dilatation in the tubular was defined as a dilated tubular number of 0 (none), 1–10 (1), 11–20 (2), and >20 (3). Congestion in the interstitial blood vessels was defined as a vessel number of 0 (none), 1–10 (1), 11–20 (2), and >20 (3) (Sakat et al. 2019).

Immunohistochemical study

All sections taken on an adhesive (poly-L-lysine) slide for immunoperoxidase examination were passed through xylol and alcohol series. After washing the sections with PBS, they were kept in 3% H2O2 for 10 min, and endogenous peroxidase inactivation was achieved. Tissues were treated with antigen recovery solution from 500 watts for 2 × 5 min in a microwave oven to reveal antigen and then allowed to cool. Tissues at 37°C for 30 min 8 OHdG, Caspase-3, (catalog no: sc66036, sc56053 dilution 1/100; Santa Cruz, EU). It was followed according to the immunohistochemistry kit procedure (Abcam HRP/DAB Detection IHC kit). 3-3′-Diaminobenzidine (DAB) was used as chromogen. The mean number of positive cells was calculated to reflect the intensity of positive expression. The sections were graded as none (0), mild (1), moderate (2), and severe (3) according to their immunoreactivity (Sengul et al. 2019; Gelen et al. 2017a, 2017b; Gelen et al. 2018), which was defined as a positive cell number of 0 (none), 1–10 (1), 11–20 (2), and >20 (3) (Yildirim et al. 2019).

Statistical analysis

The results of our study were evaluated statistically. The results were given as X ± SD. The quantitative values were statistically analyzed in SPSS 20.00 statistical data program. Then, one-way ANOVA was evaluated by the Tukey test. $p < 0.05$ was considered significant.

Results

Effects of H and CUR on renal function parameters

Serum urea levels were significantly higher in the 5-FU group compared to those in the control and treatment groups ($p<0.05$). Serum urea levels were not different between the control group and treatment groups ($p>0.05$). Serum creatinine levels were significantly higher in the 5-FU group compared to those in the other groups ($p<0.05$). When compared with serum creatinine levels, a significant decrease was observed in treatment groups compared to the 5-FU group ($p<0.05$). When compared with the control group, treatment groups determined that creatinine levels were high ($p<0.05$) (Fig. 1).

Effects of H and CUR on oxidative stress

SOD, CAT activities, and MDA levels in the 5-FU group decreased compared to those in the control group ($p<0.05$). However, the group with a high dose of H and CUR application had higher SOD activity and MDA level than the 5-FU group ($p<0.05$). SOD, CAT activities, and MDA levels in the group with a high dose of H and CUR application were similar to those in the control group ($p>0.05$). GR activity in the 5-FU group decreased compared to that in the control group ($p<0.05$). However, the group with a low dose of H and CUR application had higher GR activity than the 5-FU group ($p<0.05$). GR activity in the group with a low dose of H and CUR application was similar to that in the control group ($p>0.05$). When GSH levels were compared between groups, GSH levels in the 5-FU group decreased compared to those in the control group ($p<0.05$). It was determined that GSH levels of H- and CUR-treated groups increased compared to those of the 5-FU group ($p<0.05$), and these values were similar to the control ($p>0.05$) (Fig. 2).

Effects of H and CUR on renal histopathology

Control: Histopathological examination of the kidney tissue revealed a normal histological appearance (Fig. 3a). 5-FU: Histopathological examination of the kidney tissues revealed severe degeneration and necrosis of the renal tubular epithelium, severe dilatation in some renal tubular, dilatation in the bowman capsule, and severe congestion in the interstitial blood vessels (Fig. 3b). 5-FU+ H25: Kidney tissues revealed dilatation in some renal tubular and bowman capsules, severe degeneration of the epithelium of the renal tubules and moderate necrosis, and severe congestion of the veins (Fig. 3c). 5-FU+ H50: Kidney tissues revealed moderate degeneration of the renal tubular epithelium, mild necrosis, and moderate hyperemia of the blood vessels (Fig. 3d). 5-FU+ CUR100: Kidney tissues revealed mild dilatation in some renal tubular, moderate degeneration of renal tubular epithelium, mild necrosis, and congestion in interstitial blood vessels (Fig. 3e). 5-FU+ CUR200:

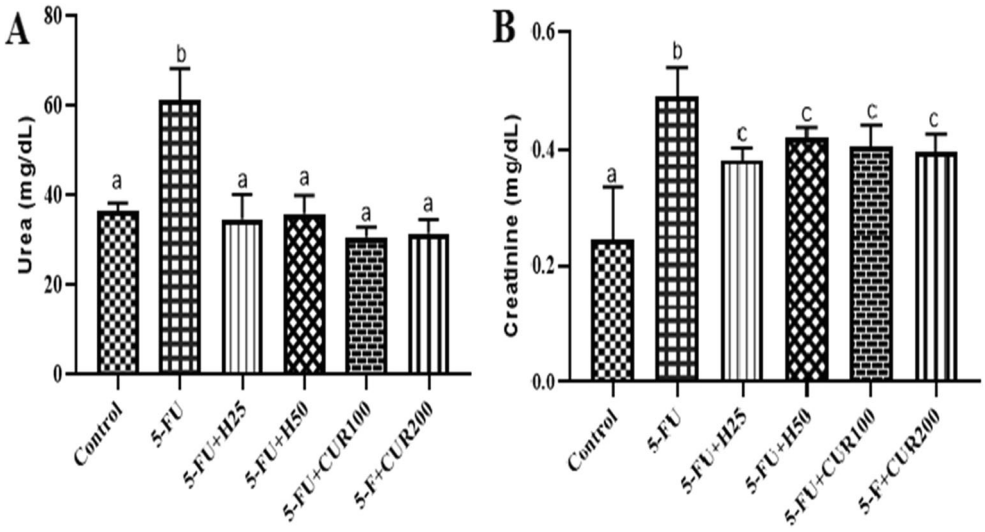

Fig. 1 Illustration of serum kidney parameters for all groups. A urea and B creatinine; the letters indicate the statistical differences among groups ($p<0.05$, $n=8$); the results were expressed as mean ± SD

Histopathological examination of the kidney tissues revealed very mild degeneration and mild congestion in the renal tubular epithelium (Fig. 3f and Table 1).

Effects of H and CUR on 5-FU–induced Caspase-3 and 8-OHdG expression

Immunohistochemical examination of kidney tissues obtained from mice in the control group revealed negative caspase-3 and 8-OHdG expressions (Figs. 4a, 5a and Table 1). In the immunohistochemical examination of the kidney tissues of 5-FU groups, severe cytoplasmic caspase-3 and 8-OHdG expressions were observed in the renal tubular epithelium (Figs. 4b and 5b). Statistically, a significant difference was determined when compared to the control group (p <0.05). In the 5-FU+H25 groups, severe caspase-3 and 8-OHdG expressions were determined in the renal tubular epithelium (Figs. 4c and 5c). In 5-FU+H50 groups, moderate cytoplasmic caspase-3 and 8-OHdG expressions were determined in the renal tubular epithelium (Figs. 4d and 5d). In the 5-FU+CUR100 group, moderate caspase-3 and 8-OHdG expressions were observed intra-cytoplasmically in the renal tubular epithelium (Figs. 4e and 5e). 5-FU+CUR200 groups: Immunohistochemical examination of the kidney tissues revealed mild caspase-3 and 8-OHdG expressions (Figs. 4f, 5f and Table 1).

Discussion

Currently, the main treatment option for cancer patients is chemotherapy, although there are serious clinical side effects (Ramadori and Cameron 2010; Naidu et al. 2004). In this study, we investigated the protective effects of H and CUR on 5-FU–induced renal dysfunction, oxidative stress, DNA damage, and apoptosis. The mechanism of renal toxicity caused by 5-FU is not completely clear. However, the possible mechanism proposed by several investigators has been reported to be the production of free radicals, resulting in lipid peroxidation, cell membrane damage, and apoptosis. The protective effect of H and CUR observed in this study may be related to the reduction of oxidative stress and apoptotic damage in the kidneys of 5-FU–treated mice. Urea and creatinine are among the most prominent determinants of kidney damage (Nada 2010). As previously reported, 5-FU–induced kidney damage is evident with increased urea and serum creatinine levels. Our findings are consistent with these studies, and the serum urea and creatinine levels of 5-FU–treated mice are very high (Nora and Ali 2012; Gelen et al. 2017a, 2017b). However, we found that H and CUR application prevented the increase of urea and creatinine levels. It was determined that these data obtained were compatible with previous studies (Elhelaly et al. 2019). Thus, the reduction in levels may be due to the nephroprotective activity of H and CUR. Lipid peroxidation, one of the mechanisms involved in the production of ROS in tissue damage, is determined by MDA measurement. A significant increase in MDA level in kidney tissue of rats treated with 5-FU was reported in previous studies (Gelen et al. 2017a, 2017b; Gelen et al. 2018). The findings of our study are similar to the data. The high dose of H significantly reduces the MDA level, and it was seen that both doses of CUR decrease the level of MDA. SOD, CAT, GR, and GSH are antioxidants, which protect against ROS by the removal of free radicals to avoid toxic damage. The depletion of SOD, CAT, GR, and GSH in tissue damages cellular defense against oxidative stress (Lawrence and Burk 1976). According to our results, the application of 5-FU leads to consumption of SOD, CAT, GR, and GSH reservoirs (Rashid et al. 2012; Rashid

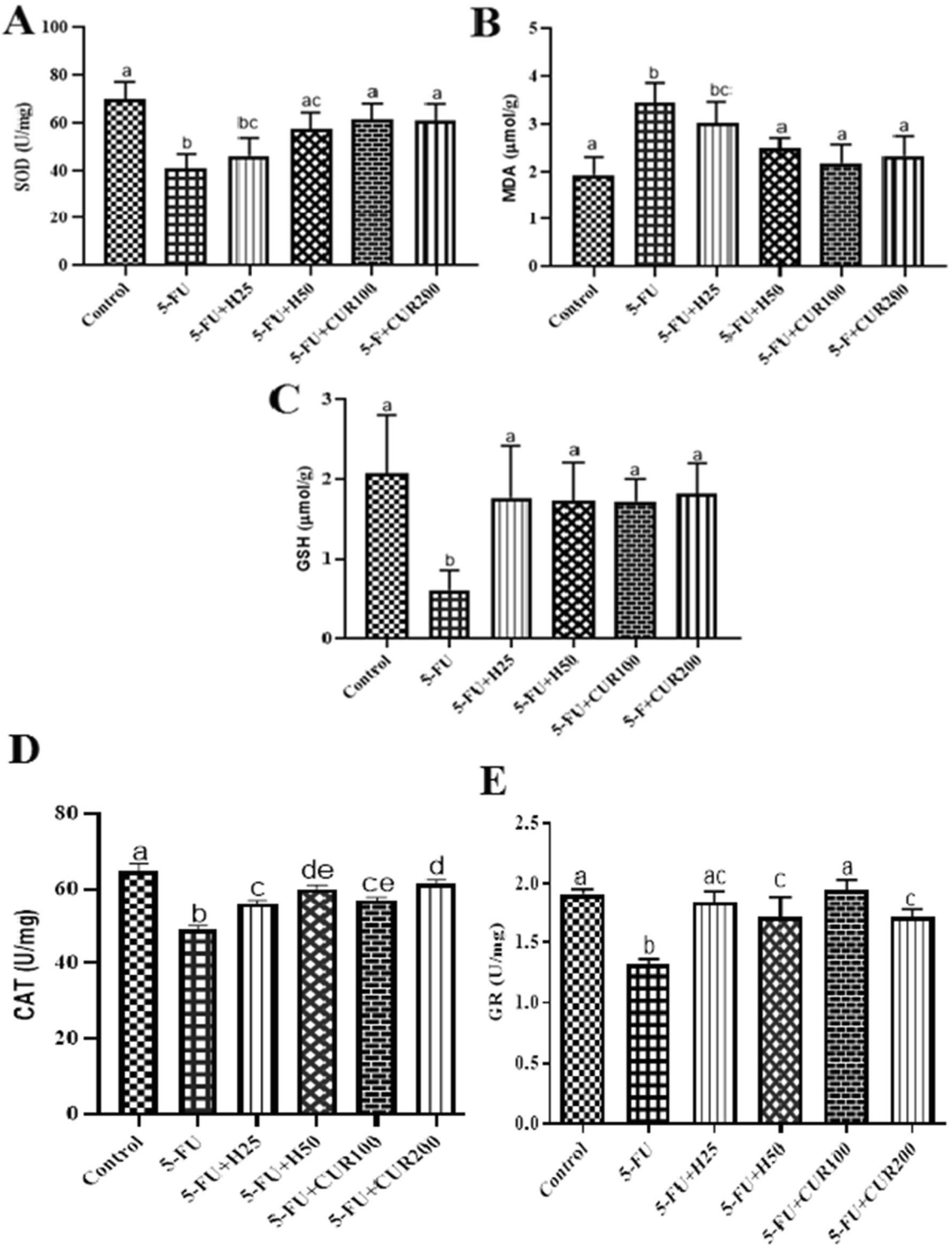

Fig. 2 Illustration of levels of oxidative parameters (SOD, MDA, and GSH) for all groups in the kidney tissues. A SOD activity, B MDA levels, C GSH levels, D CAT activity, and E GR activity; the letters indicate the statistical differences among groups ($p<0.05$, $n=8$); the results were expressed as mean ± SD

et al. 2013). In our study, we determined that the decrease in 5-FU–induced SOD, CAT, GR, and GSH activity of H and CUR improved. These data show that H and CUR prevent oxidative stress and support the antioxidant defense system. It was determined that these data obtained were compatible with previous studies (Elhelaly et al. 2019; Mercantepe et al.

Table 1 Histopathological and immunohistochemical evaluation of renal tissue in mice.

Parameters	Control	5-FU	5-FU + H25	5-FU + H50	5-FU + CUR100	5-FU + CUR200
Dilatation in tubular	0	3.00	2.00	1.50	1.00	0
Degeneration of tubular epithelium	0	3.00	3.00	2.00	2.00	1.00
Necrosis of tubular epithelium	0	2.50	2.00	1.00	1.00	0
Congestion in the vessels	0	3.00	3.00	2.00	2.00	1.00
Caspase-3	0	3.00	3.00	2.00	2.00	1.00
8-OHdG	0	3.00	3.00	2.00	2.00	1.00

None (0), mild (1), moderate (2), and severe (3)

2018). When the histopathological data were evaluated, normal glomerular and normal healthy renal tubular were detected in the control group. However, kidney tissue obtained from the 5-FU group had dilatation in the renal tubular, degeneration in the tubular epithelium, and hyperplasia in necrosis and vessels. We have determined that these changes caused by 5-FU in kidney tissue are consistent with our previous findings (Gelen et al. 2017a, 2017b) We observed that degeneration and necrosis findings in the kidney tissue obtained from the group where the high dose of H (50 mg/kg) was administered

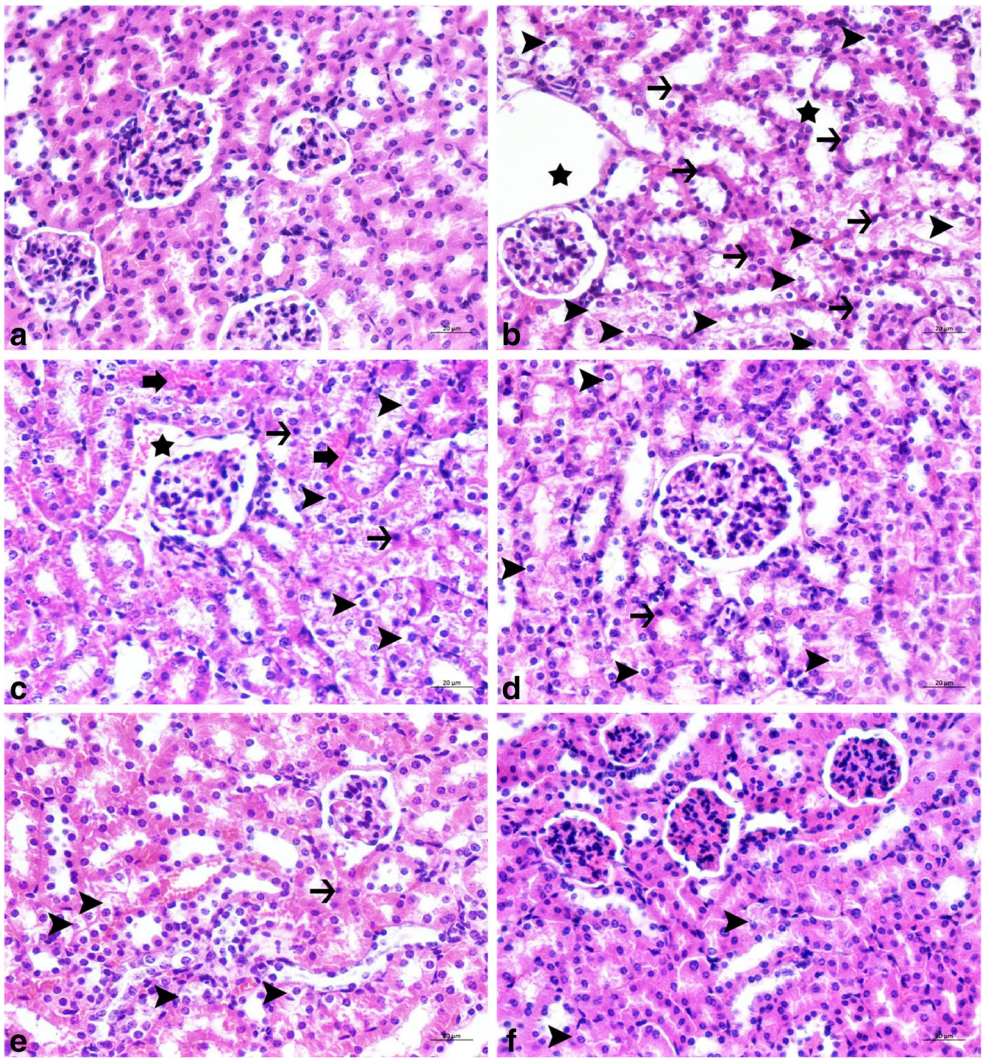

Fig. 3 Kidney tissue, control group, normal histological appearance (**a**); 5-FU group, severe vacuolar degeneration (arrowheads), necrosis (arrows), cystic dilatation in renal tubular (stars) (**b**). 5-FU+H25 groups, pronounced degeneration of renal tubular epithelium, moderate necrosis (arrows), congestion (thick arrows) in the peritubular blood capillaries, dilatation in bowman caps (asterisk) (**c**). 5-FU+H50 groups, moderate degeneration of renal tubular epithelium (arrowheads), very mild degeneration (arrows) in the renal tubular epithelium (**d**). 5-FU+CUR100 group, moderate degeneration of renal tubular epithelium, very mild necrosis (arrow) (**e**). 5-FU+CUR200 group, very mild degeneration (arrows) in tubular (**f**); H&E, bar: 20μm

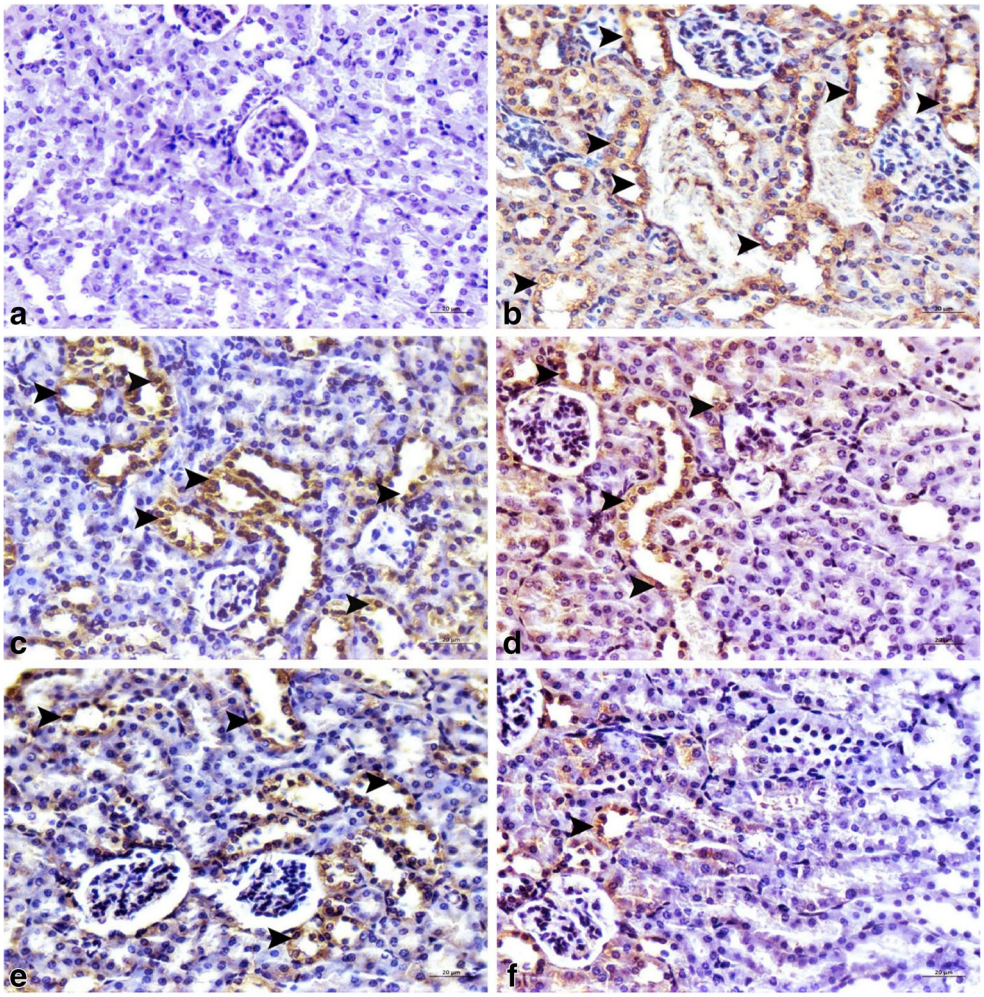

Fig. 4 Kidney tissue, control group, caspase-3 expression negative (**a**). 5-FU group, severe expression of caspase-3 in the renal tubular epithelium (**b**). 5-FU+H25 group, severe expression of caspase-3 in the renal tubular epithelium (**c**). 5-FU+H50 group, moderately cytoplasmic caspase-3 expression in the renal tubular epithelium (**d**). 5-FU+CUR100 groups, moderate expression of cytoplasmic caspase-3 in the epithelium of renal tubular (**e**). 5-FU+CUR200 group, very mild level of caspase-3 expression in the renal tubular epithelium (**f**). IHC-P, bar: 20μm

and CUR applied to both doses (100 and 200 mg/kg) decreased significantly compared to those in the renal tissues in the 5-FU group. Apoptosis caused by 5-FU has been previously reported to be a caspase-dependent process involving the activation of activated caspase-9 as well as activation of effector caspase-3 (Thant et al. 2008). Similarly, in our study, we found that it strongly induced caspase-3 in kidney tissues obtained from the 5-FU group. A significant reduction in caspase-3 expression of kidney tissues in mice treated with both doses of CUR compared to the 5-FU group was observed. Similarly, we found that caspase-3 expression in kidney tissues obtained from the group with a high dose of H was significantly altered compared to the 5-FU group. 8-OHdG is considered to be one of the most important markers of DNA damage caused by oxidative stress (Cadet et al. 2003; Stepniak and Karbownik-Lewinska 2016). Hydroxyl radicals resulting from oxidative stress lead to hydrogenation of the nucleic acid causing 8-OHdG (Cadet 2016). In previous a study, it was reported that DNA damage was intensified in rat tests after 5-FU administration (El-Sayyad and Hassan 2013). The data obtained from our study were similar to the findings of other studies, and the expression of 8-OHdG increased in renal tissues of mice in the 5-FU group. On the other hand, some studies have shown that the application of various antioxidant agents inhibits oxidative stress–induced DNA damage (Ince et al. 2014; Sengul et al. 2021a, 2021b). This shows that H and CUR have an antioxidant effect and thus reduce ROS-mediated 8-OHdG levels, thus preventing oxidative DNA damage. This finding is consistent with previous studies (Elhelaly et al. 2019; Mercantepe et al. 2018). This indicates that H and CUR treatment has a significant restorative effect on kidney damage caused by 5-FU.

Conclusion

The result provides more information on the mechanisms of 5-FU–induced renal toxicity and verifies the antioxidant and antiapoptotic potential of H and CUR. Other findings of this

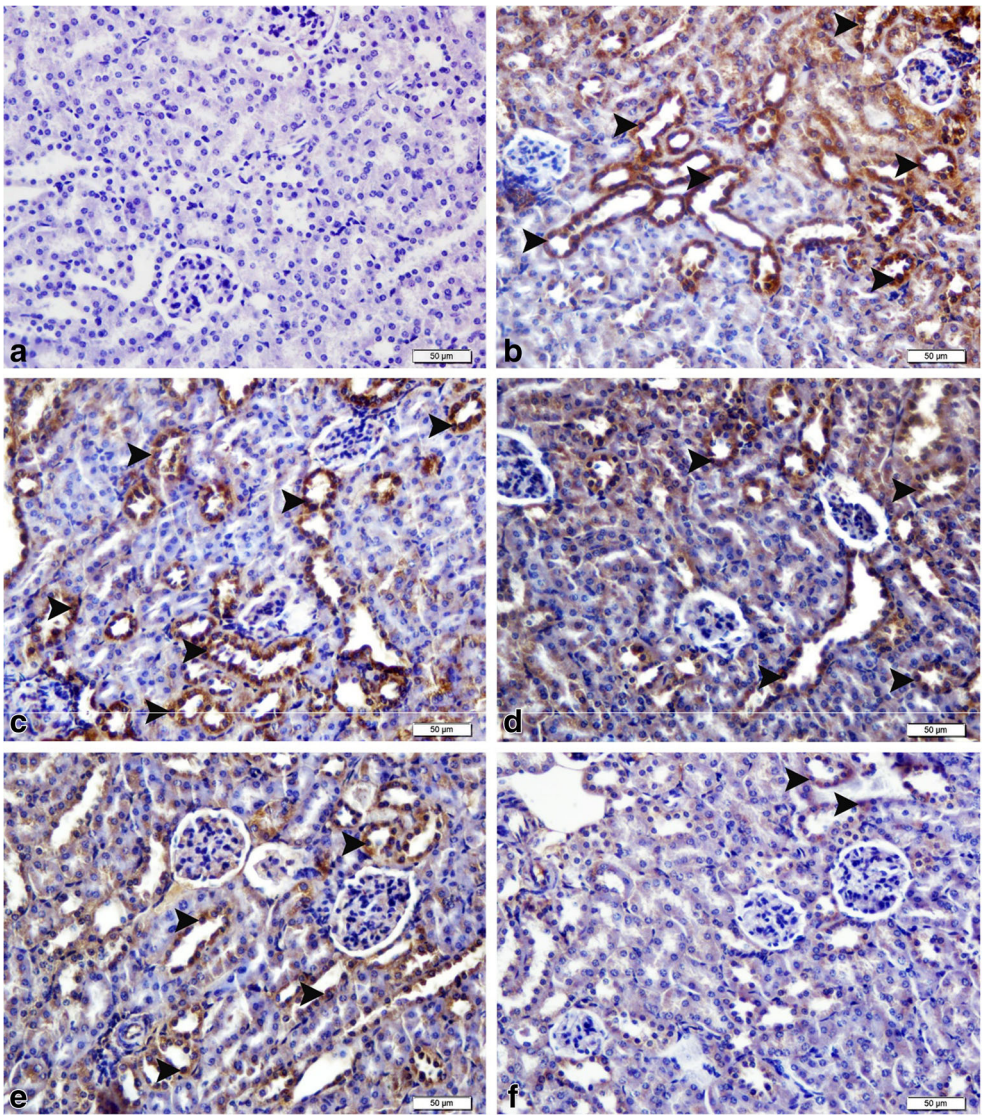

Fig. 5 Kidney tissue, control group, 8-OHdG expression negative (**a**). 5-FU group, severe expression of OHdG in the renal tubular epithelium (**b**). 5-FU+H25 group, severe expression of 8-OHdG in the renal tubular epithelium (**c**). 5-FU+H50 group, moderately cytoplasmic 8-OHdG expression in the renal tubular epithelium (**d**). 5-FU+CUR100 groups, moderate expression of cytoplasmic 8-OHdG in the epithelium of renal tubular (**e**). 5-FU+CUR200 group, very mild level of 8-OHdG expression in the renal tubular epithelium (**f**). IHC-P, bar: 20μm

study support the role of ROS, serum enzymes, apoptotic pathway, and DNA damage in the pathogenesis of 5-FU–induced renal toxicity. As a result, H and CUR eliminate 5-FU–induced renal toxicity in mice. These effects are thought to be due to their antioxidant and anti-inflammatory properties. Therefore, these agents may be clinically useful as a combination therapy following confirmatory studies at both clinical and clinical levels.

Availability of data and materials The authors confirm that the data and materials supporting the findings of this study are available within the article.

Author's contribution VG, EŞ, ST, AK: experiment design, experiment application, samples collection. VG, EŞ, ES: serum markers and tissue antioxidant estimation, data curation and analysis, final reviewing. SY: histopathological and immunohistochemical investigation. All the authors contributed to the writing and editing, and they read and approved the final manuscript.

Declarations

Ethics approval The study was designed and conducted according to ethical norms approved by the Atatürk University Rectorate Animal Experiments Local Ethics Committee (Erzurum, Turkey) (Protocol No. 2019/16).

Consent for publication Not applicable

Conflict of interest The authors declare no competing interests.

References

Abdel-Daim MM, Abdou RH (2015) Protective effects of diallyl sulfide and curcumin separately against thallium-induced toxicity in rats. Cell J 17:379–388

Abdel-Diam MM, Samak DH, El-Sayed YS, Aleya L, Alarifi S, Alkahtani S (2019) Curcumin and quercetin synergistically attenuate subacute diazinon-induced inflammation and oxidative

neurohepatic damage, and acetylcholinesterase inhibition in albino rats. Environ Sci Pollut Res Int 26:3659–3665

Aebi H (1983) Catalase. In: Bergmeyer HU (ed) Methods in enzymatic analysis. Academic Press, New York, pp 276–286

Ahmad ST, Arjumand W, Nafees S, Seth A, Ali N, Rashid S, Sultana S (2012) Hesperidin alleviates acetaminophen induced toxicity in Wistar rats by abrogation of oxidative stress, apoptosis and inflammation. Toxicol Lett 208:149–161

Ammon HPT, Wahl MA (1991) Pharmacology of Curcuma longa. Planta Med 57:1–7

Bosetti C, Rossi M, McLaughlin JK, Negri E, Talamini R, Lagiou P, Montella M, Ramazzotti V, Franceschi S, LaVecchia C (2007) Flavonoids and the risk of renal cell carcinoma. Cancer Epidemiol Biomark Prev 16:98–101

Cadet J (2016) Oxidative degradation pathways of cellular DNA: product formation and mechanistic insights. Free Radic Biol Med 75:S2

Cadet J, Douki T, Gasparutto D, Ravanat JL (2003) Oxidative damage to DNA: formation, measurement and biochemical features. Mutat Res Fund Mol M 531:5–23

Carlberg I, Mannervik B (1975) Glutathione reductase levels in rat brain. J Biol Chem 250:5475–5480

Chanet A, Milenkovic D, Manach C, Mazur A, Morand C (2012) Citrus flavanones: what is their role in cardiovascular protection? J Agric Food Chem 60:8809–8822

Chang CT, Ho TY, Lin H, Liang JA, Huang HC, Li CC, Lo HY, Wu SL, Huang YF, Hsiang CY (2012) 5-Fluorouracil induced intestinal mucositis via nuclear factor-kB activation by transcriptomic analysis and in vivo bioluminescence imaging. PLoS One 7:e31808

Chibber S, Farhan M, Hassan I, Naseem I (2011) White light-mediated Cu (II)-5FU interaction augments the chemotherapeutic potential of 5-FU: an in vitro study. Tumour Biol 32:881–892

David T, Peter HC, Gregory T, Catherine B, Saurabh S (2011) In vivo effects of immunomodulators in a murine model of fluorouracil-induced mucositis. Curr. Therapeutic Res 72:262–272

Elhelaly AE, AlBasher G, Alfarraj S, Almeer R, Bahbah EI, Fouda MMA, Bungău SG, Aleya L, Abdel-Daim MM (2019) Protective effects of hesperidin and diosmin against acrylamide-induced liver, kidney, and brain oxidative damage in rats. Environ Sci Pollut Res 26:35151–35162

El-Sayyad IH, Hassan A (2013) Effects of adriamycin, cisplatin, and 5-fluorouracil on the testes of albino rats. Br J Med Health Sci 1:45–62 49

Farombi EO, Abarikwu SO, Adedara IA, Oyeyemi MO (2007) Kolaviron and curcumin ameliorate di-n-Butylphthalate-induced testicular toxicity in rats. Basic Clin Pharmacol Toxicol 100:43–48

Gelen V, Şengül E (2018) Hematoprotective effect of naringin on 5-FU toxicity in rats. Chem Res J 3:127–130

Gelen V, Şengül E (2020) Antioxidant, antiinflammatory and antiapoptotic effects of naringin on cardiac damage induced by cisplatin. Indian J Tradit Knowl 19:459–465

Gelen V, Şengül E, Gedikli S, Atila G, Uslu H, Makav M (2017a) The protective effect of rutin and quercetin on 5-FU-induced hepatotoxicity in rats. Asian Pac J Trop Biomed 7:647–653

Gelen V, Şengül E, Gedikli S, Gür C, Özkanlar S (2017b) Therapeutic effect of quercetin on renal function and tissue damage in the obesity induced rats. Biomed Pharmacother 89:524–528

Gelen V, Şengül E, Yıldırım S, Atila G (2018) The protective effects of naringin against 5-fluorouracil-induced hepatotoxicity and nephrotoxicity in rats. Iran J Basic Med Sci 21:404–410

Gelen V, Gelen S.U, Celebi F, Cinar A, Yildirim S, Eser G (2019) The protective effect of Lactobacillus rhamnosus, Lactobacillus fermentum and Lactobacillus brevis against cisplatin-induced hepatic damage in rats. Fresenius Environ Bull 28:7583–7592.

Hussein M, Othman S (2011) Structure activity relationship of antioxidative property of hesperidin. International Journal of Pharmaceutical Research and Development 3:19–29

Inano H, Onoda M, Inafuku N, Kubota M, Kamada Y, Osawa T, Kobayashi H, Wakabayashi K (2000) Potent preventive action of curcumin on radiation-induced initiation of mammary tumorigenesis in rats. Carcinogenesis 21:1835–1841

Ince S, Arslan Acaroz D, Neuwirth O, Demirel HH, Denk B, Kucukkurt I, Turkmen R (2014) Protective effect of polydatin, a natural precursor of resveratrol, against cisplatin induced toxicity in rats. Food Chem Toxicol 72:147–153

Khan R, Sultana S (2011) Farnesol attenuates 1,2-dimethylhydrazine induced oxidative stress, inflammation and apoptotic responses in the colon of Wistar rats. Chem Biol Interact 192:193–200

Kinhult S, Albertsson M, Eskilsson J, Cwikiel M (2003) Effects of probucol on endothelial damage by 5-fluorouracil. Acta Oncol 42: 304–308

Klinkhammer BM, Djudjaj S, Kunter U, Palsson R, Edvardsson VO, Wiech T, Thorsteinsdottir M, Hardarson S, Foresto-Neto O, Mulay SR, Moeller MJ, Jahnen-Dechent W, Floege J, Anders HJ, Boor P (2020) Cellular and molecular mechanisms of kidney injury in 2,8-dihydroxyadenine nephropathy. J Am Soc Nephrol 31:799–816

Lamberti M, Porto S, Marra M, Zappavigna S, Grimaldi A, Feola D, Pesce D, Naviglio S, Spina A, Sannolo N, Caraglia M (2012) 5-Fluorouracil induces apoptosis in rat cardiocytes through intracellular oxidative stress. J Exp Clin Cancer Res 19:31–60

Lawrence RA, Burk RF (1976) Glutathione peroxidase activity in selenium-deficient rat liver. Biochem Biophys Res Commun 71: 952–958

Mercantepe F, Mercantepe T, Topcu A, Yılmaz A, Tumkaya L (2018) Protective effects of amifostine, curcumin, and melatonin against cisplatin-induced acute kidney injury. Naunyn Schmiedeberg's Arch Pharmacol 391:915–931

Middleton E Jr, Kandaswami C, Theoharides TC (2000) The effects of plant flavonoids on mammalian cells: implications for inflammation, heart disease, and cancer. Pharmacol Rev 52:673–751

Miura K, Kinouchi M, Ishida K, Fujibuchi W, Naitoh T, Ogawa H, Ti A, Yazaki N, Watanabe K, Haneda S, Shibata C, Sasaki I (2010) 5-FU metabolism in cancer and orally-administrable 5-FU drugs. Cancers 2:1717–1730

Nada O (2010) A review of propolis antitumour action in vivo and in vitro. J. Api Product ApMed Sci 2:1–20

Naidu MU, Ramana GV, Rani PU, Mohan IK, Suman A, Pb R (2004) Chemotherapy-induced and/or radiation therapy-induced oral mucositis complicating the treatment of cancer. Neoplasia 6:423–431

Nora E, Ali (2012) Protective effect of captopril against 5-fluorouracil-induced hepato and nephrotoxicity in male albino rats. J Am Sci:8

Placer ZA, Cushmanni LL, Johnson BC (1966) Estimation of products of lipid peroxidation (as malondialdehyde) in biochemical systems. Anal Biochem 16:359–364

Ramadori G, Cameron S (2010) Effects of systemic chemotherapy on the liver. Ann Hepatol 9:133–143.

Rashid S, Ali N, Nafees S, Ahmad S. Tanveer Arjumand W, Hasan S, Kazim Sultana S (2012) Alleviation of doxorubicin induced nephrotoxicity and hepatotoxicity by chrysin in Wistar rats. Toxicol Mech Methods 23:337–345.

Rashid S, Ali N, Nafees S, Ahmad S, Tanveer Hasan S, Kazim Sultana S (2013) Abrogation of 5-flouroracil induced renal toxicity by bee propolis via targeting oxidative stress and inflammation in Wistar rats. J Pharm Res 7:189–194

Sakat MS, Kilic K, Akdemir FNE, Yildirim S, Eser G, Kiziltunc A (2019) The effectiveness of eugenol against cisplatin-induced ototoxicity. Braz J Otorhinolaryngoly 85:766–773

Sedlak J, Lindsay RH (1968) Estimation of total protein bound and nonprotein sulfhydryl groups in tissue with Ellman's reagent. Anal Biochem 25:192–205

Selvaraj P, Pugalendi KV (2012) Efficacy of hesperidin on plasma, heart and liver tissue lipids in rats subjected to isoproterenol-induced cardiotoxicity. Exp Toxicol Pathol 64:449–452

Şengül E, Gelen V, Gedikli S, Özkanlar S, Gür C, Çelebi F, Çınar A (2017) The protective effect of quercetin on cyclophosphamide-induced lung toxicity in rats. Biomed Pharmacother 92:303–307

Sengul E, Gelen SU, Yıldırım S, Çelebi F, Çınar A (2019) Probiotic bacteria attenuates cisplatin-induced nephrotoxicity through modulation of oxidative stress, inflammation and apoptosis in rats. Asian Pac J Trop Biomed 9:116

Sengul E, Gelen V, Gedikli S (2021a) Cardioprotectıve activities of quercetin and rutin in Sprague-Dawley rats treated wıth 5-fluorouracil. J Anim Plant Sci 31:423–443

Sengul E, Gelen V, Yildirim S, Tekin S, Dag Y (2021b) The effects of selenium in acrylamide-induced nephrotoxicity in rats: roles of oxidative stress, inflammation, apoptosis, and DNA damage. Biol Trace Elem Res 199:173–184

Stepniak J, Karbownik-Lewinska M (2016) 17 β-estradiol prevents experimentally-induced oxidative damage to membrane lipids and nuclear DNA in porcine ovary. Syst Biol Reprod Med 62:17–21

Suarez J, Herrera MD, Marhuenda E (1998) In vitro scavenger and antioxidant properties of hesperidin and neohesperidin dihydrochalcone. Phytomedicine 5:469–473

Sun Y, Larry WO, Ying L (1988) A simple method for clinical assay of superoxide dismutase. Clin Chem 34:497–500

Surh YJ, Chun KS, Cha HH (2001) Molecular mechanisms underlying chemopreventive activities of anti-inflammatory phytochemicals: downregulation of COX-2 and iNOS through suppression of NF-kappa B activation. Mutat Res 1:243–268

Thant AA, Wu Y, Lee J, Mishra DK, Garcia H, Koeffler HP, Vadgama JV (2008) Role of caspases in 5-FU and selenium-induced growth inhibition of colorectalcancer cells. Anticancer Res 28:3579–3592

Wang X, Morris ME (2007) Effects of the flavonoid chrysin on nitrofurantoin pharmacokinetics in rats: potential involvement of ABCG2. Drug Metab Dispos 35:268–274

Yildirim S, Ozkan C, Huyut Z, Çınar A (2019) Detection of Se, vit. E, vit. A, MDA, 8-OHdG, and CoQ10 levels and histopathological changes in heart tissue in sheep with white muscle disease. Biol Trace Elem Res 188:419–423

Publisher's note Springer Nature remains neutral with regard to jurisdictional claims in published maps and institutional affiliations.