

Journal of the Hellenic Veterinary Medical Society

Vol 75, No 1 (2024)



Pathological and Molecular Investigations in the Aborted Fetal Lamb due to the Poxvirus

E Beytut, N Coskun, S Dag, H Nuhoglu, E Karakurt, V Yilmaz, A Yildiz

doi: [10.12681/jhvms.32180](https://doi.org/10.12681/jhvms.32180)

Copyright © 2024, E Beytut, N Coskun, S Dag, H Nuhoglu, E Karakurt, V Yilmaz, A Yildiz



This work is licensed under a [Creative Commons Attribution-NonCommercial 4.0](https://creativecommons.org/licenses/by-nc/4.0/).

To cite this article:

Beytut, E., Coskun, N., Dag, S., Nuhoglu, H., Karakurt, E., Yilmaz, V., & Yildiz, A. (2024). Pathological and Molecular Investigations in the Aborted Fetal Lamb due to the Poxvirus. *Journal of the Hellenic Veterinary Medical Society*, 75(1), 7185–7190. <https://doi.org/10.12681/jhvms.32180>

Pathological and Molecular Investigations in the Aborted Fetal Lamb due to the Poxvirus

E. Beytut¹, N.Coskun², S. Dag¹, H. Nuhoglu¹, E. Karakurt¹, V. Yilmaz², A. Yildiz¹

¹Department of Pathology and Virology

²Faculty of Veterinary Medicine, University of Kafkas, Kars/Turkey

ABSTRACT: In this case, the sheeppox virus strain-induced abortion in a ewe and fetal lesions are reported. At the necropsy, pock nodules of varying sizes were seen to scatter over the skin and lungs of the fetus. Histological examination of the pock nodules from the skin and the lungs found typical sheeppox cells and cytoplasmic inclusion bodies. Immunohistochemistry to surfactant proteins (SP) and multi-cytokeratin (MCK) confirmed hyperplasia of type II cells and bronchial lining epithelium in the pock nodes. A polymerase chain reaction (PCR) test using skin nodules confirmed the causing agent is a *Capripoxvirus*. The phylogenetic comparison of the sheeppox virus (SPPV), goatpox virus (GPPV), and lumpy skin disease virus (LSDV) revealed that the reason for abortion was the sheeppox virus strain.

Keywords: Abortion; Molecular; Pathology; Ovine fetus; Sheeppox virus

Corresponding Author:

Prof. Dr. Enver BEYTUT, Department of Pathology, Faculty of Veterinary Medicine, University of Kafkas, Kars/Turkey
E-mail address: enverbeytut@hotmail.com

Date of initial submission: 1.12.2022
Date of acceptance: 31.1.2023

CASE HISTORY

Sheeppox is caused by a DNA virus member of the family *Poxviridae* and of the genus of *Capripoxvirus* which consists of 3 different viruses namely the sheeppox virus (SPPV), goatpox virus (GTPV), and lumpy skin disease virus (LSDV) (Yager and Scott, 1985). Outbreaks of the disease occur mainly in Asia, Africa, and the Middle East. The disease is the most important pox virus infection of domestic animals with considerable mortality in susceptible flocks (Yager and Scott, 1985; Sumana et al., 2020). Sheeppox is most severe in neonatal lambs than in adult sheep, with mortality reaching 80-100 % (Hurisa et al., 2018; Lafar et al., 2019; Sumana et al., 2020; Zewdie et al., 2021). Even though the limited data about abortion caused by the sheeppox has been documented as a cause of economic losses in a few review articles (Hurisa et al., 2018; Zewdie et al., 2021), our best literature search did not find a published paper confirming the virus-induced abortion or describing the lesions in fetal lambs. Thus, this case aims to report the sheeppox virus strain-induced abortion in a ewe along with the description of the fetal lesions and to examine the *Capripoxvirus* nucleic acid using PCR along with differential diagnosis using molecular characterization.

An aborted crossbreed sheep fetus, about 4,5 months of gestation, was admitted to the Department of Pathology, Faculty of Veterinary Medicine, the University of Kafkas for necropsy in January 2022. At the visit to the flock where the fetus was submitted, the ewe did not show any clinical signs or skin lesions of the disease. The flock's owner stated also that the ewe had no history of the disease and the flock was not vaccinated for sheeppox. Following the gross examination, the fetus was systematically necropsied. Tissue samples taken from the skin and all internal organs were fixed in 10% buffered formalin and processed routinely, and the sections of 4µm in thickness were stained with hematoxylin and eosin (HE). To evaluate the proliferation of type II cells and airways epithelium in the pock nodules, serial lung sections were stained with Avidin-Biotin-Peroxidase Complex (ABC) technique (Hsu et al., 1981), using the Genemed Acu-Stain Mouse + Rabbit HRP Kit (Cat No. 54-0003), surfactant protein (SP) antibodies (SP-A: Chemicon AB3424; SP-B: Abcam AB40876), Multi Cytokeratin (MCK clone: AE1/AE3, Invitrogen MA1-82041) and Proliferating Cell Nuclear Antigen (PCNA). The routinely de-waxed and hydrated sections were treated with a 3% H₂O₂ solution for 20

min to block endogenous peroxidase. Then, the sections were allowed to boil in citrate buffer (pH 6.0) in a microwave oven (800W) for antigen retrieval for 20 min. After the sections were incubated with 10% normal goat serum (Reagent A), they were incubated with primary antibodies according to the manufacturer's datasheet. The sections were then incubated with biotinylated goat anti-rabbit secondary antibody (Reagent B) for 30 min at room temperature (RT). And then, the sections were treated with streptavidin-peroxidase (Reagent C) for 30 min at RT. Immunolabeling was obtained with 3-amino-9-ethyl carbazole (AEC) as the chromogen.

For the nucleic acid extraction, the skin nodules were homogenized and centrifuged and DNA extraction was performed using the phenol/chloroform described previously (Sambrook & Russel., 2001). PCR was used for *Capripoxvirus* nucleic acid investigation. The A4L gene was chosen as it is conservative and it allows the distinction of SPPV, GTPV, and LSDV after sequencing of this gene (Madhavan et al., 2020). The expected amplicon size was 486 bp with this primer pair. PCR product was visualized in a transilluminator after electrophoresis in 1% agarose gel containing Safe-Red (Safe View™ Cat No: G108-R, Canada) DNA stain. For phylogenetic analysis, the amplicon was sent to a commercial company for Sanger sequencing. The obtained sequence was compared to the reference strains of SPPV, GTPV, and LSDV in the GenBank database. Sequence alignment was performed using Bioedit (Version 7.0.5.3) Hall., 1999 and phylogenetic analysis was performed using MEGA7 software as previously described (Tamura et al., 2011).

At the gross examination, the fetus was weakly developed and numerous pock nodules of varying sizes were scattered throughout the skin (Figure 1a). The kidneys showed small whitish nodules on capsular and cut surfaces. Multiple whitish pock nodules of varying sizes were seen to be distributed to all lung lobes (Figure 1b). Histopathological examination of the skin papules revealed microvesicles of varying sizes having a small amount of fluid (Figure 1c), acanthosis, and the increase of mononuclear cells in the epidermis. The dermal layer showed vasculitis and numerous characteristic sheeppox cells with vacuolated nuclei and marginated chromatin. The sheeppox cells often had eosinophilic cytoplasmic inclusion bodies. In the lungs, pock nodules were characterized by proliferative bronchiolitis and alveolitis giving

an appearance of the gland-like which were formed by the proliferative type II cells (Figure 1d), along with numerous sheeppox cells having typical chromatin marginated-nuclei and abundant eosinophilic cytoplasm. The sheeppox cells in the pock nodules revealed often cytoplasmic inclusion bodies (Figure 1d, inset). Bronchioles and alveoli contained necrotic and desquamated cells with inflammatory cell infiltration. The lining epithelium of the terminal bronchiole showed hyperplasia and caused to narrowing of

the airways. The kidneys had also multiple foci comprised of lymphoid cells.

A slight immunopositive reaction to SP-A occurred in the cytoplasm of the proliferative type II cells and in the necrotic debris within the alveoli in the pock nodules. Non-ciliated Clara cells revealed positive staining against the marker. But, strong SP-B immunostaining was detected in the proliferative type II cells of the pock nodules (Figure 1e) and the reaction

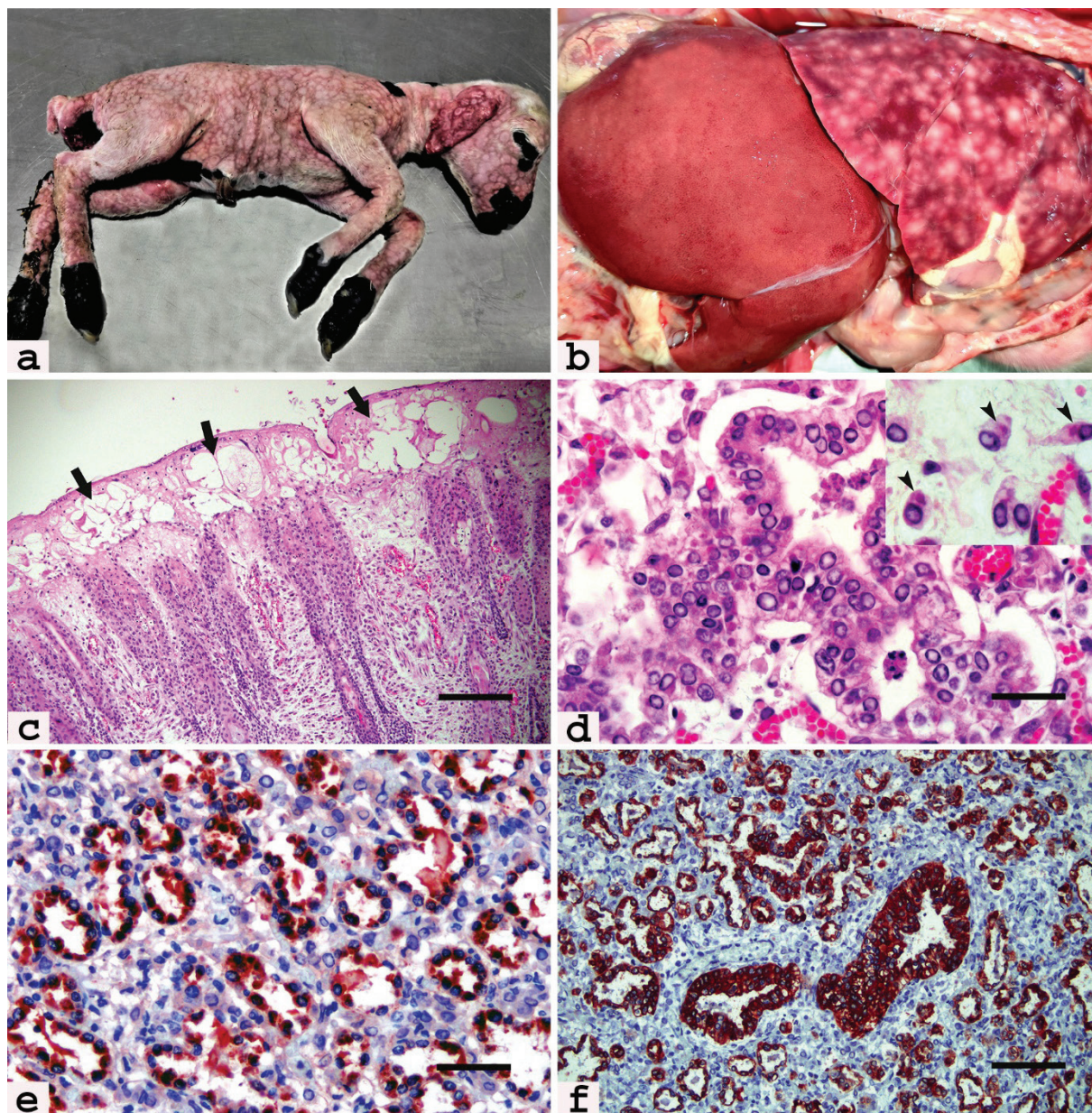


Figure 1. (a) Numerous skin papules of different sizes are distributed to all the skin of the fetus. (b) Whitish pock nodules of varying sizes are scattered to the lung lobes. (c) The vesicles (arrows) of various sizes in the epidermis (HE, Bar₅₄₃). (d) The bronchial epithelium shows hyperplasia (HE, Bar₅₁), with many sheeppox cells having cytoplasmic inclusion bodies (inset, arrowheads). (e) SP-B immunoreaction in the cytoplasm of hyperplastic type II cells (ABC, Bar_{51A}). (f) Immunohistochemistry to CK confirms gland-like proliferation of type II cells in the pock nodule (ABC, Bar₁₆₆), along with hyperplasia of bronchial epithelium.

was more diffuse compared to SP-A. Immunostaining for SP-B mainly occurred in the apical cytoplasm of the type II cells which were proliferated as gland-like structures. Non-ciliated Clara cells also positively reacted with SP-B. However, the bronchial lining epithelium and sheeppox cells did not show any reaction for SP-A and SP-B. MCK immunostaining against lung epithelial cells found also severe hyperplasia of type II cells in pock nodules (Figure 1f). MCK immunopositivity displayed the gland-like structures formed by the proliferation of type II cells in the nodules. Thin cytoplasmic extensions of type I alveolar epithelial cells in the wall of alveoli and bronchial lining epithelium showed also a positive reaction to the MCK, with no reaction of sheeppox cells. Hyperplastic type II cells and bronchial lining epithelium showed a nuclear positive reaction for PCNA.

After performing PCR, the correct-sized amplicon (approx. 486 bp) was obtained. PCR product was confirmed by sequencing. The sequence was submitted to GenBank (Accession number: ON521728). After phylogenetic analysis; SPPV, GTPV, and LSDV reference strains were grouped in the different branches and the sample was clustered with SPPV reference strains. Our analysis revealed that the sheeppox virus strain caused the abortion (Figure 2).

DISCUSSION

The reported case highlighted that the SPPV strain induces abortion in ewes and causes severe fetal lesions. In the literature (Hurisa et al., 2018; Zewdie et al., 2021), abortions due to the sheeppox have been reported not to be common and cause trade restrictions. Mims (1981) reported that the smallpox virus from the *Poxviridae* is the only virus that causes significant lesions resulting in fetal death in humans. Poxviruses are transmitted to mammalian fetuses during embryological development, and fetal involvement follows of primary infection of the mother during the first 3 months of gestation. Following the infection of the mother, the virus spreads in the bloodstream to reach the placenta. After the infection is established in the placenta, the virus is discharged into the fetal circulation, and then the disease is localized in the visceral organs, resulting in fetal death and abortions (Mims, 1981). Our detailed literature review did not find a document explaining the mechanisms of abortion by the sheeppox virus. In the present case, the fact that the fetus had severe lesions in the skin, lungs, and kidneys shows that the fetus might have been expelled following intrauterine death. But, as the placenta was not presented along with the fetus, it could not be examined for the presence of placentitis.

At the gross examination, numerous papules of dif-

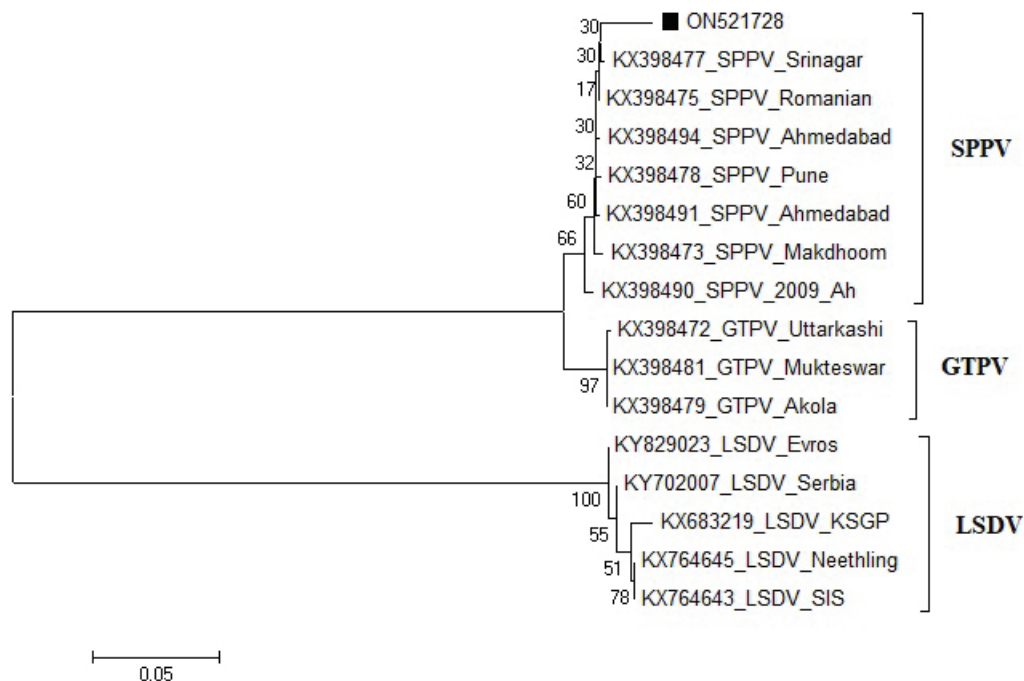


Figure 2. Phylogenetic tree constructed with neighbor-joining method using MEGA7 software with reference sheeppox virus, goatpox virus, and lumpy skin disease virus strains. The sequence obtained in this case (ON521728) is indicated with a black square.

ferent sizes were seen to scatter over the body. Similar skin lesions have early been reported in neonatal lambs with sheeppox infection in Turkey (Gulbahar et al., 2006; Eroksuz et al., 2008; Beytut, 2010) and other parts of the World (Zangana & Abdullah, 2013; Hamouda et al., 2017; Hurisa et al., 2018). Pulmonary lesions that were seen as whitish nodules in the fetus have not been early documented and the lesions were reported as the characteristics of the disease in lambs (Gulbahar et al., 2000; Mondal et al., 2004; Beytut, 2010). The major cause of the death of lambs with sheeppox has been attributed to pulmonary pock lesions (Mondal et al., 2004). The fetal skin lesions consisted of multiple epidermal cysts, sheeppox cells with inclusion bodies, epidermal hyperplasia, and ballooning degeneration have also been reported in lambs by other authors (Milli et al., 1991; Gulbahar et al., 2006; Eroksuz et al., 2008; Beytut, 2010; Zangana & Abdullah, 2013; Hamouda et al., 2017). It was noticed that skin lesions observed in the fetus were more severe than those reported in neonatal lambs with sheeppox (Gulbahar et al., 2000; Gulbahar et al., 2006; Beytut, 2010). The disseminated pulmonary pock nodules revealed proliferative alveolitis characterized by the massive proliferation of type II cells giving the appearance of gland-like, along with numerous sheeppox cells with punched-out nuclei. The pock nodules showed also marked hyperplasia of epithelial lining cells in the bronchioles. Both alveolar type II pneumocytes and epithelial lining cells of airways are the sites where the virus propagates and induces the cells' proliferation (Milli et al., 1991). These pathognomonic findings were similar to those reported in sheeppox virus infections of neonates (Milli et al., 1991; Gulbahar et al., 2000; Gulbahar et al., 2006; Beytut, 2010; Hamouda et al., 2017). Thus, the gross and histological lesions in the SPPV strain-induced aborted fetus are first time described, and these are highly suggestive of the disease.

Immunohistochemistry was performed to differentiate the cell types that proliferated in the pock nodules. Immunostainings to SP-A and SP-B openly found severe hyperplasia of type II cells forming a gland-like appearance and confirmed that sheeppox viruses induce hyperplasia of type II cells, as reported earlier (Milli et al., 1991; Beytut, 2010). Immunoreaction in the apical cytoplasm of type II cells was supposed to be lamellar bodies where mature SP-B is stored before secretion into the alveolar lumina (Hermans & Bernard, 1999; Beytut, 2010). Sheeppox cells are the sites of viral replication and the cells are supposed to originate from the monocytic lineage (Yager

& Scott, 1985). The negative reaction of the sheeppox cells for surfactant proteins might support the opinion that sheeppox cells are not originated from lung epithelial cells. Consistently, other studies (Liao et al., 2000; Luks et al., 2001) reported that numerous type II cells revealed apical SP-B cytoplasmic aggregates in normal sheep fetuses and that immunohistochemistry for SP-B allowed identifying of type II cells in fetal lungs. Thus, the SP reaction in the lung was interpreted as the actively secreted surfactant in sheep fetuses during the last period of gestation. MCK immunostaining showed marked hyperplasia of both type II cells and the lining epithelium of the bronchi. Although MCK is not specific for type II cells, it was seen that type II cells showed a strong reaction to MCK, and those pulmonary pock nodules consisted of the predominantly gland-like proliferation of the cells, along with hyperplasia of the lining epithelium of bronchioles. Also, PCNA nuclear immunolabeling confirmed a severe proliferation of both type II cells and bronchial epithelium in the pock nodules.

Although the *Capripoxvirus* genus is considered host-specific, cross-species transmission between sheep and goats has been previously reported (Madhavan et al., 2020). Our detailed literature review found that LSDV among poxvirus strains previously caused intrauterine transmission in bovines (Rouby & Aboul-soud, 2016). SPPV and GTPV are indistinguishable using serological means. But members of *Capripoxvirus* can be differentiated with molecular methods. In this case, there were no clinical signs of the disease in the ewe and flock. This data might show the possibility of a cross-species infection by GTPV or LSDV. But, the molecular characterization revealed that the abortion was induced by a SPPV strain. Thus, in the detection of the causative virus, molecular techniques should be used instead of serological examination.

In conclusion, the reporting of both abortion and the description of fetal lesions caused by the SPPV strain, which was confirmed by using molecular techniques, will make an important contribution to sheep breeding and the scientific background.

Conflict of interest statement

The authors declare no conflicts of interest.

Ethical approval

This case report is approved by the Republic of Turkey, Ministry of Agriculture and Forestry (E-52516679-903.07.01-5173776).

REFERENCES

- Beytut, E. (2010). Sheep pox virus induces proliferation of type II pneumocytes in the lungs. *J Comp Pathol*, 143(2-3), 132-141. DOI: 10.1016/j.jcpa.2010.01.014
- Eroksuz, Y., Bulut, H., Gulacti, I. & Ceribasi, A. O. (2008). Seasonal distribution of sheeppox cases in lambs in Eastern Turkey. *J Anim Vet Adv*, 7(5), 638-642. DOI: javaa.2008.638.642
- Gulbahar, M. Y., Cabalar, M., Gul, Y. & Icen, H. (2000). Immunohistochemical detection of antigen in lamb tissues naturally infected with sheeppox virus. *J Vet Med Series B*, 47(3), 173-181. DOI: 10.1046/j.1439-0450.2000.00321.x
- Gulbahar, M. Y., Davis, W. C., Yuksel, H. & Cabalar, M. (2006). Immunohistochemical evaluation of inflammatory infiltrate in the skin and lung of lambs naturally infected with sheeppox virus. *Vet Pathol*, 43(1), 67-75. DOI: 10.1354/vp.43-1-67
- Hall, T.A. (1999) BioEdit: A user-friendly biological sequence alignment editor and analysis program for Windows 95/98/NT. *Nucleic Acids Symp Ser* 41:95-98
- Hamouda, M., Al-Hizab, F. & El-Sabagh, I. (2017). Clinical, pathological and molecular diagnosis of sheeppox virus in Saudi Arabia. *J Anim Plant Sci*, 27(1), 91-97.
- Hermans, C. & Bernard, A. (1999). Lung epithelium-specific proteins: characteristics and potential applications as markers. *Am J Respir Crit Care Med*, 159(2), 646-678. DOI: 10.1164/ajrccm.159.2.9806064
- Hsu, S. M., Raine, L. & Fanger, H. (1981). Use of avidin-biotin-peroxidase complex (ABC) in immunoperoxidase techniques: a comparison between ABC and unlabeled antibody (PAP) procedures. *J Histochem Cytochem*, 29, 577-580.
- Hurisa, T. T., Jing, Z., Jia, H., Chen, G. & He, X. B. (2018). A review on sheeppox and goatpox: Insight of epidemiology, diagnosis, treatment and control measures in Ethiopia. *J Infect Dis Epidemiol*, 4(3), 057. DOI: 10.23937/2474-3658/1510057
- Lafar, S., Zro, K., Haegeman, A., Khayli, M., De Clercq, K., Lancelot, R. & Ennaji, M. (2019). Clinical and epidemiological evolution of sheep pox in Morocco. *J Agric Sci Technol*, 9(2), 103-113. DOI: 10.17265/2161-6256/2019.02.004
- Liao, S. L., Luks, F. I., Piasecki, G.J., Wild, Y. K., Papadakis, K. & De Paepe, M. E. (2000). Late-gestation tracheal occlusion in the fetal lamb causes rapid lung growth with type II cell preservation. *J Surg Res*, 92(1), 64-70. DOI: 10.1006/jsre.2000.5858
- Luks, F. I., Roggin, K. K., Wild, Y. K., Piasecki, G. J., Rubin, L. P., Lesieur B. A. M. & De Paepe, M.E. (2001). Effect of lung fluid composition on type II cellular activity after tracheal occlusion in the fetal lamb. *J Pediatr Surg*, 36(1), 196-201. DOI: 10.1053/jpsu.2001.20051
- Madhavan, A., Venkatesan, G., Kumar, A., Arya, S. & Pandey, A. B. (2020). Comparative sequence and structural analysis of the ORF095 gene, a vaccinia virus A4L homolog of capripoxvirus in sheep and goats. *Arch Virol*, 165(6), 1419-1431. DOI:10.1007/s00705-020-04623-5
- Milli, U. H., Alcigir, G. & Altinsaat, M. S. (1991). Light and electron microscopic studies on pulmonary lesions in sheeppox. *Ank Univ Vet Fak Derg*, 38, 138-163.
- Mims, C. A. (1981). Vertical transmission of viruses. *Microbiol Rev*, 45(2), 267-286. DOI: 10.1128/mr.45.2.267-286.1981
- Mondal, B., Hosamani, M., Dutta, T. K., Senthilkumar, V. S., Rathore, R. & Singh, R. K. (2004). An outbreak of sheep pox on a sheep breeding farm in Jammu, India. *Rev Sci Tech*, 23(3), 943-949. DOI: 10.20506/rst.23.3.1536
- Rouby, S. & Aboulsoud, E. (2016). Evidence of intrauterine transmission of lumpy skin disease virus. *Vet J*, 209, 193-195. DOI: 10.1016/j.tvjl.2015.11.010
- Sambrook, J. & Russell, D.W. (2001) Molecular cloning: a laboratory manual. Cold Spring Harbor Laboratory, New York
- Sumana, K., Revanaiah, Y., Apsana, R., Roy, P. & Reddy, G. M. (2020). Molecular characterization of sheeppox virus from outbreaks in Karnataka, India. *Vet World*, 13(2), 386. DOI: 10.14202/vet-world.2020.386-391.
- Tamura, K., Peterson, D., Peterson, N., Stecher, G., Nei, M., Kumar, S. (2011) MEGA5: molecular evolutionary genetics analysis using maximum likelihood, evolutionary distance, and maximum parsimony methods. *Mol Biol Evol*, 28:2731-2739. <https://doi.org/10.1093/molbev/msr121>
- Yager, J. A. & Scott, D. W. (1985). The skin and appendages. In: Pathology of Domestic Animals, 3rd Ed, Jubb, K.V.F., Kennedy, P.C., Palmer, N. Eds., pp. 461-471, Academic Press, California.
- Zangana, I. K. & Abdullah, M. A. (2013). Epidemiological, clinical, and histopathological studies of lamb and kid pox in Duhok, Iraq. *Bulg J Vet Med*, 16(2), 133-138.
- Zewdie, G., Derese, G., Getachew, B., Belay, H. & Akalu, M. (2021). Review of sheep and goat pox disease: current updates on epidemiology, diagnosis, prevention and control measures in Ethiopia. *Anim Dis*, 1, 28-38. <https://doi.org/10.1186/s44149-021-00028-2>