

## Flexible Ureterorenoscopy versus Semirigid Ureteroscopy for the Treatment of Proximal Ureteral Stones: A Retrospective Comparative Analysis of 124 Patients

Mert Ali Karadag,<sup>1\*</sup> Aslan Demir,<sup>1</sup> Murat Bagcioglu,<sup>1</sup> Kursat Cecen,<sup>1</sup> Ramazan Kocaaslan,<sup>1</sup> Fatih Altunrende<sup>2</sup>

**Purpose:** To investigate and compare the stone clearance and complication rates of flexible ureteroscopy (URS) with semirigid URS in patients having proximal ureteral stones.

**Materials and Methods:** The data of 124 patients with proximal ureteral stones who underwent semirigid or flexible ureterorenoscopic lithotripsy between March 2008 and December 2012 were retrospectively investigated. The patients were divided into 2 groups according to the operation types. Group 1 included 63 patients who were treated with semirigid URS and group 2 was consisted from 61 patients who underwent flexible URS. Each group was compared in terms of stone diameter, successful access to the stone, operation time, reoperation rates, stone free status at postoperative 1st and 3rd month and complications.

**Results:** Successful access was achieved in 48/63 (76%) of the cases in group 1 and 57/61 (93%) of the patients in group 2 ( $P < .05$ ). Initial stone free status was 63.4% (40/63) and 86.8% (53/61) in groups 1 and 2, respectively ( $P < .05$ ). Third month radiologic investigations revealed a stone free rate of 77.7% (49/57) in group 1 and 93.4% (57/61) in group 2 ( $P < .05$ ). Reoperation was required in 20.6% (13/63) of cases in group 1 and this value was only 6% (4/61) in group 2 ( $P < .05$ ). There was not any statistically significant difference between 2 groups in terms of complication rates ( $P > .05$ ).

**Conclusion:** Flexible URS is a favorable option for patients having proximal ureteral stones with higher stone free rate; on the other hand semirigid URS seems a less successful alternative for treatment of proximal ureteral stones.

**Keywords:** ureteral calculi; surgery; ureteroscopes; ureteroscopy; lithotripsy; retrospective studies; treatment outcome; complications.

### INTRODUCTION

Proximal ureteral stones can be managed by various techniques including extracorporeal shock wave lithotripsy (SWL), ureterorenoscopy (URS) with semirigid or flexible instruments, laparoscopic approaches, antegrade ureterolithotripsy and open surgery. The decisions about the choice of therapy depends on the stone factors like localization, size, density and radiolucency, anatomical factors, obstruction, technical capacity of the department, patient's preference and surgeon's skills.<sup>(1,2)</sup> SWL and URS have been accepted as the initial treatment alternatives for proximal ureteral stones having low probability of spontaneous passage. SWL has been considered as the first line treatment alternative for patients having proximal ureteral stones < 10 mm due to noninvasiveness and lower complication rates.<sup>(3)</sup> The major disadvantages of SWL are long duration of treatment and requirement for auxiliary procedures. With the miniaturization and advancements in the designs of ureterorenoscopes, stone disintegration systems and endourologic techniques, most of the ureteral stones can be managed by URS now-

adays. Usage of holmium:YAG laser during URS makes the stone clearance better in a single session even for the proximal ureteral stones > 10 mm.<sup>(4)</sup>

Many studies to date have investigated the superiority and outcomes (in terms of complication rates and stone free status) of SWL, retrograde intrarenal surgery and laparoscopy over each other for the treatment of proximal ureteral stones.<sup>(5,6)</sup> To the best of our knowledge, there has been no published article investigating and comparing the outcomes of flexible URS (F-URS) against semirigid URS for treatment of proximal ureteral stones. In the present study, we investigated and compared the stone clearance and complication rates of F-URS against semirigid URS in patients having proximal ureteral stones.

### MATERIALS AND METHODS

The medical files of 228 patients with solitary proximal ureteral stones who underwent semirigid URS or F-URS in Kars State Hospital, Kafkas University, Faculty of Medicine and Acibadem Kayseri Hospital between

<sup>1</sup> Department of Urology, Kafkas University, Faculty of Medicine, Kars, Turkey.

<sup>2</sup> Department of Urology, Istanbul Bilim University, Faculty of Medicine, Istanbul, Turkey.

\*Correspondence: Kafkas Üniversitesi Tıp Fakültesi Hastanesi, Üroloji A.B.D, Kars, Türkiye. Tel: +90 532 5584324. E-mail: karadagmert@yahoo.com.

Received March 2014 & Accepted October 2014.

March 2008 and December 2012 were reviewed and database of the study was formed. Semirigid URS was performed in 108 patients and 120 underwent F-URS. According to the data searched, a total of 124 patients with solitary proximal stones who underwent semirigid URS or F-URS with holmium:YAG laser were enrolled in this study. Inclusion criteria of the study was patients who were operated for solitary proximal ureteral stones with semirigid or F-URS and who had postoperative 1st and 3rd month radiological investigations for assessment of stone free status in the medical records. Patients with ureteral calculi who were previously operated or treated with SWL, cases with ureteropelvic junction obstruction, solitary kidneys or multiple stones and the patients under 18 years old were excluded from the study.

Semirigid URS group included the patients who were operated in Kars Sate Hospital and Kafkas University, Faculty of Medicine. F-URS group consisted of the patients who were operated in Acibadem Kayseri Hospital. Review of the complete medical records of the patients for our study was approved by local ethics committee of Kafkas University, Faculty of Medicine and performed in accordance with the Helsinki Declaration of the World Medical Association.

Proximal ureteral stones were defined as the stones located between the superior margin of the sacroiliac joint and the ureteropelvic junction. All of the patients were preoperatively evaluated with a detailed history, physical examination, laboratory tests including renal function tests, urine analysis and urine culture. The imaging investigations were plain X-ray of the kidneys, ureter and bladder (KUB), urinary ultrasonography and non contrast computed tomography (CT) scan of the abdomen in patients with radioluscent stones.

Stone status was assessed intraoperatively and with postoperative 1st and 3rd month plain X-ray of the KUB, urinary ultrasonography and non contrast CT scan of the abdomen in patients having radioluscent stones. Success was accepted as patients with no stones or clinically insignificant residual fragments (< 4 mm) observed at initial postoperative evaluation and 1st/3rd month radiologic investigations. Stone size was measured by using the longest axis of the stone viewed on plain film or sagittal section of CT scan.

### **Surgical Procedures**

All of the patients were operated under general anesthesia at the lithotomy position. Cephazolin sodium 1 gr intravenous was administered for preoperative antibiotic prophylaxis. Semirigid URS was performed by using a 6.0/7.5 French (F) ureteroscope (Richard Wolf, Knittlingen, Germany). First, we introduced a safety guide wire (Microvasive, Boston Scientific Corp, Natick, MA, USA) to the ureter with stone, then the semirigid ureterorenoscope was inserted into the ureter over guide wire under direct vision. After reaching the stone, disintegration was completed by using 20 W holmium:YAG laser (Lumenis, Santa Clara, CA, USA). A 200- $\mu$ m laser fiber with an energy output of 0.8-1.5 joule at 8-12 hertz was used; but the joule and hertz of energy could be changed during the operation according to the stone hardness and efficacy of lithotripsy. The main goal was to disintegrate the stones until the fragments were smaller than 4 mm under direct vision or completely extraction of the stone fragments

with basket (Zero Tip™, Boston Scientific Corp, Natick, MA, USA).

F-URS was performed using a 7.5 F flexible ureterorenoscope (Karl Storz, Tuttlingen, Germany). After the insertion of a 9/11 F access sheath (Cook Urological, Spencer, Indiana, USA) over a sensor guide wire (Microvasive, Boston Scientific Corp, Natick, MA, USA) under C arm fluoroscopy, we inserted the F-URS into the ureter and completed the stone disintegration and extraction like in the semirigid URS procedure.

For both treatment groups, we inserted 26 cm 4.8 F double J ureteral catheters over the guide wires at the end of the procedures. It is a routine application in our department and urology department of Acibadem Kayseri Hospital after the treatment of proximal ureteral stones.

### **Statistical Analysis**

Results are presented as the mean  $\pm$  Standard deviation (SD). The data were analyzed by Statistical Package for the Social Science (SPSS Inc, Chicago, Illinois, USA) version 16.0. Categorical variables were analyzed using chi-square test and statistical analyses of the means of continuous variables were performed with the Student's *t*-test. A *P* value of < .05 was considered statistically significant.

Each group treated with semirigid URS and F-URS for proximal ureteral stones were compared in terms of stone diameter, successful access to the stone, operation time, reoperation rates, stone free status at 1st and 3rd month and complications like fever, bleeding and perforation. Reoperation was defined as requirement of same modality in patients with residual stones or stones > 4 mm in radiologic evaluation. Bleeding was accepted as hemorrhage that disrupted the endoscopic vision of the surgeon and ureteral injury was defined as mucosal trauma that was observed during URS applications. Bleeding and ureteral injury were decided by the urologists who performed the operations.

### **RESULTS**

Patients' characteristics and demographics of 2 groups were summarized in **Table**. There was not any statistically significant difference between two groups in terms of age, gender, stone size and opacity (*P* > .05). As expected, the mean operation time of group 1 was significantly shorter than group 2. With regards to success rate of reaching to the stone, we could make a successful access and reach to the stone in 48/63 (76%) of the cases in group 1 and 57/61 (93%) of the patients in group 2. This value was statistically significant (*P* = .008) and showed the superiority of F-URS in reaching to the proximal ureteral stones. In patients of group 1 with unsuccessful access to the stones (*n* = 9) (5 tortuosity, 2 narrow caliber of the ureter and 2 serious stenosis) and stone migration into the kidneys (*n* = 6), we inserted 26 cm 4.8 F double J catheters and operations were terminated. They were referred to another center for SWL or F-URS applications and excluded from the study in terms of stone free achievement. In patients of group 2 with unsuccessful access to the stone (*n* = 4), same aforementioned modality was preferred. The reason of unsuccessful access in these patients was narrow caliber of the ureters (summarized in the flow chart).

Table. Demographic and clinical characteristics of study groups.

Variables	Semirigid URS	Flexible URS	P Value
No. of patients	63	61	
Mean age (year)*	38.2 ± 9.85	36.2 ± 7.38	.214
Stone diameter (mm)*	11.6 ± 2.20	11.01 ± 2.24	.107
Sex**			.697
Female	29/63	25/61	----
Male	34/63	36/61	----
Laterality**			.474
Right	34/63	29/61	
Left	29/63	32/61	
Radioluscent**	7/63	6/61	.817
Operation time (min)*	64.71 ± 16.11	84.06 ± 16.7	.001

Abbreviation: URS, ureteroscopy.

\*Student *t*-test ( $P > .05$ )

\*\*Chi-square test ( $P > .05$ )

Initial stone free status which was achieved after disintegration of the stones < 4 mm or complete extraction of the fragments decided by the surgeon at the end of the procedure was 63.4% (40/63) and 86.8% (53/61) in groups 1 and 2, respectively. This result was statistically significant ( $P = .003$ ). This rate increased to 71.4% (45/63) in group 1 and 90.1% (55/61) in group 2 ( $P = .008$ ) at 1st month radiologic controls. Third month radiologic investigations revealed a stone free rate of 77.7% (49/63) in group 1 and 93.4% (57/61) in group 2 ( $P = .013$ ). All these results showed us the superiority of F-URS in terms of achieving a stone free status.

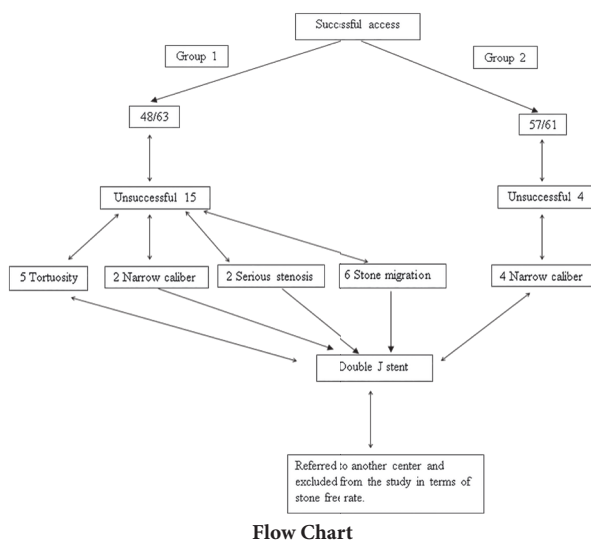
Reoperation rates of 2 groups were compared in our study. We required reoperation in cases who had rest stones or stones > 4 mm in radiologic evaluations. Reoperation was required in 13/63 (20.6%) of cases in group 1 this value was only 6% (4/61) in group 2. Reoperation rate of group 2 was statistically lower than group 1 ( $P = .023$ ). Complications were classified according to the modified

Clavien Grading system.<sup>(7)</sup> No major intraoperative complications (grade 4 or 5) like avulsion or septicaemia were observed. Ureteral perforation (grade 3B) below the ureteropelvic junction occurred in 1 patient from F-URS group and managed conservatively with insertion of a 26 cm 4.8 F double J ureteral catheter. The complication rates of 2 groups in terms of fever, bleeding and ureteral injury were compared. Postoperative fever (grade 1) was observed in 7 (11.1%) patients from group 1 and 8 (13.1%) patients from group 2 ( $P = .732$ ). Bleeding (grade 1) was noted in 13 (20.6%) and 5 (9.8%) patients from group 1 and 2, respectively ( $P = .095$ ). Ureteral injury (grade 1) occurred in 4 (7.9%) and 2 (3.2%) cases from groups 1 and 2, respectively ( $P = .261$ ). There was not any statistically significant difference between 2 groups in terms of complication rates.

## DISCUSSION

The success rate of SWL in proximal ureteral stones larger than 10 mm varies between 57-96% in the literature.<sup>(8,9)</sup> Patient's and urologist's preference of SWL therapy mainly depend on the advantage of less invasiveness with lower complication rates.<sup>(3)</sup> In our department, we also have a SWL machine and therapy choice of proximal ureteral stones are decided after explanation of the options and discussion with the patients. All of the patients who were included in our study preferred ureterorenoscopic procedures as therapeutic modality.

Recent developments in the market about miniaturization of semirigid and F-URS and holmium:YAG laser in URS applications attracted the attentions of the urologists and markedly improved the success rates of treating proximal ureteral and renal stones. Atis and colleagues investigated the efficacy of semirigid URS against F-URS in treatment of renal pelvis stones.<sup>(10)</sup> The study included 47 patients with isolated renal pelvis stones. Successful access with semirigid URS was achieved in 25 of 47 patients and the stones were fragmented using holmium:YAG laser. F-URS was performed in remaining 22 patients.



The authors revealed no significant differences among 2 groups in terms of stone free rates, complication rates and hospitalization. An approximately success rate of 50% improved to 90% in the treatment of proximal ureteral stones after development of small caliber URS and holmium:YAG laser.<sup>(11-14)</sup> The major disadvantage of holmium:YAG laser seems to be the cost; but we also prefer to use holmium:YAG laser for treating patients with proximal ureteral stones as energy source in our department. In a recent study from India, 90 patients having upper ureteral stones < 2 cm were treated with shockwave lithotripsy and semirigid URS and outcomes were compared.<sup>(15)</sup> Ureteroscopy and stone disintegration were performed by using an 6/7.5 F semirigid URS with holmium:YAG laser. The average stone size of URS group was 12.5 mm and the overall 3rd month stone free rate was 86.6%. In our study, the mean stone size of patients treated with semirigid URS was 11.6 mm and 3rd month success rate of this group was 77.7%. The average stone diameter of 2 studies were similar; but the other group's success rate was higher. This may attribute to the experience of the other group in treating proximal ureteral stones and technical armamentarium of the clinics. In our opinion, if we had F-URS, stone-cone® or N-Trap® basket in the clinics of Kars State Hospital and Kafkas University Faculty of Medicine, the success rate of semirigid URS group would be higher.

After introduction of flexible systems into urology, the stone free rate was significantly increased for the treatment of the patients having proximal ureteral stones.<sup>(16,17)</sup> In a recent study, Liu and colleagues investigated the outcomes of 187 patients with proximal ureteral stones who were treated with ureteroscopic lithotripsy using holmium:YAG laser.<sup>(18)</sup> They reported that with the aid of F-URS and N-Trap® basket, the success rate improved to 88.9% and achievement of a stone free state after semirigid URS procedures would be possible. Endourological Society Ureteroscopy Global Study Group recently published their article dealing with differences in ureteroscopic stone treatment and outcomes in patients with distal, mid, proximal, or multiple ureteral locations.<sup>(19)</sup> Of 9681 patients, 2656 received ureteroscopy treatment for stones located in the proximal ureter. Semirigid URS with laser or pneumatic lithotripsy were used in the majority of cases. They revealed a stone free rate of 84.5% for proximal ureteral stones. Similar to our study, failure and retreatment rates were significantly higher for semirigid URS, when compared to F-URS. A new study from Korea investigated the effectiveness of flexible ureteroscopic stone removal for treating ureteral and ipsilateral renal stones.<sup>(20)</sup> The study included 74 ureteral stones of which 46 located in the upper ureter, 10 in the middle ureter and 18 in the lower ureter. They achieved a stone free rate of 100% for ureteral stones; but the mean size of the ureteral stones was not reported in the study. Instead of average stone size term, they used cumulative stone burden which also included the sizes of ipsilateral renal stones. In our study, the initial success rate of F-URS group was 86.8% and this rate increased to 93.4% at the end of 3rd month. The overall success rate of F-URS group was statistically higher than semirigid URS group. In our opinion, the treatment of patients of semirigid URS group having unsuccessful access to the stone or stone migration into the kidneys could be completed by using

F-URS. Unfortunately, the urology departments of Kars State Hospital and Kafkas University, Faculty of Medicine had not had F-URS until 2012. Nowadays, we have capability of using F-URS in patients with proximal ureteral or renal stones.

Most of the urologists prefer to dilate the ureter "optically" by using a semirigid URS prior to F-URS. Besides this, we did not perform optical dilatation before flexible procedures in our study and they were performed after insertion of 9/11 F access sheaths over the guide wires. Instead of switching to F-URS in the operation, we rather prefer to start the procedure with flexible instrument and disintegrate the stone with the same modality.

Stone access rates in our study showed us that F-URS was statistically superior against semirigid URS (93% vs. 76%). This difference may be attributable to the use of access sheath prior to the flexible procedure. The application of ureteral access sheath carries many advantages like outflow of irrigation fluid which facilitates clear vision for the surgeon, avoiding of high renal pressure which could decrease septicemia risk and obtain expulsion of stone fragments, preventing mucosal trauma during the procedure and prolonging the active life of F-URS.<sup>(18)</sup> Except of 4 cases with narrow caliber of ureters, we introduced access sheaths to all patients prior to the flexible procedures and we did not face with any difficulties in application of the access sheaths over guide wires. In our opinion, factors that complicate access to stones like tortuosity of the ureter, angulations and serious edema at the stone site could be defeated by using access sheath and F-URS.

Retreatment rate of semirigid URS varies between 4% and 23% in the literature.<sup>(21-23)</sup> Our study revealed a reoperation rate of 20.6% for semirigid URS group. This result was similar with the rate of Basiri's and Nikoobakht's studies.<sup>(22,23)</sup> Basiri and colleagues found reoperation rate in their study as 22%; on the other hand Salem and colleagues<sup>(21)</sup> revealed a reoperation rate of 4%. In our opinion, the heterogeneity in reoperation rates depends on the mean stone sizes of the studies. The mean stone size of patients who were treated with semirigid URS in Salem's study was approximately 7 mm; but the average stone size of the patients in Basiri's study was  $1.8 \pm 0.2$  cm.

Lee and colleagues reported a reoperation rate of 42% with F-URS for the patients having large upper third ureteral stones.<sup>(17)</sup> In our study, reoperation rate of F-URS group was only 6%. This disparity could be explained again with the difference in average stone diameters of the studies. The mean stone size in Lee's study was  $1.8 \pm 0.3$  cm, on the other hand our study's average stone size of patients treated with F-URS was 11.01 mm. It seems that the requirement for auxiliary treatments increases with the increase in the ureteral stone diameter.

The most important and serious complications of ureteroscopic lithotripsy are ureteral avulsion and perforation.

<sup>(18)</sup> In the literature, the incidence of ureteral perforation is between 0-1%.<sup>(18,20,24)</sup> Only in 1 patient from F-URS group, a 2 cm ureteral perforation occurred at the edematous site below the ureteropelvic junction during tracing a stone which migrated into the kidney. The operation was terminated after insertion of a 26 cm 4.8 F double J ureteral catheter and left for 6 weeks. After 6 weeks he was reoperated for migrating stone. The comparison between complication rates in terms of fever, bleeding and ure-

teral injury revealed no significant difference between 2 groups. These minor complications were treated conservatively and disappeared after 2-3 days. Bleeding and ureteral injury were more common in patients treated with semirigid URS. We did not terminate any operations due to bleeding or ureteral injury in any cases. We think that it was due to surgeon's forced forward pushing of semirigid ureteroscope in some cases having angulations, tortuosity of the ureter and serious edema at the stone site. In our opinion, these difficulties in reaching the proximal ureteral stones could be defeated by using F-URS with the advantages of deflexion and rotation.

There are several limitations of our study. First of all, our study had a retrospective nature and based on a small sample size. In the literature, the "stone free status" and clinically insignificant residual fragments (CIRF) terms have not been defined and standardized yet. In our study, we preferred to use CIRF term for stones < 4 mm. There are 3 institutions involving in this study; but procedures were performed by only 3 surgeons. KC performed semirigid ureteroscopies, whereas MAK and MS performed flexible procedures. It should be kept in mind that surgical skills may vary from surgeon to surgeon and for this reason making standardization about studies dealing with surgical interventions is very difficult.

## CONCLUSION

Ureteroscopic management of proximal ureteral stones can be achieved by using semirigid or F-URS. F-URS is a favorable option for patients having proximal ureteral stones with higher stone free rate; on the other hand semirigid URS seems a less successful alternative for treatment of proximal ureteral stones. The semirigid URS should be preferred for management of proximal ureteral stones, if F-URS is involved in department's armamentarium due to the fact that with the aid of F-URS, success rate of the semirigid procedures will be higher.

## CONFLICT OF INTEREST

None declared.

## REFERENCES

1. Kijvikai K, Haleblan GE, Preminger GM, de la Rosette J. Shock wave lithotripsy or ureteroscopy for the management of proximal ureteral calculi: an old discussion revisited. *J Urol.* 2007;178:1157-63.
2. Maltaga BR. Contemporary surgical management of upper urinary tract calculi. *J Urol.* 2009;181:2418-34.
3. Segura JW, Preminger GM, Assimos DG, et al. Ureteral Stones Clinical Guidelines Panel summary report on the management of ureteral calculi. *The American Urological Association. J Urol.* 1997;158:1915-21.
4. Wu CF, Shee JJ, Lin WY, Lin CL, Chen CS. Comparison between extracorporeal shock wave lithotripsy and semirigid ureterorenoscopy with holmium:YAG laser lithotripsy for treating large proximal ureteral stones. *J Urol.* 2004;172:1899-902.
5. Ozturk U, Sener NC, Goktug G, Gucuk A, Nalbant I, Imamoglu A. The comparison of laparoscopy, shock wave lithotripsy and retrograde intrarenal surgery for large proximal ureteral stones. *Can Urol Assoc J.* 2013;7:e673-76.
6. Lam JS, Greene TD, Gupta M. Treatment of proximal ureteral calculi: holmium:YAG laser ureterolithotripsy versus extracorporeal shock wave lithotripsy. *J Urol.* 2002;167:1972-6.
7. Dindo D, Demartines N, Clavien PA. Classification of surgical complications: a new proposal with evaluation in a cohort of 6336 patients and results of a survey. *Ann Surg.* 2004;240:205-13.
8. Liong ML, Clayman RV, Gittes RF, Lingeman JE, Huffman JL, Lyon ES. Treatment options for proximal ureteral urolithiasis: review and recommendations. *J Urol.* 1989;141:504-9.
9. Demirbas M, Samli M, Karalar M, Kose AC. Extracorporeal shockwave lithotripsy for ureteral Stones: twelve years of experience with 2836 patients at a single center. *Urol J.* 2012;9:557-61.
10. Atis G, Gurbuz C, Arikan O, Canat L, Kilic M, Caskurlu T. Ureteroscopic management with laser lithotripsy of renal pelvic Stones. *J Endourol.* 2012;26:983-7.
11. Slam J, Tricia D: Greene and Mantu Gupta. Treatment of proximal ureteral calculi: Holmium YAG laser ureterolithotripsy versus extracorporeal shock wave lithotripsy. *J Urol.* 2002;167:1972-6.
12. Ching-Fang W, Shee JJ, Lin WY, Lin CL, Chen CS. YAG laser lithotripsy for treating large proximal ureteral Stones. *J Urol.* 2004;172:1899-902.
13. Razzaghi MR, Razi A, Mazloomfard MM, Taklimi AG, Valipour R, Razzaghi Z. Safety and efficacy of pneumatic lithotripters versus holmium laser in management of ureteral calculi: a randomized clinical trial. *Urol J.* 2013;10:762-6.
14. Tawfik ER, Bagley DH. Management of upper urinary tract calculi with ureteroscopic techniques. *Urology.* 1999;53:25-31.
15. Kumar A, Nanda B, Kumar N, Kumar R, Vasudeva P, Mohanty NK. A Prospective Randomized Comparison Between Shockwave Lithotripsy and Semirigid Ureteroscopy for Upper Ureteral Stones < 2 cm: A Single Center Experience. *J Endourol.* 2013; Sep 12. [Epub ahead of print]
16. Best SL, Nakada SY. Flexible ureteroscopy is effective for proximal ureteral stones in both obese and non obese patients: a two year, single-surgeon experience. *Urology.* 2011;77:36-9.
17. Lee YH, Tsai JY, Jiaan BP, Wu T, Yu CC. Prospective randomized trial comparing shockwave lithotripsy and ureteroscopic lithotripsy for the management of large upper third ureteral stones. *Urology.* 2006;67:480-4.
18. Liu DY, He H, Wang J, et al. Ureteroscopic lithotripsy using holmium laser for 187 patients with proximal ureteral stones. *Chin Med J.* 2012;125:1542-6.
19. Perez Castro E, Osthier PJ, Jinga V, et al. Differences in ureteroscopic stone treatment and outcomes for distal, mid, proximal, or multiple

- ureteral locations: The Clinical Research Office of the Endourological Society Ureteroscopy Global Study. *Eur Urol.* 2014;66:102-9.
20. Lee SH, Kim TH, Myung SC, et al. Effectiveness of Flexible Ureteroscopic Stone Removal for Treating Ureteral and Ipsilateral Renal Stones: A Single-Center Experience. *Korean J Urol.* 2013;54:377-82.
  21. Salem HK. A prospective randomized study comparing shockwave lithotripsy and semirigid ureteroscopy for the management of proximal ureteral calculi. *Urology.* 2009;74:1216-21.
  22. Basiri A, Simforoosh N, Ziaee A, Shayaninasab H, Moghaddam SM, Zare S. Retrograde, antegrade, and laparoscopic approaches for the management of large, proximal ureteral stones: a randomized clinical trial. *J Endourol.* 2008;22:2677-80.
  23. Nikoobakht MR, Emamzadeh A, Abedi AR, Moradi K, Mehraei A. Transureteral lithotripsy versus extracorporeal shock wave lithotripsy in management of upper ureteral calculi: a comparative study. *Urol J.* 2007;4:207-11.
  24. Taie K, Jasemi M, Khazaeli D, Fatholahi A. Prevalence and management of complications of ureteroscopy: a seven-year experience with introduction of a new maneuver to prevent ureteral avulsion. *Urol J.* 2012;9:356-60.